



HAL
open science

Endoscopic hybrid resection and under-water snare resection of symptomatic duodenal duplication cysts in children

M. Milashka-Brihay, M. Figueiredo, M. Pantaleón Sánchez, C. Yzet, S. Collardeau-Frachon, J. Rivory, M. Pioche

► To cite this version:

M. Milashka-Brihay, M. Figueiredo, M. Pantaleón Sánchez, C. Yzet, S. Collardeau-Frachon, et al.. Endoscopic hybrid resection and under-water snare resection of symptomatic duodenal duplication cysts in children. *Endoscopy*, 2022, 55 (S01), pp.E108-E109. 10.1055/a-1929-8901 . inserm-03987320

HAL Id: inserm-03987320

<https://www.hal.inserm.fr/inserm-03987320>

Submitted on 14 Feb 2023

HAL is a multi-disciplinary open access archive for the deposit and dissemination of scientific research documents, whether they are published or not. The documents may come from teaching and research institutions in France or abroad, or from public or private research centers.

L'archive ouverte pluridisciplinaire **HAL**, est destinée au dépôt et à la diffusion de documents scientifiques de niveau recherche, publiés ou non, émanant des établissements d'enseignement et de recherche français ou étrangers, des laboratoires publics ou privés.

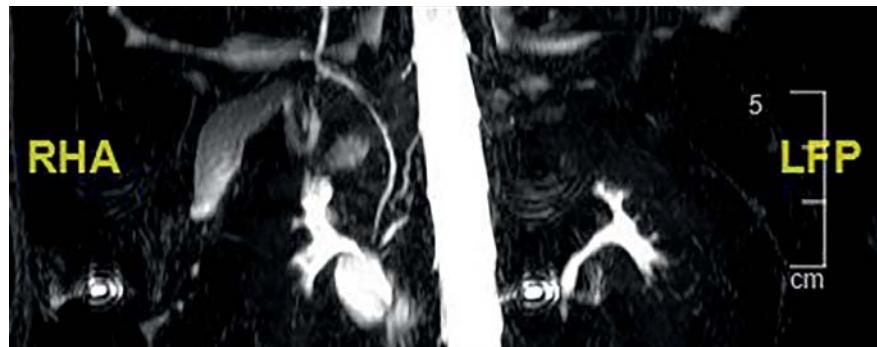
Endoscopic hybrid resection and under-water snare resection of symptomatic duodenal duplication cysts in children

OPEN
ACCESS

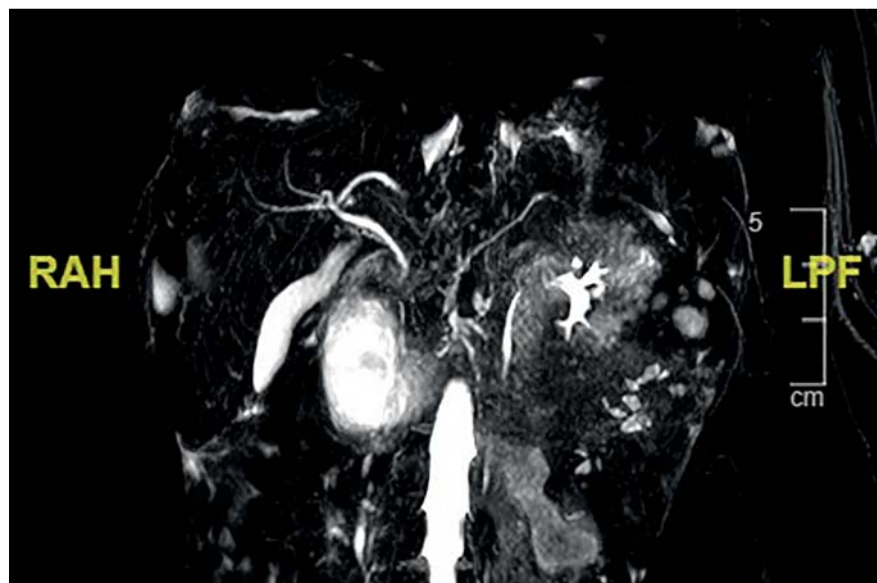
Duodenal duplication cysts are rare congenital malformations of the gastrointestinal tract, manifested in early childhood [1, 2]. They are benign lesions, although a few cases have been reported including carcinoid tumors, squamous cell carcinomas, and adenocarcinomas [3]. Endoscopic treatments include fenestration, marsupialization, snare resection, and aspiration [4, 5].

We report two cases of endoscopic resection of duodenal duplications in children. The first case is of a 7-year-old boy presenting with abdominal pain and elevated liver enzymes. Magnetic resonance imaging (MRI) and endoscopic ultrasound (EUS) showed a 25-mm duodenal duplication cyst, independent from the common bile duct and pancreatic duct but encompassing the major papilla (► Fig. 1). We performed endoscopic under-water snare resection of the cyst using a linear EUS scope. The posterior wall of the resected cyst contained the major papilla and a prophylactic pancreatic stent was placed without complication.

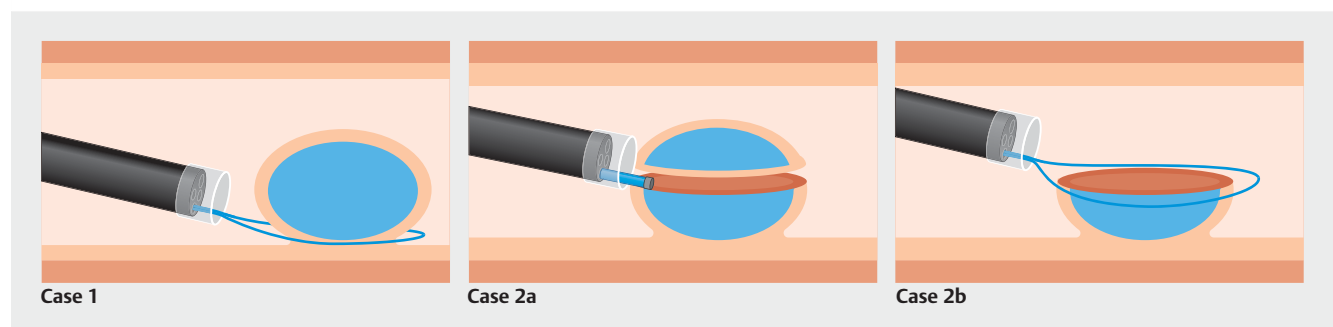
The second case was a 2-year-old girl admitted for abdominal pain and vomiting (► Fig. 2, ► Fig. 3; ► Video 1). CT showed jejunal intussusception, which was reduced laparoscopically. MRI and EUS revealed a 40-mm duodenal duplication cyst in the second duodenum, with



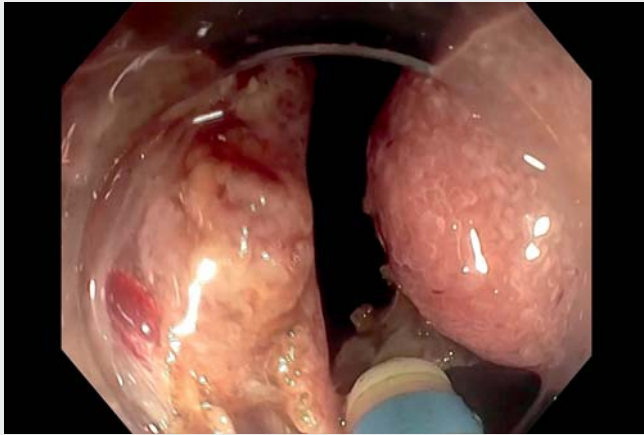
► Fig. 1 Abdominal magnetic resonance imaging (MRI), case 1.



► Fig. 2 Abdominal MRI, case 2.



► Fig. 3 Diagram of endoscopic snare resection (Case 1) and endoscopic hybrid resection (Case 2a: circumferential incision + Case 2b: snare resection).



Video 1 Endoscopic under-water snare resection and endoscopic hybrid resection of duodenal duplication cysts.

the major papilla inside. We performed endoscopic hybrid resection, combining circumferential incision of the proximal portion of the cyst (Dual Knife; Olympus, Tokyo, Japan), followed by snare resection using the Olympus PCF 190 TI colonoscope. The remaining duplication mucosa was fixed to duodenal mucosa by clips. In both cases histology confirmed duodenal duplication covered by intestinal mucosa without dysplasia.




This video shows two different types of resections depending on the presentation of duplication and its links to the duodenal wall. In the first case complete resection was feasible with a snare, but in the second, the duodenal wall appeared incomplete and therefore only complete duplication could be resected using the hybrid technique. These two types of resections avoid the morbidity associated with surgical resection and the necessity of endoscopic follow-up recommended to prevent the risk of malignant transformation in cases of simple fenestration.

Endoscopy_UCTN_Code_TTT_1AO_2AG

Competing interests

The authors declare that they have no conflict of interest.

The authors

Mariana Milashka-Brihay  **Mariana Figueiredo, Miguel Pantaleón Sánchez**  **Clara Yzet, Sophie Collardeau-Frachon**  **Jérôme Rivory, Mathieu Pioche**

Department of Endoscopy and Hepato-Gastroenterology, Pavilion L, Edouard Herriot Hospital, Lyon, France

Corresponding author

Mariana Milashka-Brihay, MD

Endoscopy Unit – Digestive Disease Department, Pavilion L – Edouard Herriot Hospital, 69437 Lyon Cédex, France
mariana.milashka@chu-lyon.fr

References

- [1] Dipasquale V, Barraco P, Faraci S et al. Duodenal duplication cysts in children: clinical features and current treatment choices. *Biomed Hub* 2020; 5: 508489
- [2] Bulotta AL, Stern MV, Moneghini D et al. Endoscopic treatment of periampullary duodenal duplication cysts in children: four case reports and review of the literature. *World J Gastrointest Endosc* 2021; 13: 529–542

- [3] Blank G, Köigsrainer A, Sipos B et al. Adenocarcinoma arising in a cystic duplication of the small bowel: case report and review of literature. *World J Surg Oncol* 2012; 10: 55
- [4] Vandenbroucke F, Dagenais M, Létourneau R et al. Endoscopic treatment of a duodenal duplication cyst. *Endoscopy* 2005; 37: 601
- [5] Gjeorgjievski M, Manickam P, Ghaith G et al. Safety and efficacy of endoscopic therapy for nonmalignant duodenal duplication cysts: case report and comprehensive review of 28 cases reported in the literature. *Medicine* 2016; 95: 22

Bibliography

Endoscopy 2023; 55: E108–E109

DOI 10.1055/a-1929-8901

ISSN 0013-726X

published online 14.10.2022

© 2022. The Author(s).

This is an open access article published by Thieme under the terms of the Creative Commons Attribution-NonDerivative-NonCommercial License, permitting copying and reproduction so long as the original work is given appropriate credit. Contents may not be used for commercial purposes, or adapted, remixed, transformed or built upon. (<https://creativecommons.org/licenses/by-nc-nd/4.0/>)

Georg Thieme Verlag KG, Rüdigerstraße 14, 70469 Stuttgart, Germany



ENDOSCOPY E-VIDEOS

<https://eref.thieme.de/e-videos>



Endoscopy E-Videos is an open access online section, reporting on interesting cases

and new techniques in gastroenterological endoscopy. All papers include a high quality video and all contributions are freely accessible online. Processing charges apply (currently EUR 375), discounts and waivers acc. to HINARI are available.

This section has its own submission website at

<https://mc.manuscriptcentral.com/e-videos>