



HAL
open science

Percutaneous atrial septal defect occlusion through thrombosed inferior vena cava filter

R. R. Rakotonoel, G. Rioufol, W. Uhlrich, F. Derimay

► To cite this version:

R. R. Rakotonoel, G. Rioufol, W. Uhlrich, F. Derimay. Percutaneous atrial septal defect occlusion through thrombosed inferior vena cava filter. *Clinical Case Reports*, 2021, 9 (8), pp.e04350. 10.1002/ccr3.4350 . inserm-03452177

HAL Id: inserm-03452177

<https://www.hal.inserm.fr/inserm-03452177>

Submitted on 26 Nov 2021

HAL is a multi-disciplinary open access archive for the deposit and dissemination of scientific research documents, whether they are published or not. The documents may come from teaching and research institutions in France or abroad, or from public or private research centers.

L'archive ouverte pluridisciplinaire **HAL**, est destinée au dépôt et à la diffusion de documents scientifiques de niveau recherche, publiés ou non, émanant des établissements d'enseignement et de recherche français ou étrangers, des laboratoires publics ou privés.

Percutaneous atrial septal defect occlusion through thrombosed inferior vena cava filter

Radotseheno Rolland Rakotonoel^{1,2} | Gilles Rioufol¹ | William Uhlrich¹ | François Derimay¹

¹Cardiovascular Hospital and Claude Bernard University and Univ Lyon, CarMeN Laboratory, INSERM, INRA, INSA Lyon, Université Claude Bernard Lyon 1, Lyon, France

²Cardiology Unit, Joseph Raseta Befelatanana University Hospital, Antananarivo, Madagascar

Correspondence

François Dérimay, Department of Interventional Cardiology, Louis Pradel Cardiovascular Hospital, Lyon-Monchat, 69394 Lyon Cedex 03, France.
Email: francois.derimay@chu-lyon.fr

Abstract

Thrombosed inferior vena cava (IVC) should not be considered as a limitation to femoral access for cardiac structural procedures. Reopening by angioplasty in the same procedural step is feasible and safe.

KEYWORDS

atrial septal defect, IVC filter, mini TEE

1 | INTRODUCTION

We report percutaneous atrial septal defect (ASD) occlusion through a thrombosed inferior vena cava filter. This demonstrates the technical feasibility and safety of combined vena cava reopening and ASD occlusion in the same step. Thrombosed inferior vena cava (IVC) filter seems not to be a contraindication for femoral access for cardiac structural treatment.

Indications for atrial septal defect (ASD) occlusion can be hemodynamic (right ventricular dilatation by volume overload in absence of pulmonary arterial hypertension) or for paradoxical embolism, to prevent stroke recurrence.¹ When the edges are adequate, percutaneous treatment is the favorite strategy for ostium secundum ASD closure, applied in 80% of ASDs.^{1,2} The anatomy of primum ASD or sinus venosus, however, does not provide enough edge for good stability and can be associated with other cardiac abnormalities. Venous femoral access is then the only option. The present case report describes, for the first time, percutaneous ASD

occlusion through a totally thrombosed IVC filter 5 months after implantation in acute-phase stroke.

2 | CASE REPORT

A 47-year-old man with familial polycystic kidney disease presented with left sylvian ischemic stroke, with complete recovery after thrombolysis. The culprit mechanism was identified as paradoxical embolism after discovery of ASD associated with proximal bilateral phlebitis; no other etiologies were identified. A large thrombophilic check-up identified no real factors. The ASD was of the ostium secundum type, size 19 × 13 mm on transesophageal echocardiography (TEE) (Figure 1A and B). Due to absolute contraindications against all anticoagulation treatments (VKA, DOACs, heparin), given the macroscopic hematuria associated with polycystic kidney disease, a vena cava filter was implanted in the acute phase (ALN, France). Patient was discharged from neurology at day 7.

This is an open access article under the terms of the Creative Commons Attribution License, which permits use, distribution and reproduction in any medium, provided the original work is properly cited.

© 2021 The Authors. *Clinical Case Reports* published by John Wiley & Sons Ltd.

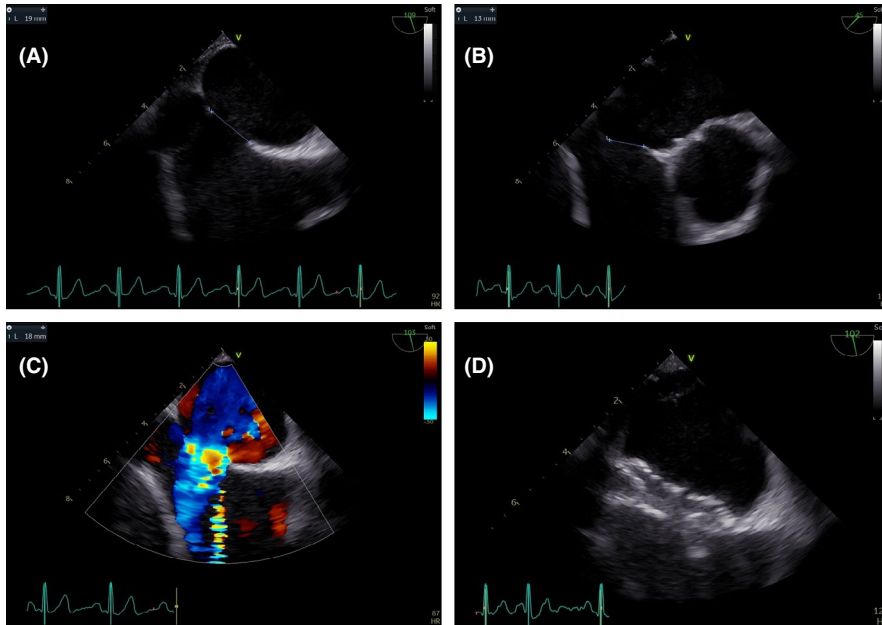


FIGURE 1 Procedural TEE acquisition. A and B, maximum and minimum diameters of ostium secundum ASD. C, left-right unidirectional shunt. D, final control after 24 mm ASD prosthesis implantation (Figulla Occlutech, Germany)

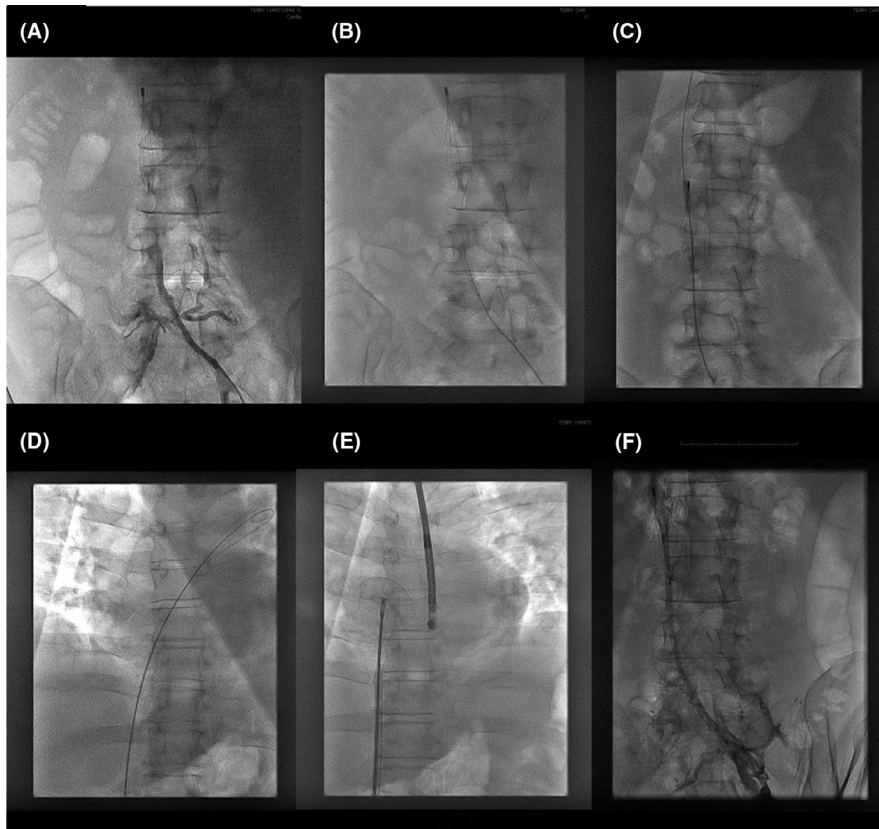


FIGURE 2 inferior vena cava (IVC) reopening and ASD closure. A, total occlusion of IVC. B, occlusion crossing. C, reopening by 5.0 mm balloon angioplasties inside vena cava filter. D: 0.035 mm wire positioning in left superior pulmonary vein through ASD. E, ASD prosthesis deployed. F, final IVC angiographic control without rupture

Five months poststroke, ASD occlusion was decided on as secondary prevention. On TEE, edges were compatible with a percutaneous occlusion strategy, avoiding more complex surgical closure. TTE confirmed the absence of pulmonary arterial hypertension. The right ventricle was slightly dilated but normo-kinetic, without other cardiac abnormalities. Before the procedure, complete IVC occlusion upstream of the vena cava filter was observed on Doppler.

The procedure was performed under local anesthesia, guided by TEE and X-ray. The TEE device was a pediatric mini probe (General Electric). A 12-French desilet was positioned under echo guidance in the left femoral vein (right side thrombosed). Nonfractionated heparin was then injected (100 IU/kg) to obtain ACT>300. Complete IVC occlusion, 15 cm long, was confirmed upstream of the vena cava filter by angiography (Figure 2A). The occlusion was crossed by a 0.35 mm hydrophilic wire (Terumo, Japan) up to the right

atrium (Figure 2B). Reopening was performed by repeated angioplasties with a 5.0x20mm noncompliant balloon at 8 atm (Mustang, Boston Scientific) involving all the occluded segment up to the vena cava filter (Figure 2C). Regarding the risk of thrombus embolization from thrombosed IVC during angioplasty, we performed continuous control of IVC hemodynamics and flow on TEE. The ASD was wired with hydrophilic wire and a 5-French multipurpose launcher (Cordis) to position a nonhydrophilic 0.35 mm exchange wire (Medtronic) in the left superior pulmonary vein (Figure 2D). To limit crossing the vena cava filter, no ASD balloon calibration was performed. Prosthesis sizing was based only on TEE, given the usual underestimation with ultrasound (on average, 15%-20%). A 9-French ASD sheath (Occlutech, Germany) was positioned in the left atrium. The Flex II 24 mm ASD Occluder (Occlutech, Germany) was deployed under TEE control (Figure 2E). Stability testing and edge trapping were perfect, allowing delivery. The final result was perfect, without residual shunt (Figures 1D and 2E). Final angiographic control confirmed IVC reopening without venous rupture (Figure 2F). Aspirin 250 mg was injected before removing the desilet. The complete procedure lasted 30 min. At 1 day, the ASD prosthesis was well positioned, without pericardial effusion on transthoracic ultrasound, and no IVC effusion or filter distortion on abdominal CT. The patient was discharged at 1 day. During clinical follow-up at 3 months, no clinical events were observed. Considering the good tolerance, the absence identified of thrombophilic factors and the definitive contraindication against anticoagulation, after concertation, it was decided to leave the thrombosed IVC in situ.

3 | DISCUSSION

This case shows, for the first time, the feasibility of using IVC access despite a thrombosed inferior vena cava filter for a cardiac procedure (here, ASD occlusion). The procedure, under local anesthesia, was quick and safe. The risks appeared to be very low: thrombus embolization could be feared during angioplasty, despite short anticoagulation by heparin, or else venous rupture, but neither occurred, probably thanks to the small diameter of the angioplasty balloon compared with the diameter of the vein.

Rates of vena cava filter implantation are decreasing, but specific indications remain, especially in stroke, and not only in case of suspected paradoxical embolism. In the literature, half of all patients admitted to hospital with acute stroke develop deep venous thrombosis and more than a quarter develop pulmonary embolism,³ usually without clinical symptoms. Given the risk of cerebral bleeding, an IVC filter is often the best prophylactic solution. As the IVC filter is frequently not removed, the risk of IVC thrombosis is increased and was 20% in one report.⁴ Many IVC reopening techniques

were developed, mainly in case of clinical symptoms,^{5,6} but most are complex, needing specific device implantation,⁷ with risk of complications such as venous rupture or IVC filter distortion, with loss of mechanical effect.⁸

In parallel, indications for percutaneous cardiac treatment after stroke have increased in recent years. New indications such as patent foramen ovale (PFO) occlusion⁹ and new techniques such as left atrial appendage closure (LAAC)¹⁰ have appeared. PFO occlusion and LAAC usually concern patients with history of stroke, in whom anticoagulation treatment is contraindicated in the acute phase, making IVC filter a useful option. PFO occlusion and LAAC systematically need femoral venous access. Thus, in the future, cases where a partially or totally thrombosed femoral vena cava filter needs to be crossed will probably become more frequent. The present case demonstrated the technical feasibility of easy and safe partial IVC reopening in the same step as the cardiac procedure.

4 | CONCLUSION

Partially or completely thrombosed IVC filters should not be considered as contraindicating cardiac procedures with requiring femoral venous access. Simple IVC reopening by angioplasty can be performed in the same step as the cardiac procedure.

ACKNOWLEDGMENTS

Published with written consent of the patient.

CONFLICT OF INTEREST

None declared.

AUTHOR CONTRIBUTIONS

We affirm that all individuals listed as authors agree that they have met the criteria for authorship and agree to the conclusions of the study and that no individual meeting the criteria for authorship has been omitted.

ETHICAL APPROVAL

Informed consent was obtained from the patient regarding the report of her clinical scenario in an anonymous way.

DATA AVAILABILITY STATEMENT

None declared.

REFERENCES

1. Baumgartner H, De Backer J, Babu-Narayan SV, et al. 2020 ESC Guidelines for the management of adult congenital heart disease. *Rev Española Cardiol (English Edition)*. 2021;74(5):436.
2. Du ZD, Hijazi ZM, Kleinman CS, Silverman NH, Larntz K; Investigators Amplatzer. Comparison between transcatheter and

- surgical closure of secundum atrial septal defect in children and adults: results of a multicenter nonrandomized trial. *J Am Coll Cardiol*. 2002;39:1836-1844.
3. Somarouthu B, Yeddula K, Wicky S, Hirsch JA, Kalva SP. Long-term safety and effectiveness of inferior vena cava filters in patients with stroke. *J Neurointerv Surg*. 2011;3:141-146.
 4. Gaspard SF, Gaspard DJ. Retrievable inferior vena cava filters are rarely removed. *Am Surg*. 2009;75:426-428.
 5. Crochet DP, Brunel P, Trogrlic S, Grossetête R, Auget JL, Dary C. Long-term follow-up of Vena Tech-LGM filter: predictors and frequency of caval occlusion. *J Vasc Interv Radiol*. 1999;10:137-142.
 6. Habito CR, Kalva SP. Inferior vena cava filter thrombosis: a review of current concepts, evidence, and approach to management. *Hosp Pract (1995)*. 2011;39(3):79-86.
 7. Raju S, Neglén P. Percutaneous recanalization of total occlusions of the iliac vein. *J Vasc Surg*. 2009;50:360-368.
 8. Neglén P, Oglesbee M, Olivier J, Raju S. Stenting of chronically obstructed inferior vena cava filters. *J Vasc Surg*. 2011;54:153-161.
 9. Mas JL, Derumeaux G, Guillon B, et al. Patent foramen ovale closure or anticoagulation vs. antiplatelets after stroke. *N Engl J Med*. 2017;377:1011-1021.
 10. Reddy VY, Holmes D, Doshi SK, Neuzil P, Kar S. Safety of percutaneous left atrial appendage closure: results from the Watchman Left Atrial Appendage System for Embolic Protection in Patients with AF (PROTECT AF) clinical trial and the Continued Access Registry. *Circulation*. 2011;123:417-424.

How to cite this article: Rakotonoel RR, Rioufol G, Uhlrich W, Derimay F. Percutaneous atrial septal defect occlusion through thrombosed inferior vena cava filter. *Clin Case Rep*. 2021;9:e04350. <https://doi.org/10.1002/ccr3.4350>