

A rare asymptomatic retroperitoneal endometriotic cyst with mass effect on the inferior vena cava

Tracy YS Cui¹, Tiffany CL Wong^{1,2,3}, Chung-Mau Lo^{1,2,3}

¹Department of Surgery, Queen Mary Hospital, Hong Kong

²Department of Surgery, The University of Hong Kong, Hong Kong

³Department of Surgery, The University of Hong Kong-Shenzhen Hospital, China

Corresponding author

Dr. Tiffany CL Wong

Clinical Assistant Professor

Department of Surgery

The University of Hong Kong

Queen Mary Hospital

102 Pok Fu Lam Road, Hong Kong

Email: wongtcl@hku.hk

Telephone no: 852-22554748

Facsimile no: 852-28162765

Disclosure: Informed consent was obtained from the patient to publish the medical images.

Conflict of interest: The authors declare no conflict of interest.

1 **A rare asymptomatic retroperitoneal endometriotic cyst with mass effect on**
2 **the inferior vena cava**

3

4 A 40-year-old lady was referred for an asymptomatic retroperitoneal cystic mass that was
5 incidentally found on transabdominal ultrasound. She was nulliparous. Besides a history of
6 pelvic inflammatory disease, she was otherwise healthy. Physical examination and blood
7 tests including tumour markers were normal. A contrast magnetic resonance imaging(MRI)
8 of the abdomen showed a 9.4x6.4x4.8 cm non-enhancing retroperitoneal cystic lesion,
9 located inferior to the head of pancreas and anterior to infrarenal inferior vena cava(IVC).
10 The IVC was slit-like and there was venous collateral inferior to the lesion. The cyst was
11 eumetabolic on F¹⁸ fluorodeoxyglucose positron emission tomography(¹⁸FDG PET)(Figure 1).

12

13 The differential diagnoses included enteric duplication cyst, mesenteric cyst, pancreatic
14 pseudocyst, or pancreatic cystic neoplasms. The absence of fat content on MRI and
15 eumetabolism on PET made retroperitoneal liposarcoma unlikely. Exploratory laparotomy
16 and excision of retroperitoneal cyst was offered in view of its size and mass effect to IVC.

17 Upon laparotomy, with right sided medial visceral rotation the IVC and aorta were exposed.
18 The cystic was densely adhered to infrarenal IVC, right ovarian vein and right ureter(Figure
19 2). The cyst was excised completely and it did not arise from surrounding organs.

20 Lymphadenectomy at aortocaval region and renal hilum was performed. The rest of
21 laparotomy did not identify other cystic lesion; the uterus and ovaries were normal. On
22 histological examination, the lesion consisted of haemorrhagic fibro-connective tissue and
23 packed spindle cells forming endometrial type stroma. The cells demonstrated positivity to
24 CD 10 and estrogen receptor, which was consistent with endometriosis. As patient did not
25 have fertility wish, she was started on gonadotropin-releasing hormone agonist by
26 gynaecologist.

27

28 Extrapelvic endometriosis is rare and there were less than a dozen reports on
29 retroperitoneal pericaval/periaortic endometriosis in the literature[1,2]. Surgical resection
30 might be warranted as it might create diagnostic difficulty and mass effect to surrounding
31 structures.

1

2 **References**

- 3 1. Lu J, Zhao JY, Xiong XZ, Cheng NS. An unusual retroperitoneal endometriotic cyst in a
4 young woman. *Dig Liver Dis* 2019;51:324.
- 5 2. Kelemen PR. Extrapelvic retroperitoneal endometrioma. *Am J Surg* 2002;184:52-3.

1 **Figure legends**

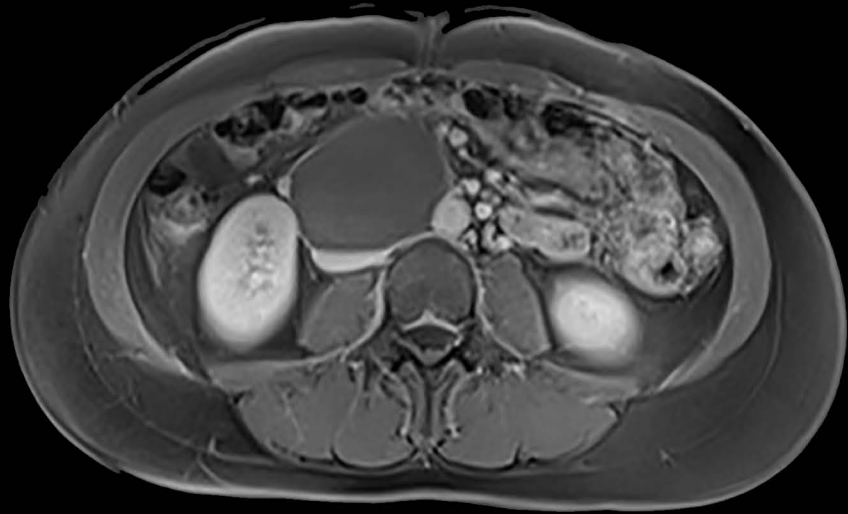
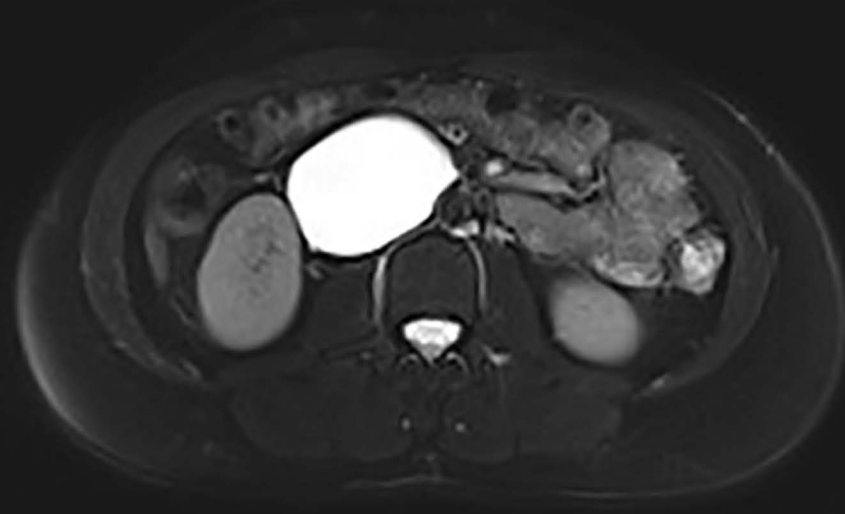2 Figure 1a. The retroperitoneal cyst caused significant mass effect to inferior vena cava. It
3 was iso/hyperintense on T1-weighted MRI.

4 Figure 1b. The retroperitoneal cyst was homogeneously hyperintense on T2-weighted MRI.

5 Figure 1c. The cyst was eumetabolic on ¹⁸F FDG PET.

6 Figure 2a. The cystic was densely adhered to the IVC which was slung by blue tape. Multiple
7 small venous collateral surrounded the cyst.

8 Figure 2b. The cyst was excised *en bloc* with surrounding lymphatics.

a)**b)****c)**