



Severe TBI patients without focal lesion but with behavioral disorders: shrinkage of gray matter nuclei and thalamus revealed in a pilot voxel based MRI study

Alexis Ruet, Françoise Joyeux, Shailendra Segobin, Corine Jokic, Béatrice Desgranges, Francis Eustache, Anne-Lise Pitel

► To cite this version:

Alexis Ruet, Françoise Joyeux, Shailendra Segobin, Corine Jokic, Béatrice Desgranges, et al.. Severe TBI patients without focal lesion but with behavioral disorders: shrinkage of gray matter nuclei and thalamus revealed in a pilot voxel based MRI study. Journal of Neurotrauma, inPress, Epub ahead of print. inserm-01721457

HAL Id: inserm-01721457

<https://inserm.hal.science/inserm-01721457>

Submitted on 2 Mar 2018

HAL is a multi-disciplinary open access archive for the deposit and dissemination of scientific research documents, whether they are published or not. The documents may come from teaching and research institutions in France or abroad, or from public or private research centers.

L'archive ouverte pluridisciplinaire **HAL**, est destinée au dépôt et à la diffusion de documents scientifiques de niveau recherche, publiés ou non, émanant des établissements d'enseignement et de recherche français ou étrangers, des laboratoires publics ou privés.

Title:

Severe TBI patients without focal lesion but with behavioral disorders: shrinkage of gray matter nuclei and thalamus revealed in a pilot voxel based MRI study.

Authors:

Alexis Ruet, Françoise Joyeux, Shailendra Segobin, Corine JOKIC, Béatrice Desgranges, Francis Eustache, Anne-Lise Pitel

Alexis RUET (corresponding author)

mail: ruet-a@chu-caen.fr

Fax: 02 31 06 50 47

phone: 02 31 06 47 21

Françoise JOYEUX

mail: f.joyeux@ch-aunay.fr

fax: 02 31 71 76 79

phone: 02 31 71 76 61

Shailendra SEGOBIN

mail: segobin@cyceron.fr

fax: 02 31 56 83 91

phone: 02 31 47 02 47

Corinne JOKIC

mail: c.jokic@ch-aunay.fr

fax: 02 31 71 76 79

phone: 02 31 71 76 61

Béatrice DESGRANGES

mail: beatrice.desgranges@unicaen.fr

fax: 02 31 56 83 91

phone: 02 31 56 83 81

Francis EUSTACHE

mail: francis.eustache@unicaen.fr

fax: 02 31 56 83 91

phone: 02 31 56 83 90

Anne-Lise PITEL

mail: pitel@cyceron.fr

fax: 02 31 56 83 91

phone: 02 31 47 01 25

Abstract:

After a traumatic brain injury (TBI), behavioral disorders can occur without major focal brain lesion and in this case, their pathophysiology remains unclear. The aim of this study is to examine whether TBI patients with behavioral disorders but without any focal damage, as observed from an initial clinical CT scan, present subtle volumetric alterations that could be measured voxel-by-voxel in the whole brain with magnetic resonance imaging (MRI). Eight severe TBI male adults with behavioral sequela but without major focal cerebral lesion and 17 age-matched controls underwent a volumetric T1-weighted 1.5T MRI. A two-step analysis was performed. First, gray and white matter (GM and WM) volumes were compared between groups using Voxel-Based Morphometry. Second, we examined brain regions systematically damaged using the sum of the individual binary maps obtained from z-maps thresholded at -1.75 for significant GM and WM atrophy. TBI patients had lower GM volume than controls ($p < 0.001$, uncorrected) in the right parahippocampal gyrus, the left and right superior, middle and inferior temporal gyri, left superior frontal gyrus, right middle frontal gyrus, thalami, mammillary bodies, caudate nuclei, insulae, cerebellar cortex and vermis. WM volume was lower ($p < 0.001$, uncorrected) in the TBI group compared with controls in the periventricular area and around the basal nuclei. We found shrinkage in the dorsomedial thalami in each of the TBI patients, and in the posterior part of the right putamen and caudate nuclei in 7 TBI patients. Shrinkage in the dorsomedial thalami and in the posterior part of the right putamen and caudate nuclei may be the common effect of the disseminated microscopic lesions and be associated with behavioral issues in severe TBI patients without major focal lesions.

Keywords: Traumatic Brain Injury, MRI scan, Behavioral disorders, Adult

Traumatic brain injury (TBI) is a major cause of long-term disability. Owing to its frequency notably in young population, TBI is an important socioeconomic problem.¹ Long-lasting effects of TBI frequently include cognitive, emotional, physical and sensory disabilities. Cognitive and behavioral disorders often disrupt social and professional integration.² The relationship between behavioral disorders following TBI and cerebral lesions remains unclear. TBI can lead to both focal and diffuse brain damage with widespread structural changes resulting in reduced overall brain volume.³ Behavioral disorders are expected when a focal lesion affects cerebral regions involved in behavioral regulation, such as in the prefrontal cortices. But, how can we explain behavioral disorders when no focal brain lesion can be identified with usual clinical imaging tools such as CT scan? The aim of this study is to examine whether TBI patients with behavioral disorders but without focal damage on the CT scan present subtle volumetric alterations measured voxel-by-voxel in the whole brain with magnetic resonance imaging (MRI).

Volumetric differences using voxel-based morphometry techniques applied to MRI examinations conducted more than 3 months post-injury were examined in patients with severe TBI (GCS 4-8) and a median PTA >40 days but without noticeable injury on the initial CT scan or focal pathology >5mm. The TBI group consisted of 8 male adults with persisting behavioral disorders (Lhermitte's scale) consecutive to a severe TBI (initial Glasgow Coma Scale [GCS] score of 8 or less).⁴ Lhermitte's scale is composed of 80 items assessing behavioral disorders that are grouped in 16 categories (5 items in each). A trained neuropsychologist indicates for each item whether the behavioral modification is observed in the patient since TBI according to a multidisciplinary team and the patients' relatives. For example, "he/she can hardly move from one activity to another" refers to a stereotypical behavior. Inclusion criteria were the following: preserved intellectual abilities (score not below -2 standard deviation on Raven's Standard Progressive Matrices 38) and posttraumatic amnesia ended for at least one month. Patients were excluded if they had a history of other neurological or psychiatric disease, alcohol use disorder, severe anterograde amnesia (score below 2 standard deviation on the Free and Cued Selective Reminding Test) or current depression (Beck Depression Inventory).⁵⁻⁷ A group of age-matched adult controls were selected.

All participants (patients and controls) underwent a high-resolution volumetric T1-weighted MRI scan (1.5T Signa Advance Echospeed; General Electric Milwaukee, WI) which consisted of a set of 128 adjacent axial planes parallel to the anterior commissure–posterior commissure line with a pixel size of 0.9375 mm² and slice thickness of 1.5 mm, using a spoiled gradient echo sequence (repetition time = 10.3 ms; echo time = 2.1 ms; field of view = 240 x 180 mm²; matrix = 256 x 192).

Gray and white matter (GM and WM) volumes were analyzed using the Voxel Based Morphometry (VBM5) toolbox in the Statistical Parametric Mapping (SPM) software.⁸ Briefly, the image preprocessing steps included segmentation of the MRI data into gray matter (GM) and spatial normalization to the Montreal Neurological Institute (MNI) template (voxel size = 1 mm³, matrix = 156 x 189 x 157). The normalized GM images were modulated by the Jacobian determinants to

correct for non-linear warping only so that the resulting brain volumes were corrected for brain size. The resulting images were smoothed by a Gaussian kernel of 12 mm full-width-at-half-maximum (FWHM) and masked so as to include only GM or WM. The GM mask was obtained taking the unmodulated GM images of controls normalized in MNI space, averaging them and thresholding the resultant mean image at 0.5. The same principle was applied for the WM data.

First, we first performed a two-sample t-test for GM and WM volume comparisons between TBI and controls. An uncorrected $p < 0.001$ was used and the cluster threshold was set at $k = 200$ contiguous voxels. Second, for each patient, we computed individual z-score maps of GM and WM volumes at a voxel level $[(\text{patient individual value} - \text{control mean}) / \text{control standard deviation}]$. These individual maps were then thresholded in order to obtain a value of 1 in voxels with significant atrophy and a value of 0 elsewhere. The threshold of -1.75 was chosen (corresponding to the t-value for $p < 0.05$ (one-tailed), with 15 degrees of freedom for a control sample size of 17). We then summed the individual atrophy maps to clearly display the voxels affected in all TBI patients, thus highlighting the between-subject variability and commonalities.

Demographic characteristics, initial severity and main neuropsychological results of the 8 male TBI patients are provided in table 1. Median age in the control group was 40 [20-58]. The most common behavioral disorders, with a score at least of 3/5 on Lhermitte's sub-scales were "dependence on the social environment" (7/8 patients), "apathy" (6/8 patients) and "lack of interest" (6/8 patients). Between-group differences for GM and WM volumes are illustrated in figure 1 A and B. Regarding GM, TBI patients had significantly ($p < 0.001$, uncorrected) lower volumes than controls in the right parahippocampal gyrus, the dorsomedial thalami, the cerebellar cortex bilaterally and in lower and upper part of the cerebellar vermis, left middle temporal gyrus, right insula, right superior, inferior and middle temporal gyrus, right caudate nucleus, left superior frontal gyrus, left caudate nucleus, right superior temporal gyrus, right middle frontal gyrus, left insula and left inferior temporal gyrus. Shrinkage in the right parahippocampal gyrus, right putamen and in the upper part of the vermis remained significant with a more restrictive threshold ($p < 0.05$ FWE (Family Wise Error)).

WM volume was significantly lower ($p < 0.001$, uncorrected) in the TBI group compared with controls in a large area including periventricular WM, WM lying around the basal nuclei but sparing the internal capsule, corpus callosum, body of the fornix, mesencephalic and pontine WM. Small areas of atrophy were also located in subcortical WM of frontal lobes, left superior temporal gyrus, left precuneus, left middle occipital gyrus and right supra marginal gyrus. WM atrophy was still significant at a $p < 0.05$ FWE in the superior longitudinal fasciculus bilaterally and right fornix crus.

The sum of individual patterns of atrophy are shown in figure 1C. Shrinkage was systematically observed (in all 8 TBI patients) in the dorsomedial thalami and the posterior part of the right putamen. In 7 TBI patients out of 8, the caudate nuclei, and a larger part of the right putamen and of the dorsomedial thalami were atrophied.

Few studies have examined patterns of cerebral atrophy after severe TBI and most of them focused on whole brain volume shrinkage.¹⁰ Those studies did not restrict inclusions to patients with almost no focal lesions as in the present study. In a VBM investigation, GM atrophy was found in the right thalamus, bilateral pallidum and the cingulum, right post central gyrus, supplementary motor area, right precentral gyrus, and bilateral putamen.¹¹ Another study conducted in mild to severe TBI patients revealed volume loss in amygdala, hippocampus, thalami bilaterally and in right putamen, right cuneus and right superior frontal cortex.¹² Region of interest (ROI) based studies revealed that severe TBI leads to GM atrophy of hippocampi and dorsomedial thalami as well as WM atrophy of the fornix and corpus callosum.^{13,14} TBI patients had also greater volume decline over time compared to controls in corona radiata, corpus callosum, internal capsule, external capsule, the superior and inferior longitudinal fasciculus, cingulum, inferior fronto-occipital fasciculus, corticospinal tract, superior, middle, and inferior cerebellar peduncles, and small regions of cerebellar WM.¹¹

Our results confirm these previous findings and emphasize structural brain abnormalities in thalami, basal ganglia and periventricular WM in a specific population of severe TBI patients exhibiting persisting behavioral disorders/sequela, which could not be explained by clinically detectable focal cerebral lesion. Since injury causing experiments cannot be performed on humans, brain deformation dynamics leading to TBI remain unclear. Biofidelic computer models aim to simulate regional brain deformations leading to damage in response to a traumatic impact. According to recent engineering models of traumatic brain injury, these areas may be especially vulnerable to the shear and strain forces.⁹ GM and WM shrinkage observed in deep regions of the brain could thus result from microscopic lesions induced by these shear and strain forces. While brain damage in TBI is usually spatially heterogeneous, the VBM analysis of MRI data revealed that the cerebral cortex seemed relatively spared, even in frontal areas, but thalami and right putamen were systematically atrophied in those patients suggesting common effects of TBI microscopic lesions in this particular population.

In such selected population, behavior disorders could be related to thalami and basal ganglia lesions rather than frontal cortical lesions. Although not statistically tested in our work, this assumption is plausible as such damage could interrupt functional loops connecting cortex, thalami and basal ganglia evolved in goal directed and reward seeking behaviors.¹⁵ Limited focal lesions of dorsomedial part of thalamus or caudate nuclei have already been described in stroke patients and led to cognitive and behavior disorders such as personality changes with disinhibited behavior, apathy and loss of self-activation.^{16–20} Right putamen volume loss was correlated with higher primary reward seeking scores in behavioral variant frontotemporal dementia.²¹

The first limitation to consider in this study is the small sample size. However, the studied sample was very carefully selected to include only patients with severe TBI, very limited focal brain lesions, behavior disorders in absence of impaired intellectual ability and major episodic memory disorder. Further studies are required with a larger sample size to make possible the comparison of severe TBI patients with and without behavior disorders and the study of the relationship between cerebral volume and severity of behavior disorders. The second limitation of our study is the absence of specific MRI sequence to detect microbleeds such as gradient echo sequence-based susceptibility weighted imaging. Microbleeds, an important imaging marker for diffuse axonal injury, were found to be correlated with functional outcome in TBI patients.²² Finally, this pilot study did not take into account the time since injury although cerebral atrophy seems to increase with time even when cognitive performance improves.^{11,12}

No competing financial interests exist

References

1. Maas AIR, Stocchetti N, Bullock R. (2008). Moderate and severe traumatic brain injury in adults. *Lancet Neurol.* 7:728-741.
2. Brasure M, Lamberty GJ, Sayer NA, Nelson NW, Macdonald R, Ouellette J, Wilt TJ. (2013). Participation after multidisciplinary rehabilitation for moderate to severe traumatic brain injury in adults: a systematic review. *Arch Phys Med Rehabil.* 94:1398-1420.
3. Levine B, Kovacevic N, Nica EI, Cheung G, Gao F, Schwartz ML, Black SE. (2008). The Toronto traumatic brain injury study: injury severity and quantified MRI. *Neurology.* 70:771-778.
4. Lhermitte F, Pillon B, Serdaru M. (1986). Human autonomy and the frontal lobes. part I: imitation and utilization behavior: a neuropsychological study of 75 patients. *Ann Neurol.* 19:326-334.
5. Raven JC. Guide to using progressive matrices (1938). United Kingdom of Great Britain and Northern Ireland: Dumfries, H.K. Lewis & Co., Wm Grieve & Sons,
6. Grober E, Buschke H. (1987). Genuine memory deficits in dementia. *Dev Neuropsychol.* 3:13-36.
7. Beck AT, Ward CH, Mendelson M, Mock J, Erbaugh J. (1961). An inventory for measuring depression. *Arch Gen Psychiatry.* 4:561-571.
8. SPM5 software. Wellcome Trust Centre for Neuroimaging.
9. Ganpule S, Daphalapurkar NP, Ramesh KT, Knutsen AK, Pham DL, Bayly P V., Prince JL. (2017). A three-dimensional computational human head model that captures live human brain dynamics. *J Neurotrauma.* 34:2154-2166.
10. Ross DE. (2011). Review of longitudinal studies of MRI brain volumetry in patients with traumatic brain injury. *Brain Inj.* 25:1271-1278.
11. Bendlin B, Ries ML, Lazar M, Alexander AL, Dempsey RJ, Rowley HA, Sherman JE, Johnson SC. (2008). Longitudinal changes in patients with traumatic brain injury assessed with diffusion tensor and volumetric imaging. *Neuroimage.* 42:503-514.
12. Warner MA, Youn T, Davis T, Chandra A, Marquez de la Plata C, Moore C, Harper C, Madden CJ, Spence J, McColl R, Devous M, King R, Diaz-Arrastia R, Author C. (2010). Regionally selective atrophy after traumatic axonal injury. *67149:1336-1344.*
13. Avants B, Duda JT, Kim J, Zhang H, Pluta J, Gee JC, Whyte J. (2008). Multivariate analysis of structural and diffusion imaging in traumatic brain injury. *Acad Radiol.* 15:1360-1375.
14. Tomaiuolo F, Carlesimo GA, Paola M Di, Petrides M, Fera F, Bonanni R, Formisano R, Pasqualetti P, Caltagirone C. (2004). Gross morphology and morphometric sequelae in the hippocampus, fornix, and corpus callosum of patients with severe non-missile traumatic brain injury without macroscopically detectable lesions: a T1 weighted MRI study. *J Neurol Neurosurg Psychiatry.* 75:1314-1322.
15. Haber SN, Knutson B. (2010). The reward circuit: linking primate anatomy and human imaging. *Neuropsychopharmacology.* 35:4-26.

16. Bogousslavsky J, Ferrazzini M, Regli F, Assal G, Tanabe H, Delaloye-Bischof A. (1988). Manic delirium and frontal-like syndrome with paramedian infarction of the right thalamus. *J Neurol Neurosurg Psychiatry*. 51:116-119.
17. Carrera E, Bogousslavsky J. (2006). The thalamus and behavior effects of anatomically distinct strokes. *Neurology*. 66:1817–1823.
18. Mrabet A, Mrad-Ben Hammouda I, Abroug Z, Smiri W, Haddad A. (1994). [Bilateral infarction of the caudate nuclei]. *Rev Neurol (Paris)*. 150:67-69.
19. Narumoto J, Matsushima N, Oka S, Shimizu H, Kooguchi Y, Kitabayashi Y, Kunizawa M, Ueda H, Fukui K. (2005). Neurobehavioral changes associated with bilateral caudate nucleus infarctions. *Psychiatry Clin Neurosci*. 59:109-110.
20. Petty RG, Bonner D, Mouratoglou V, Silverman M. (1996). Acute frontal lobe syndrome and dyscontrol associated with bilateral caudate nucleus infarctions. *Br J Psychiatry*. 168:237-240.
21. Perry DC, Sturm VE, Seeley WW, Miller BL, Kramer JH, Rosen HJ. (2014). Anatomical correlates of reward-seeking behaviours in behavioural variant frontotemporal dementia. *Brain*. 137:1621-1626.
22. Park J-H, Park S-W, Kang S-H, Nam T-K, Min B-K, Hwang S-N. (2009). Detection of traumatic cerebral microbleeds by susceptibility-weighted image of MRI. *J Korean Neurosurg Soc*. 46:365-369.

Patients	MM	CD	CC	GR	SP	LD	ED	NP	
Age (years)	46	41	30	49	29	43	20	55	39
Cultural level	2	2	1	1	1	1	1	1	
Initial GCS score	7	6	6	8	4	8	6	7	
Post Traumatic Amnesia (days)	45	35	42	70	NA	NA	21	77	48
Time since TBI (months)	5	10	12	12	27	35	3	19	1
PM 38 score	124	108	100	105	90	110	115	100	107
Free and cued recall (16-items)	15	16	15	16	15	15	15	15	15
Total delayed recall									
Lhermitte Scale subscores :									
- Apathy	5	0	4	1	5	3	3	3	
- Restlessness	1	0	2	2	0	1	0	0	
- Stereotypy	3	2	3	4	3	0	2	4	
- Impulsiveness	1	0	0	0	0	4	0	0	
- Indifference	0	3	0	0	5	1	1	5	
- Euphoria	3	0	3	0	0	0	0	2	
- Lack of interest	3	3	0	4	3	1	4	4	
- Cheerfulness	4	0	2	1	0	0	0	0	
- Dependence on the social env.	4	2	4	4	5	4	5	4	
- Indifference to social rules	3	1	1	1	0	0	0	0	
- Decrease in attention	1	3	3	2	3	0	4	4	
- Dependence on the physical env.	3	0	1	0	0	0	0	0	
- Programming disorders	4	2	3	2	5	2	5	4	
- Personality disorders	4	1	5	5	2	4	1	3	
- Loss of intellectual control	2	0	2	4	4	1	0	5	
- Loss of emotional control	3	1	2	5	2	4	3	4	

Table 1. Cultural level: 1<10y of education, 2≥10y; GCS: Glasgow Coma Scale Score; GCS: Glasgow Coma Scale; TBI: Traumatic Brain Injury; PM 38: Raven's Progressive Matrix 38.

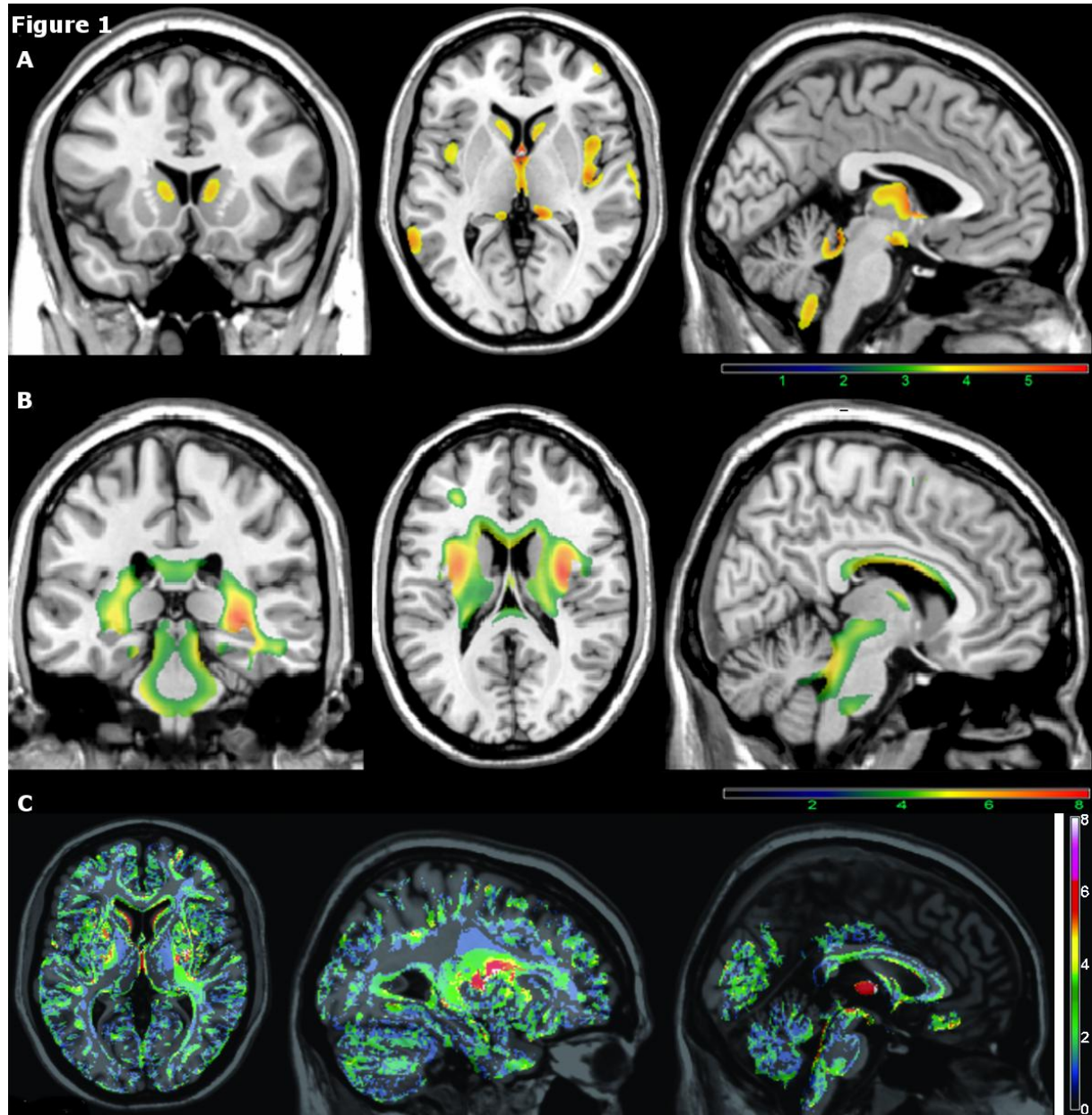


Figure 1. Gray matter (A) and white matter (B) atrophy in TBI patients compared with controls ($k > 200$). Between-group comparison conducted with SPM5 two-sample t-test routine. The color-bars represent the t value of significant voxels at a $p < .001$ uncorrected threshold. Results are shown in neurological orientation (right is right) and are displayed on the MNI template. C: Individual patterns of atrophy in the TBI patients. The color-bar represents the number of TBI patients with significant atrophy, voxel-by-voxel, present in all 8 TBI patients (white) to absent in all 8 (transparent). Results are shown in neurological orientation (right is right) and are displayed on the MNI template.