

A novel mutation in the ABCD1 gene of a Moroccan patient with X-linked adrenoleukodystrophy: case report

Adnane Karkar, Abdelhamid Barakat, Amina Bakhchane, Houda Fettah, Ilham Slassi, Imen Dorboz, Odile Boespflug-Tanguy, Sellama Nadifi

► **To cite this version:**

Adnane Karkar, Abdelhamid Barakat, Amina Bakhchane, Houda Fettah, Ilham Slassi, et al.. A novel mutation in the ABCD1 gene of a Moroccan patient with X-linked adrenoleukodystrophy: case report. BMC Neurology, BioMed Central, 2015, 15 (1), pp.244. <10.1186/s12883-015-0503-1>. <inserm-01264481>

HAL Id: inserm-01264481

<http://www.hal.inserm.fr/inserm-01264481>

Submitted on 29 Jan 2016

HAL is a multi-disciplinary open access archive for the deposit and dissemination of scientific research documents, whether they are published or not. The documents may come from teaching and research institutions in France or abroad, or from public or private research centers.

L'archive ouverte pluridisciplinaire **HAL**, est destinée au dépôt et à la diffusion de documents scientifiques de niveau recherche, publiés ou non, émanant des établissements d'enseignement et de recherche français ou étrangers, des laboratoires publics ou privés.

CASE REPORT

Open Access



A novel mutation in the *ABCD1* gene of a Moroccan patient with X-linked adrenoleukodystrophy: case report

Adnane Karkar^{1,2}, Abdelhamid Barakat³, Amina Bakhchane³, Houda Fettah⁴, Ilham Slassi⁵, Imen Dorboz⁶, Odile Boespflug-Tanguy^{6,7} and Sellama Nadifi^{2*}

Abstract

Background: X-linked adrenoleukodystrophy (X-ALD; OMIM: 300100) is the most common peroxisomal disease caused by mutations in the ATP-binding cassette, sub-family D member 1 gene or *ABCD1* (geneID: 215), the coding gene for the adrenoleukodystrophy protein (ALDP), which is an ATP-binding transport protein associated to an active transport of very long chain fatty acids (VLCFAs). Dysfunction of ALDP induces an accumulation of VLCFAs in all tissues leading to a neurodegenerative disorder that involves the nervous system white matter.

Case presentation: In our case report, magnetic resonance imaging (MRI) as well as the high levels of VLCFAs prompted the diagnosis the X-ALD. Molecular analysis of *ABCD1* gene have shown a pathogenic homozygous nonsense mutation (c.1677C > G; p.(Tyr559*)) in exon 7.

Conclusion: Thus, we identified here a novel mutation in the *ABCD1* gene in a Moroccan patient causing X-linked adrenoleukodystrophy.

Keywords: Nonsense mutation, *ABCD1*, ALDP, VLCFAs, X-linked Adrenoleukodystrophy

Background

X-linked adrenoleukodystrophy (X-ALD; OMIM: 300100) is the most common peroxisomal disease caused by mutations in the *ABCD1* (OMIM: 300371), the coding gene for the adrenoleukodystrophy protein (ALDP) [1]. ALDP is an ATP-binding transport protein involved in active transport of enzymes or cofactors implicated in very long chain fatty acids (VLCFAs) β -oxidation in peroxisomes. Therefore, a slight dysfunction of ALDP induces an accumulation of VLCFAs in all tissues [2]. This accumulation often leads to a neurodegenerative disorder in the nervous system's white matter, axons, adrenal cortex, and testes [3]. X-ALD is divided into two main phenotypes: The Child Cerebral ALD (CCALD) and the adrenomyeloneuropathy (AMN). Both of these forms may occur in the same family. However, there is no correlation between mutations in the gene *ABCD1* and the X-ALD phenotype [4].

Epidemiological studies reported that the estimated relative frequency in males with X-ALD is 31–35 % for childhood cerebral ALD and 40–46 % for AMN [5]. Moreover, the total frequency of X-ALD gene carriers is estimated to be 1/16800 for both hemizygous males and heterozygous women [6]. In the present study, a candidate gene approach was used to determine X-ALD related mutation in a Moroccan patient by analyzing the entire coding region of the *ABCD1* gene by direct Sanger sequencing.

Case presentation

The patient is a 7 years and 5 months old boy who has been adopted at birth with no information about the biological parents, therefore we were unable to realize an adequate family investigation with a pedigree and a molecular analysis for the biological mother. The patient had a normal development until he reached 6 years and 11 months old when he suddenly showed hearing difficulties, a decline in visual acuity and a hyperactivity. He also became violent and failed in school.

* Correspondence: nadifisel@yahoo.fr

²Genetics and Molecular Pathology Laboratory, Medical school of Casablanca, Hassan II University, Casablanca, Morocco

Full list of author information is available at the end of the article



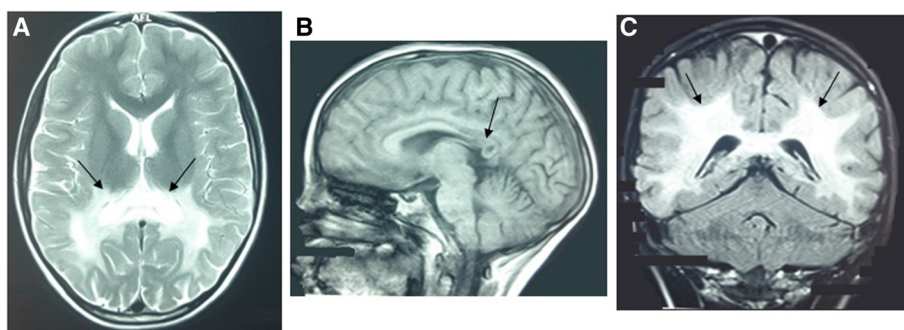


Fig. 1 Brain MRI of the patient with high signal intensity of the white matter in axial T2, the arrows show high signal in the corpus callosum (a), low signal intensity of the white matter in sagittal T1 (b), low signal in the splenium of corpus callosum (arrow B) and diffuse high signal intensity of the white matter in coronal Flair (arrows c)

The neurological examination revealed pyramidal syndrome of the lower limbs, walking difficulties and cerebellar ataxia. Besides, MRI images were consistent with active demyelination as usually observed in childhood cerebral ALD. A high bilateral symmetrical signal intensity was detected in T2 and Flair within the pons and midbrain. Furthermore, a low signal intensity was found in T1 and a diffuse high signal intensity of the white matter in T2 and Flair within the parietal-occipital area and the splenium of corpus callosum (Fig. 1).

Visual evoked potential (VEP) and brainstem auditory evoked potential (BAEP) tests have shown that both visual and auditory pathways evoked potential damage. Serum cortisol level reveals that the adrenal glands were not affected. VLCFAs analysis (Table 1) by liquid chromatography-tandem mass spectrometry (LC-MS/MS) revealed high levels of C24/C22 and C26/C22 ratio in plasma.

Genomic DNA was extracted from peripheral blood samples using standard phenol–chloroform extraction method. The DNA concentration and purity were determined using a nanodrop spectrophotometer (NanoVue™-NV - General Electric Healthcare Limited, UK). Polymerase chain reaction (PCR) primer pairs of the *ABCD1* coding regions were designed following the NCBI Reference Sequence: NM_000033.3 (Table 2).

Table 1 VLCFAs analysis

VLCFAs	Patient	Normal control
C22 mg/L	40.6	1.827 to 22.161
C22 μmol/L	119.364	5.371 to 65.153
C24 mg/L	72.8	1.228 to 18.837
C24 μmol/L	197.288	3.328 to 51.048
C26 mg/L	4.68	<1.03
C26 μmol/L	11.747	<2.585
C24/C22 ratio	1.793	0.665 to 1.008
C26/C22 ratio	0.115	0.009 to 0.069

DNA sequence analysis of the ten coding exons of *ABCD1* gene, including the flanking region of each exon (exon-intron boundaries) was performed using conventional Sanger sequencing. DNA samples were first amplified in a final volume of 25 μl containing: 1× reaction buffer, 1× Q-Solution, 200 μM of each dNTP, 2 mM MgCl₂, 1 μM of primers, 2.5 U Hotstar Taq polymerase and 50 ng of genomic DNA (Qiagen GmbH, Hilden, Germany). PCR conditions were as follows: denaturation at 95 °C for 15 min; 94 °C for 1 min; 60 °C- for 1 min; and 72 °C for 1 min for 35 cycles followed by a 10 minute final extension at 72 °C. PCR products were electrophoresed on a 1 % agarose gel and visualized with ethidium bromide staining under ultraviolet light to verify their size and quantity. All the PCR products were treated with exonuclease I and shrimp alkaline phosphatase enzymes prior to sequencing according to the following protocol: 37 °C for 40 min and 80 °C for 15 min. The sequencing reaction was performed on the purified products using the BigDye Terminator v 1.1 Standard Kit (Applied Biosystems, Foster City, CA, USA). Electrophoresis of samples was performed on the 3100 ABI Applied Biosystems sequencer (Applied Biosystems, Foster City, CA, USA).

A mutation was identified in the exon 7 of the *ABCD1* gene, with C substituted by G at nucleotide 1677, corresponding to the stop codon at the residue 559.

The ALDP potentially generated by the appearance of the stop codon exclude a part of exon 7, 8, 9 and 10 coding for the ATP binding domain (Fig. 2).

Conclusion

The first clinical case of X-linked adrenoleukodystrophy was described by Haberland and Spieler in 1910 [7]. Sixty years later, Blaw introduced the name adrenoleukodystrophy relative to adrenal insufficiency correlated with leukodystrophy [8]. In 1981, adrenoleukodystrophy locus was identified at the long arm of the X chromosome [9]. Afterwards, the gene related to the X-ALD (*ABCD1*) was identified using positional cloning strategies in 1993[1].

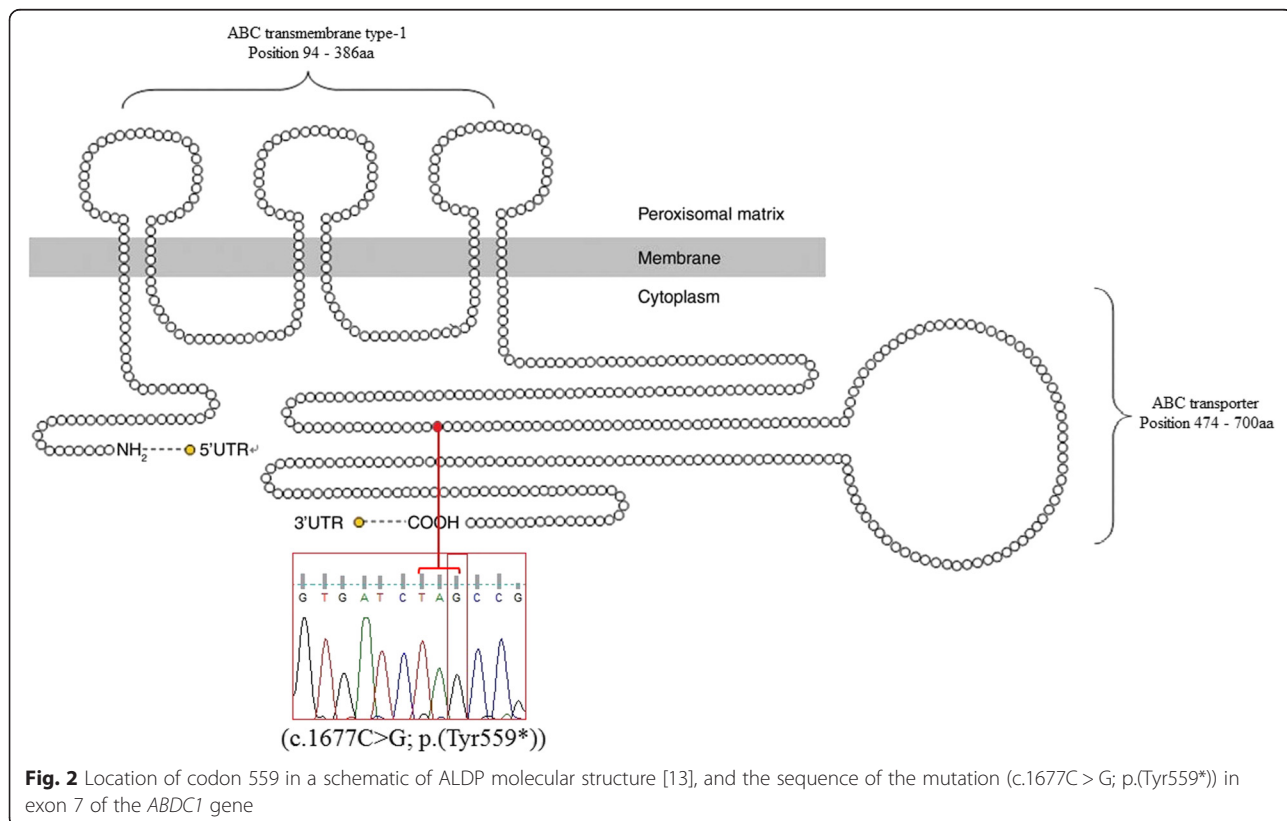
Table 2 *ABCD1* gene primers sequences

Exons	Forward 5' to 3'	Reverse 3' to 5'	Size
1(first part)	AGCAACAATCCTCCAGCCA	CACCACGTCCTCCGTCAGA	689
1(second part)	CTGCTACCTTCGTAACAG	CCCACACCTTTGGCATCAG	593
2	GTGACTAGAGAGGGAGTGG	GGCTTGCTGAGTGGTAAC	657
3	CATCAGCCTGTGATGTGCTC	TGGGCCTCTGAAGTGACAG	531
4	GTGAAGAAGGCAGCCTTGG	CCAGAAGCACATGGAGGTC	509
5	AGACTCCCCAGAATGCAGAG	GGCTGAGGCTTGCCATATGTG	216
6	CTCTCAAGGCTGGTCAGGAG	CTTCACCACTTCTGGGCCT	312
7	CGATGTGAGCGTGTGGATG	GGCACCTGGCATTTAGAC	372
8 and 9	GGAACTGAGCCAAGACCATT	CTGCTGATGACAGCCGCT	493
10	TGACCCTGTCCCTCTCCTG	GCTGCTGTCTCCTCATGTG	322

To date, 1605 mutations have been reported, 703 of them are non-recurrent mutations while 162 others are nonsense and 132 are located in exon 7 (<http://www.x-ald.nl>). In our study, we identified a novel nonsense mutation in exon 7 (c.1677C > G; p.(Tyr559*)) of a Moroccan patient, there is also another mutation found in the same residue by J. Haasjes & P.A.W. Mooijer in The Netherlands and S.J.S. Steinberg in USA but the nucleotide change is in one position behind our mutation (c.1676A > G; p.(Tyr559Cys)), this mutation is one of the unpublished data in the X-ALD database (<http://www.x-ald.nl>). No previous studies has investigated the *ABCD1* gene in the

Moroccan population. Indeed, only one study reported the same single mutation (c.659 T > C) in three families of Moroccan Jewish descent, probably due to a founder effect [10]. In the North African population, only two other mutations (c.284C > A; p.(Ala95Asp)) and (c.1780 + 2 T > G) of *ABCD1* gene were described in Tunisian patients [11, 12] . All these data lead us to think that the mutations in the *ABCD1* gene are very heterogeneous and their identification in the North African population are very scarce.

Nowadays, Moroccan population has better access to MRI and dosage of VLCFA is requested as soon as the



clinical picture is suggestive of X-linked adrenoleukodystrophy. Thus, we expect to have more information about the incidence of the mutations and the frequency of X-ALD within the Moroccan population in the near future.

Consent

Patient was seen at the Memory Consultation group at the CHU IBN ROCHD Neurology Department in Casablanca, Morocco. The protocol was approved by the human ethics committee of the CHU IBN ROCHD in accordance with the declaration of Helsinki for experiments involving humans and written consent was obtained from the guardians prior to the study.

Abbreviations

X-ALD: X-linked adrenoleukodystrophy; ABCD1: ATP-binding cassette, sub-family D member 1; ALDP: Adrenoleukodystrophy Protein; VLCFAs: Very Long Chain Fatty Acids; MRI: Magnetic Resonance Imaging; CCALD: Child Cerebral ALD; AMN: Adrenomyeloneuropathy; VEP: Visual Evoked Potential; BAEP: Brainstem Auditory Evoked Potential; PCR: Polymerase Chain Reaction.

Competing interests

The authors declare that no competing interests exist.

Authors' contributions

IS had the neurological patient contacts and acquired the data and drafted the manuscript. IS conceived the case report. All authors critically performed the protocol, discussed the data and drafted the manuscript. All authors read and approved the final manuscript.

Acknowledgements

We are indebted to the proband's family for their invaluable cooperation and for providing blood samples.

Author details

¹Inserm U1141, Paris Diderot University, Sorbonne Paris Cité, Robert Debré Hospital, Paris, France. ²Genetics and Molecular Pathology Laboratory, Medical school of Casablanca, Hassan II University, Casablanca, Morocco. ³Laboratoire de Génétique Moléculaire Humaine, Département de la Recherche Scientifique, Institut Pasteur du Maroc, Casablanca, Morocco. ⁴Department of Neuropediatrics, Hassan II University Hospital, 9154 Casablanca, Morocco. ⁵Department of Neurology, Hassan II University Hospital, 9154 Casablanca, Morocco. ⁶Inserm U1141, Paris Diderot University, Sorbonne Paris Cité, DHU PROTECT, Robert Debré Hospital, Paris, France. ⁷Reference Center For Leukodystrophies, Department of Neuropediatrics and Metabolic Diseases, Robert Debré Hospital, AP-HP, Paris, France.

Received: 6 August 2015 Accepted: 21 November 2015

Published online: 25 November 2015

References

- Mosser J, Douar AM, Sarde CO, Kioschis P, Feil R, Moser H, et al. Putative X-linked adrenoleukodystrophy gene shares unexpected homology with ABC transporters. *Nature*. 1993;361:726–30.
- Singh I, Moser HW, Moser AB, Kishimoto Y. Adrenoleukodystrophy: impaired oxidation of long chain fatty acids in cultured skin fibroblasts and adrenal cortex. *Biochem Biophys Res Commun*. 1981;102:1223–9.
- Moser HW. Adrenoleukodystrophy: phenotype, genetics, pathogenesis and therapy. *Brain*. 1997;120:1485–508.
- Kemp S, Berger J, Aubourg P. X-linked adrenoleukodystrophy: Clinical, metabolic, genetic and pathophysiological aspects. *Biochim Biophys Acta BBA - Mol Basis Dis*. 1822;2012:1465–74.
- Kemp S, Pujol A, Waterham HR, van Geel BM, Boehm CD, Raymond GV, et al. ABCD1 mutations and the X-linked adrenoleukodystrophy mutation database: role in diagnosis and clinical correlations. *Hum Mutat*. 2001;18:499–515.

- Bezman L, Moser AB, Raymond GV, Rinaldo P, Watkins PA, Smith KD, et al. Adrenoleukodystrophy: incidence, new mutation rate, and results of extended family screening. *Ann Neurol*. 2001;49:512–7.
- Haberfeld DW, Spieler DF. Zur diffusen Hirn-Rückenmarksklerose im Kindesalter. *Dtsch Z Für Nervenheilkd*. 1910;40:436–63.
- Blaw ME. Melanodermic type leukodystrophy (adrenoleukodystrophy). *Handb Clin Neurol*. 1970;10:128–33.
- Migeon BR, Moser HW, Moser AB, Axelman J, Sillence D, Norum RA. Adrenoleukodystrophy: evidence for X linkage, inactivation, and selection favoring the mutant allele in heterozygous cells. *Proc Natl Acad Sci U S A*. 1981;78:5066–70.
- Neumann S, Topper A, Mandel H, Shapira I, Golan O, Gazit E, et al. Identification of new mutations in Israeli patients with X-linked adrenoleukodystrophy. *Genet Test*. 2001;5:65–8.
- Kallabi F, Hadj Salem I, Ben Salah G, Ben Turkia H, Ben Chehida A, Tebib N, et al. Molecular Characterization of X-Linked Adrenoleukodystrophy in a Tunisian Family: Identification of a Novel Missense Mutation in the ABCD1 Gene. *Neurodegener Dis*. 2013;12:207–11.
- Kallabi F, Hadj Salem I, Ben Chehida A, Ben Salah G, Ben Turkia H, Tebib N, et al. Splicing defects in ABCD1 gene leading to both exon skipping and partial intron retention in X-linked adrenoleukodystrophy Tunisian patient. *Neurosci Res*. 2015;97:7–12.
- Cai Y, Jiang M, Liang C, Peng M, Cheng J, Sheng H, et al. A novel ABCD1 gene mutation in a Chinese patient with X-linked adrenoleukodystrophy. *J Pediatr Endocrinol Metab*. 2014.

Submit your next manuscript to BioMed Central and we will help you at every step:

- We accept pre-submission inquiries
- Our selector tool helps you to find the most relevant journal
- We provide round the clock customer support
- Convenient online submission
- Thorough peer review
- Inclusion in PubMed and all major indexing services
- Maximum visibility for your research

Submit your manuscript at
www.biomedcentral.com/submit

