

Statistical Analysis of White Matter Integrity for the Clinical Study of Specific Language Impairment in Children

Emmanuel Vallee, Olivier Commowick, Camille Maumet, Aymeric Stamm,
Elisabeth Le Rumeur, Catherine Allaire, Jean-Christophe Ferré, Clément De
Guibert, Christian Barillot

► **To cite this version:**

Emmanuel Vallee, Olivier Commowick, Camille Maumet, Aymeric Stamm, Elisabeth Le Rumeur, et al.. Statistical Analysis of White Matter Integrity for the Clinical Study of Specific Language Impairment in Children. MICCAI 2013 Workshop on Computational Diffusion MRI, Sep 2013, Japan. pp.187-195, 2013, <10.1007/978-3-319-02475-2_17>. <inserm-00849267>

HAL Id: inserm-00849267

<https://www.hal.inserm.fr/inserm-00849267>

Submitted on 6 Oct 2013

HAL is a multi-disciplinary open access archive for the deposit and dissemination of scientific research documents, whether they are published or not. The documents may come from teaching and research institutions in France or abroad, or from public or private research centers.

L'archive ouverte pluridisciplinaire **HAL**, est destinée au dépôt et à la diffusion de documents scientifiques de niveau recherche, publiés ou non, émanant des établissements d'enseignement et de recherche français ou étrangers, des laboratoires publics ou privés.

Statistical Analysis of White Matter Integrity for the Clinical Study of Typical Specific Language Impairment in Children

Emmanuel Vallée, Olivier Commowick, Camille Maumet, Aymeric Stamm, Elisabeth Le Rumeur, Catherine Allaire, Jean-Christophe Ferré, Clément de Guibert, and Christian Barillot

Abstract Children affected by Specific Language Impairment (SLI) fail to develop a normal language capability. To date, the etiology of SLI remains largely unknown. It induces difficulties with oral language which cannot be directly attributed to intellectual deficit or other developmental delay. Whereas previous studies on SLI focused on the psychological and genetic aspects of the pathology, few imaging studies investigated defaults in neuroanatomy or brain function. We propose to investigate the integrity of white matter in SLI thanks to diffusion Magnetic Resonance Imaging. An exploratory analysis was performed without *a priori* on the impaired regions. A region of interest statistical analysis was performed based, first, on regions defined from Catani's atlas and, then, on tractography-based regions. Both the mean fractional anisotropy and mean apparent diffusion coefficient were compared across groups. To the best of our knowledge, this is the first study focusing on white matter integrity in specific language impairment. 22 children with SLI and 19 typically developing children were involved in this study. Overall, the tractography-based approach to group comparison was more sensitive than the classical ROI-based approach. Group differences between controls and SLI patients in-

Emmanuel Vallée · Olivier Commowick · Camille Maumet · Aymeric Stamm · Jean-Christophe Ferré · Christian Barillot
Inria, INSERM, VisAGeS U746 Unit/Project, F-35042 Rennes, France

Elisabeth Le Rumeur · Jean-Christophe Ferré
University Hospital, Department of Neuroradiology, F-35033 Rennes, France

Catherine Allaire
Centre Toul-arC'hoat, F-29150 Chateaulin, France

Clément de Guibert
European University of Brittany-Rennes 2, LAS-EA 2241, F-35043, Rennes, France and University Hospital, Regional center for language and learning disorders, F-35033 France
Contact: e-mail: Olivier.Commowick@inria.fr

cluded decreases in FA in both the perisylvian and ventral pathways of language, comforting findings from previous functional studies.

1 Introduction

Some children fail to develop their language capability for no obvious reason. Their pathology typically induces difficulties with oral language, and cannot be attributed to intellectual deficit or other developmental delay. This developmental disorder is known as Specific Language Impairment [2].

The literature [2, 18] does not show evidence of brain lesion or educational issues, so the origin of the trouble is not well understood. While this pathology has been studied in its psychological or genetic aspects [3, 4], few studies have been conducted on the neuroanatomical and functional aspects. The current neuroanatomical hypothesis is a maturation default and/or an abnormal functional specialization of the networks dedicated to language.

SLI covers a large and heterogeneous clinical spectrum. In the context of this study, we focus on Typical-Specific Language Impairment (T-SLI), a subtype of the pathology, in which the trouble mainly affects the structural aspects of language (including morphosyntax and phonology) [9].

A functional MRI study was recently conducted by de Guibert et al. [9] on a group of subjects similar to ours. It revealed an abnormal lateralization of language function in patients. While the left hemisphere has usually a predominant role in language tasks, their study revealed a reduced activity in the supramarginal region of the left hemisphere (Geschwind area) and an increased activity in the right hemisphere close to the counterpart of Broca's region.

Earlier, Kim et al. published a study [11] on language impairment in children, using diffusion MRI. They measured the Fractional Anisotropy in six regions of the brain, and found a significant reduction in the genu of the corpus callosum. It can have an importance in language impairments as it is the main bundle that connects the two hemispheres and therefore manages connections between the two hemispheres, as shown by Preis et al. in [17]. Although their results are interesting, the study was led on very young children (mean 3.8 years old). It is then hard to differentiate a persistent language impairment from a transitional language retardation. Also, the specificity of the trouble can be questioned, as other non-language related troubles were not diagnosed. Filippi et al [7] led a diffusion imaging study on developmental delay in children. The study revealed an alteration of white matter bundles in affected children. Mao et al. [14] also conducted a diffusion imaging study where they showed that language impaired subjects had a decreased white matter integrity in the left frontal and medial temporal areas.

To the best of our knowledge, no previous study investigated white matter integrity in T-SLI. Understanding the neurological basis of SLI is of great interest as the specificity of the trouble allows to target a single impaired function (language) while most other developmental disorders are characterized by complex patterns of

clinical signs. In this paper, we aim at studying this integrity through the group comparison of diffusion weighted images between patients suffering from T-SLI and controls. Two different strategies were assessed for this exploratory comparison: classical region of interest (ROI) analysis and tractography-based analysis where ROIs are drawn from fiber bundles seeded from an atlas. We present in Section 2 the material and the processing pipeline. Then, we present in Section 3 the main findings of our study before discussing and concluding on these results.

2 Material and Methods

2.1 *Participants*

22 children diagnosed with T-SLI and 19 typically developing children were involved in this study. Two controls and one patient were excluded as diffusion MRI data was not acquired for these subjects. This resulted in a group of 21 children with T-SLI aged from 7 to 18 years old (mean age = 11.4 ± 3.3 , 9 males, 3 left-handed) and 17 control children aged from 8 to 18 years old (mean age = 12.5 ± 3.1 , 9 males, 1 left-handed). The T-SLI and control groups were similar for sex and handedness, and no significant between-group difference was found for age (two-sample t-test: $p=0.30$). None of the subjects exhibited any neurological abnormalities or auditory deficit, or was affected by communication, behavioral or attentional disorders. Visual inspection of anatomical 3D T1 and FLAIR images by an experienced neuroradiologist showed no significant abnormalities. For all children with T-SLI, impairment in the morphosyntactic or phonological component of language as well as preserved skills in non-verbal scores were assessed by neuropsychological tests [9].

2.2 *Data acquisition*

Acquisitions were performed on a 3 T whole-body scanner (Achieva, Philips Medical Systems) using an 8-channel head coil. Anatomical imaging included a 3D T1-weighted image with a Fast Field Echo sequence (TR = 9.9 ms, TE = 4.6 ms, flip angle = 8° , acquired matrix size: 256 x 256, voxel size: $1 \times 1 \times 1 \text{ mm}^3$, 160 slices) and a FLAIR sequence (TR = 11 ms, TE = 125 ms, flip angle = 90° , acquired matrix size: 352 x 233, voxel size: $0.34 \times 0.34 \times 4 \text{ mm}^3$, 34 slices). Diffusion images were acquired with 15 gradient directions, a b-value of 1000 s.mm^{-2} (TR = 10 ms, TE = 64 ms, flip angle = 90° , acquired matrix size: 128 x 128, voxel size: $2 \times 2 \times 2 \text{ mm}^3$, 60 slices).

2.3 Processing Pipeline

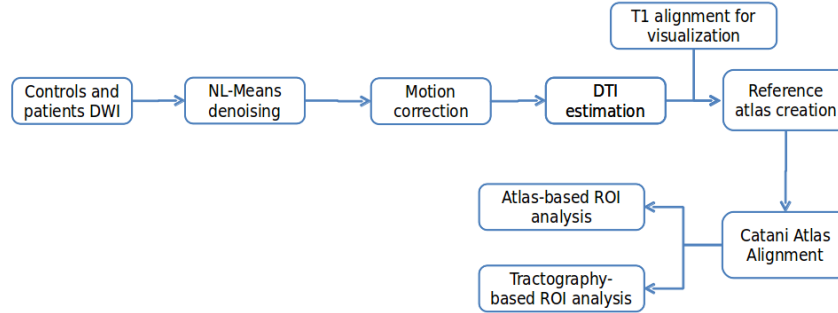


Fig. 1: Overall processing pipeline for DTI-based study of Specific Language Impairment.

We have performed an exploratory study on those two populations to infer differences in white matter organization related to T-SLI. To this end, we first investigated voxel-based analysis where images are brought onto a reference frame and voxel-wise comparisons of the diffusion parameters are performed. The indices compared included scalar values derived from the diffusion tensor: Apparent Diffusion Coefficient (ADC), or Fractional Anisotropy (FA), and the full-tensor itself in the log-Euclidean framework. However, this approach did not lead to conclusive results. Instead, we follow a ROI approach, based either on an atlas or on tractography results, following the pipeline presented in Fig. 1.

This pipeline consists first of preprocessing steps to improve the quality of diffusion tensor images. First, noise removal was performed on the DWI images utilizing the non-local means method (NL-Means) assuming Rician noise in the images [20]. Then, motion between successive diffusion images of each patient was corrected by registering all diffusion volumes on the reference B0 image of each patient, looking for a global rigid transform [16]. To keep the gradients and tensors aligned with the data, the linear parts of the rigid transformations (rotations) were applied to the gradients. Then, brain masking of the DWIs was performed. The threshold value was automatically computed from the diffusion images, after averaging the values of DW images, excluding the B0 image. Here, we used a cutoff at the first quartile of the intensity histogram of this average volume. If we apply this simple thresholding method, the brain mask can have holes where the values were low. A closing operation was therefore applied to the mask image to retrieve the missing values from the original image. Finally, tensors were estimated utilizing Fillard et al. log-Euclidean estimation method [8], ensuring that the estimated tensors are always positive definite.

All of the DTI volumes were then aligned into a single DTI atlas using Guimond et al. unbiased atlas construction method [10]. Each of the required registrations consisted of first finding a global affine transformation, followed by a full tensor-based non linear registration [19], which is a block-matching based registration with a generalized correlation coefficient as the similarity measure. For visualization purposes, all T1 images were also brought to this reference frame utilizing the obtained transformations. We then used Catani's atlas [6] to define ROIs for each patient or control, by non-linearly registering the FA image provided with Catani's atlas onto the FA image of our common frame. The analysis was then performed on each ROI choosing from two options:

- Compare mean FA and ADC values inside of the ROIs defined by Catani's atlas
- Perform tractography on each aligned DTI, based on Catani seeding ROIs, and use the envelopes of the obtained tracts as ROIs to compare mean FA and ADC

In summary, while the first approach amounts to an automated classical ROI-based analysis, the second approach could lead to more sensitive results as it focuses on the tracts extracted from each individual patient rather than on predefined regions. To build the tracts from the tensor images, we chose a deterministic approach that is widely used in tractography, called Fiber Assignment by Continuous Tracking (FACT), introduced by Mori et al. [15].

For each region, two-sample t-tests were performed to compare the patient and control groups. To avoid false positive detections, the results were corrected for multiple comparisons using FDR correction [1] with a q-value threshold of 0.05. For explanatory purposes, results displaying a trend to significance with an uncorrected p-value smaller than 0.05 were also retained for discussion.

3 Results

3.1 ROI-Based Analysis

Using ROI-based analysis, no regions were declared as significantly different from patients to controls after FDR correction. For exploratory purposes, we present regions with a trend to significance with an uncorrected p-value $p < 0.05$. This is reasonable as we computed 30 tests but the results have to be interpreted with care as they show a tendency.

Out of the 30 regions, three, illustrated in Fig. 2, presented a trend to significance: the Anterior Segment Left, the Anterior Segment Right and the Inferior Longitudinal Fasciculus Left. The Anterior Segment is part of the Arcuate Fasciculus which is the main fasciculus involved in language. The inferior longitudinal fasciculus is also related to language [13].

The ADC in the Anterior Segment Right was higher in patients than controls ($p=0.008$). The FA values were lower in patients than controls in the Anterior Segment Left ($p=0.035$) and in the Inferior Longitudinal Fasciculus Left ($p=0.009$).

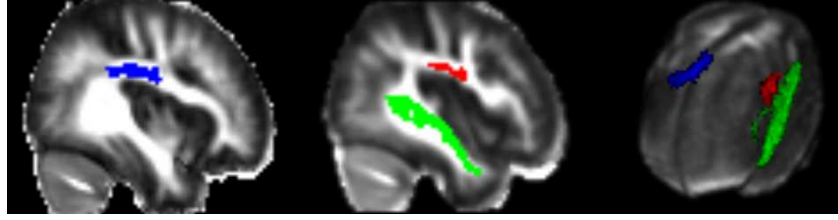


Fig. 2: **Regions as defined in Catani’s Atlas that differ from controls to patients;** $p < 0.05$, uncorrected; Blue: Anterior Segment Right, Red: Anterior Segment Left, Green: Inferior Longitudinal Fasciculus Left

3.2 Tractography-Based Analysis

The tractography-based analysis using Catani’s atlas showed significant differences in terms of FA and only some trends for ADC. Out of 30 regions under study, 10 presented a significant between-group difference. In all detected regions, a decrease in FA was observed in patients by comparison to controls as described in Table 1.

Bundle name	FA Control	FA Patient	q-Value
Anterior Segment Right	0.375±0.0134	0.362±0.0168	0.0129
Arcuate Left	0.397±0.0127	0.384±0.0167	0.0126
Inferior Longitudinal Fasciculus Left	0.423±0.0154	0.406±0.0181	0.0046
Inferior Longitudinal Fasciculus Right	0.41±0.0202	0.393±0.0206	0.0153
Inferior Occipito Frontal Fasciculus Right	0.406±0.0184	0.387±0.0191	0.0031
Long Segment Left	0.411±0.013	0.394±0.0249	0.0163
Optic Radiations Left	0.427±0.0249	0.406±0.0241	0.0115
Optic Radiations Right	0.43±0.0511	0.395±0.0317	0.0113
Posterior Segment Right	0.407±0.0292	0.387±0.017	0.0135
Anterior Commissure	0.375±0.0214	0.358±0.0187	0.0119

Table 1: **Fibers bundles showing significant FA decrease in patients;** $q < 0.05$ FDR corrected

Most of the significantly different regions are related to language. While some fiber bundles such as Optic Radiations and Anterior Commissure are not related to language, the other ones (Anterior Segment Right, Inferior Longitudinal Fasciculus Left and Right, Inferior Occipito-Frontal Fasciculus Right, Long Segment Left and Posterior Segment Right) are directly involved in this function. We illustrate in Fig. 3 the fiber bundles related to language with an altered integrity in children diagnosed with T-SLI.

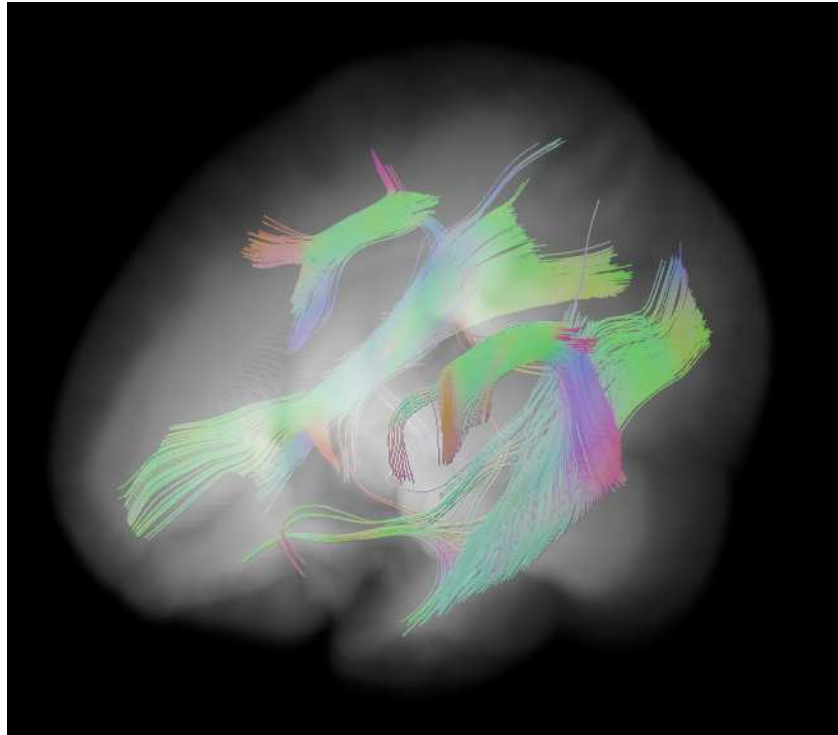


Fig. 3: **Language related tracts showing integrity decrease in patients; $q < 0.05$, FDR corrected; Anterior Segment Right, Arcuate Left, Inferior Longitudinal Fasciculus Left and Right, Inferior Occipito Frontal Fasciculus Right, Long Segment Left and Posterior Segment Right issued from tractography.**

4 Discussion and conclusion

We proposed two ROI-based approaches to analyze white matter integrity from Diffusion Weighted Images in children diagnosed with T-SLI. While the first one utilized ROIs defined directly from an atlas, the second approach used these regions as seeds for tractography which were in turn used for comparison of scalar indices. As expected, this second approach revealed a better sensitivity to detect differences as it focuses on the individual fiber bundles of the subjects.

Overall, this study revealed that several fiber bundles are impacted by T-SLI. The ROI based analysis exhibited interesting trends of differences in regions related to language. An increase of ADC correlated with a decrease of FA in patients was observed. This phenomenon is associated to brain maturation and myelination as described in [12]. The exploratory pipeline we followed revealed alteration of integrity of white matter in the perisylvian and ventral pathways, which are related to language functions [13, 5].

A previous study led by Kim et al. on language impairment [11] revealed a decrease of FA in the corpus callosum. Filippi et al. noted an increase of ADC in the cortical regions and a decrease of FA in white matter bundles (corpus callosum, and subcortical white matter of the frontal and parieto-occipital lobes) of children with developmental delay [7]. These pathologies can be compared to T-SLI as oral language is also impacted. Their findings are consistent with our results showing ADC decrease in the occipital, postcentral and temporal lobe of the left hemisphere. They also noted a decrease of FA in patients, comparable to the general tendency that we observed during the comparison of FA along fiber tracts.

Interestingly, the findings of this study also confirm previous functional studies on a similar dataset that had highlighted a different cortex functional organization in patients [9]. The hypo and hyper-activated cortical regions (Geschwind and Broca) revealed in the f-MRI study are connected through the white matter fiber bundles that differ from control to patient subjects (Arcuate and Inferior Longitudinal Fasciculus). Considering that alterations in ADC and FA in white matter fiber tracts are sensitive markers of white matter integrity, one can argue that several white matter bundles are impacted in children with T-SLI.

Future works will include refinements of the methodology and particularly using more advanced diffusion models (such as orientation distribution functions) to better capture the white matter organization. Also, the developed pipeline is by essence generic and will be applied to the study of other pathologies such as dementia or Parkinson's disease.

References

1. Benjamini, Y., Hochberg, Y.: Controlling the false discovery rate: A practical and powerful approach to multiple testing. *J. of the Royal Stat Society. Series B (Methodological)* **57**(1), 289–300 (1995)
2. Bishop, D.V.M.: *Uncommon understanding: Development and disorders of language comprehension in children*, vol. viii. Psychology Press/Erlbaum (UK) (1997)
3. Bishop, D.V.M.: Genetic and environmental risks for specific language impairment in children. *Philosophical Transactions of the Royal Society of London. Series B* **356**(1407), 369–380 (2001). DOI 10.1098/rstb.2000.0770
4. Bishop, D.V.M.: What causes specific language impairment in children? *Current Directions in Psychological Science* **15**(5), 217–221 (2006). DOI 10.1111/j.1467-8721.2006.00439.x
5. Catani, M., Mesulam, M.: The arcuate fasciculus and the disconnection theme in language and aphasia: History and current state. *Cortex* **44**(8), 953–961 (2008). DOI 10.1016/j.cortex.2008.04.002
6. Catani, M., Thiebaut de Schotten, M.: A diffusion tensor imaging tractography atlas for virtual in vivo dissections. *Cortex* **44**(8), 1105–1132 (2008)
7. Filippi, C.G., Lin, D.D.M., Tsiouris, A.J., et al.: Diffusion-tensor MR imaging in children with developmental delay: preliminary findings. *Radiology* **229**(1), 44–50 (2003)
8. Fillard, P., Pennec, X., Arsigny, V., Ayache, N.: Clinical DT-MRI estimation, smoothing, and fiber tracking with log-euclidean metrics. *IEEE TMI* **26**(11), 1472–1482 (2007). DOI 10.1109/TMI.2007.899173
9. de Guibert, C., Maumet, C., Jannin, P., Ferré, J.C., Tréguier, C., Barillot, C., Le Rumeur, E., Allaire, C., Biraben, A.: Abnormal functional lateralization and activity of language brain

- areas in typical specific language impairment (developmental dysphasia). *Brain* **134**(Pt 10), 3044–3058 (2011). DOI 10.1093/brain/awr141
10. Guimond, A., Meunier, J., Thirion, J.: Average brain models: A convergence study. *CVIU* **77**(2), 192–210 (2000)
 11. Kim, J., Kim, Y.W., Park, C.I., Park, E.S., Kim, H.H., Lee, S.K., Kim, D.I.: Diffusion-tensor magnetic resonance imaging in children with language impairment. *NeuroReport* **17**(12), 1279–1282 (2006). DOI 10.1097/01.wnr.0000230516.86090.67
 12. Löbel, U., Sedlacik, J., Güllmar, D., Kaiser, W., Reichenbach, J., Mentzel, H.J.: Diffusion tensor imaging: the normal evolution of ADC, RA, FA, and eigenvalues studied in multiple anatomical regions of the brain. *Neuroradiology* **51**(4), 253–263 (2009)
 13. Mandonnet, E., Nouet, A., Gatignol, P., Capelle, L., Duffau, H.: Does the left inferior longitudinal fasciculus play a role in language? a brain stimulation study. *Brain* **130**(3), 623–629 (2007)
 14. Mao, H., Polensek, S.H., Goldstein, F.C., Holder, C.A., Ni, C.: Diffusion tensor and functional magnetic resonance imaging of diffuse axonal injury and resulting language impairment. *J. of Neuroimaging* **17**(4), 292–294 (2007). DOI 10.1111/j.1552-6569.2007.00146.x
 15. Mori, S., Crain, B.J., Chacko, V.P., Van Zijl, P.C.M.: Three-dimensional tracking of axonal projections in the brain by magnetic resonance imaging. *Annals of Neurology* **45**(2), 265–269 (1999). DOI 10.1002/1531-8249(199902)45:2<265::AID-ANA21>3.0.CO;2-3
 16. Ourselin, S., Roche, A., Prima, S., Ayache, N.: Block matching: A general framework to improve robustness of rigid registration of medical images. In: *MICCAI, LNCS*, vol. 1935, pp. 557–566 (2000)
 17. Preis, S., Steinmetz, H., Knorr, U., Jäncke, L.: Corpus callosum size in children with developmental language disorder. *Cognitive Brain Research* **10**(1–2), 37–44 (2000). DOI 10.1016/S0926-6410(00)00020-3
 18. Rapin, I.: Practitioner review: Developmental language disorders: A clinical update. *J. of Child Psychology and Psychiatry* **37**(6), 643–655 (1996). DOI 10.1111/j.1469-7610.1996.tb01456.x
 19. Suarez, R.O., Commowick, O., Prabhu, S.P., Warfield, S.K.: Automated delineation of white matter fiber tracts with a multiple region-of-interest approach. *NeuroImage* **59**(4), 3690–3700 (2012). DOI 10.1016/j.neuroimage.2011.11.043
 20. Wiest-Daesslé, N., Prima, S., Coupé, P., Morrissey, S.P., Barillot, C.: Rician Noise Removal by Non-Local Means Filtering for Low Signal-to-Noise Ratio MRI: Applications to DT-MRI. In: *MICCAI (2), LNCS*, vol. 5242, pp. 171–179 (2008)