

# A qualitative and quantitative study of coronary artery MRA

Jérôme Velut<sup>1,2</sup>, Pierre-Axel Lentz<sup>3</sup>, Clément Philipot<sup>1,2</sup>, Marie-Paule Garcia<sup>1,2</sup>, Christine Toumoulin<sup>1,2</sup>

**Abstract**—In this paper, we propose an analysis of the coronary arterial tree obtained through magnetic resonance angiography (MRA). Ten datasets of the state-of-the-art SSFP MRI sequence are first qualitatively evaluated and labelled. Second, a quantitative analysis of anatomical and image features is performed. Finally, a comparison with an existing semi-automatic centreline extraction method is reported. The discussion deals with the clinical usage of such an imaging modality for both global anatomy visualisation and quantification purpose.

## I. INTRODUCTION

CARDIOVASCULAR diseases (CVD) remain the major cause of death in western countries. However, an earlier and better diagnostic of CAD based on the advances made in imaging modalities leads to a significant decrease of mortality. Imaging sources play an important role as it enables to detect and characterize potential pathological patterns and to elaborate sound planning for therapy and efficient patient follow up. They provide relevant anatomical knowledge of the human heart vasculatures which can be confronted to patient-specific data in a therapeutic or surgical decisional process. Despite the high resolution of the X-Ray angiography, the gold standard for coronary analysis, other techniques are increasingly being included in clinical protocols : Multidetector Computed Tomography (MDCT), Electron Beam Computed Tomography (EBCT) and Magnetic Resonance Angiography (MRA).

Recent works show that MRA could discriminate significant ( $> 50\%$ ) from non-significant stenoses [1], but they do not offer yet precise quantitative features. The state-of-art of MR sequences used for clinical studies are those based on steady-state free precession (SSFP) technique [2], [3], without contrast agent and in a free-breathing fashion.

Existing studies [4], [5] report a moderately high sensitivity for detecting proximal stenoses and performing congenital heart disease diagnostic.

In this paper, we propose an in-depth analysis of 10 whole-heart coronary arterial SSFP MRA. They were acquired on 1.5T systems (Philips Intera and Achieva) at end-diastolic phase without contrast agent. MR sequence parameters are summarized in table I. First, we expose the involved coronary arterial nomenclature. Then a qualitative and quantitative study is performed to confirm the conclusion of closely related papers, and allows us to be more precise on the annotation and to go deeper along the vessels. Finally, a

Parameters	
TR	4.04 – 4.75ms
TE	2.01 – 2.38ms
Flip angle	70.00 – 90.00
Pixel size	0.5 – 0.7mm
Matrix size	512 × 512
Slice distance	0.7 – 0.9mm
Number of slices	100 – 170

TABLE I  
MR SEQUENCE PARAMETERS

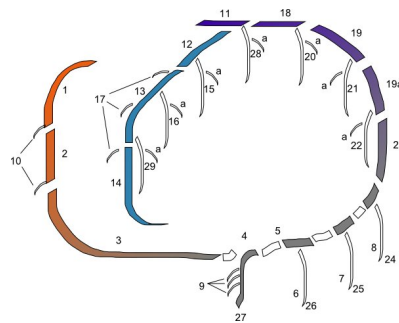


Fig. 1. Coronary artery map as proposed by the AHA [7]

preliminary comparison of the manual extractions against an existing semi-automatic centreline tracking algorithm [6] is presented and feeds the final discussion on factual benefits and future challenge of whole-heart coronary artery imaging.

## II. ANATOMICAL BACKGROUND

In the following and for the whole paper, anatomical nomenclature is based on the coronary map used in [7]. Figure 1 shows the anatomical locations, with the corresponding names depicted in table II. For clarity purpose, we propose reader-friendly acronyms that will be used in the remaining text.

## III. ANNOTATION AND MANUAL EXTRACTION

Existing studies, even recent, on whole-heart coronary MRA lack in-depth qualitative and quantitative analysis. In this section, we present the manually extracted coronary arterial trees from the ten datasets. First, the interactive process is described. Afterwards, an annotation performed by a radiologist is presented and confronted to the anatomical nomenclature. Finally, quantifications of vessel radius and image intensity are developed and discussed.

### A. Coronary arterial tree extraction procedure

The manual extractions have been first roughly performed by interactively pointing each slice of the volumes in the axial direction. Resulting curves are uniformly re-sampled

<sup>1</sup>LTSI, Université de Rennes 1, Campus de Beaulieu, Bât 22, Rennes, F-35042 Cedex

<sup>2</sup>INSERM, U642, Rennes, F-35000, France

<sup>3</sup>CHU Pontchaillou, Service de Radiologie, Rennes, F-35000

Segment	Acronym	Map location
1	RCA(p)	Proximal right coronary artery conduit segment
2	RCA(m)	Mid-right coronary artery conduit segment
3	RCA(d)	Distal-right coronary artery conduit segment
4	RPD	Right posterior descending artery segment
5	RPA	Right posterior atrioventricular segment
10	RCA-AM	Acute marginal segment(s)
11	LM	Left main coronary artery segment
12	LAD(p)	Proximal LAD artery segment
13	LAD(m)	Mid-LAD artery segment
14	LAD(d)	Distal LAD artery segment
15(a)	DIAG(1)	(Lateral) first diagonal branch segment
16(a)	DIAG(2)	(Lateral) second diagonal branch segment
18	CX(p)	Proximal circumflex artery segment
19(a)	CX(md)	Mid (distal)-circumflex artery segment
23	CX(g)	Circumflex artery AV groove continuation segment
29(a)	DIAG(3)	(Lateral) third diagonal branch segment

TABLE II  
CORONARY ARTERY MAP CORRESPONDENCE.

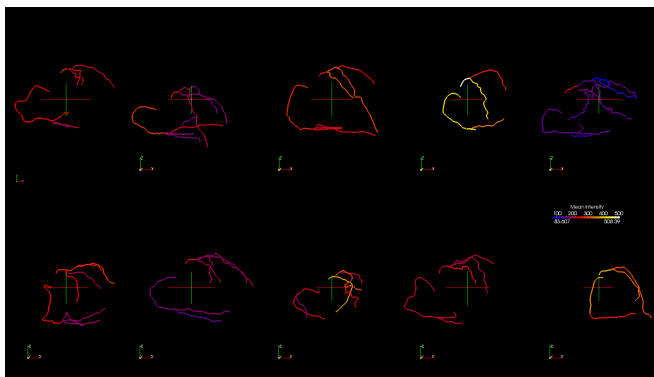


Fig. 2. Coronal views of ten coronary arterial trees manually extracted from MRA

and slightly smoothed. Figure 2 shows the ten arterial trees obtained after this interactive procedure. By slicing the MR dataset orthogonally to the curves, it is possible to carry out a straightened reformation of the arteries called Sa-CPR in the following.

The main drawback of an axial-exclusive slice pointing is that the centre of the vessel cannot be reliably located when the vessel runs tangent to the axial plane. It implies wrong centreline position for a non-negligible length of coronary arteries. To deal with this matter, the centreline is reconsidered by pointing on more truthful slices taken orthogonally to the rough extraction.

### B. Coronary arterial tree annotation

Figures 3(a) and 3(b) display several labelled slices from the coronary artery MRA dataset #2. Whether right or left coronary artery, the annotation has been successful down to the distal segments. The figure 2 illustrates the manual extraction of the coronary arteries from the ten datasets. The extracted segments are reported in tables III and IV in term of success rate of identification.

This analysis demonstrates the merits of MR imaging for coronary arteries. The whole proximal and medial segments have been extracted, and even the distal locations for the most part of the datasets. However, whereas these merits are

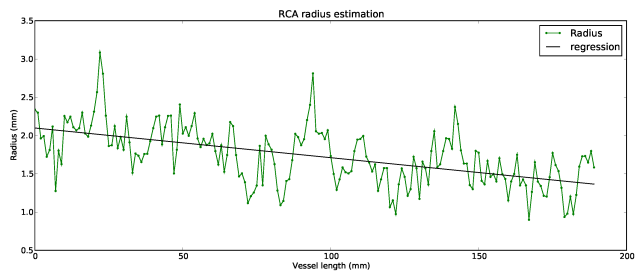


Fig. 4. Radius estimation along the RCA(p), RCA(m) and RCA(d) segments

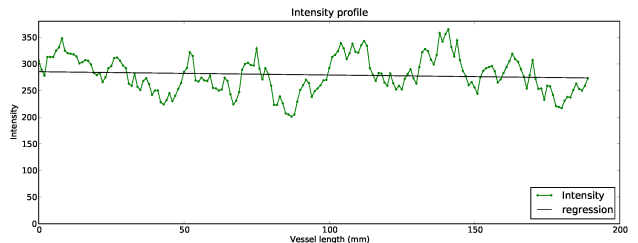


Fig. 5. Intensity measurement along the RCA(p), RCA(m) and RCA(d) segment centrelines

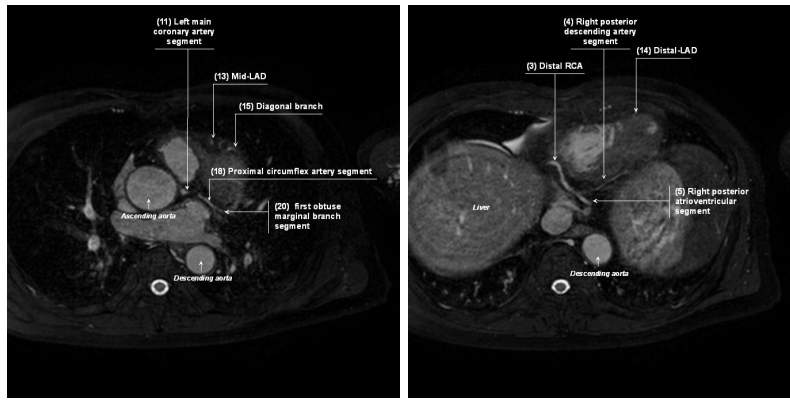
obvious in the case of a global coronary anatomy exploration, we are interesting in the following in assessing the MR modality for quantification purposes.

### C. Quantitative analysis

The characteristics presented in this work are the estimated radii and the image intensity probed along the corrected centreline.

1) *Estimated radii*: The radius is estimated at each Sa-CPR axial slice by pointing the north point of the vessel. As the radius is expected to decrease along a vessel, the result is presented through the simple linear regression parameters  $a$  (slope),  $y$ -intercept  $b$  and Pearson coefficient  $r$ . Figure 4 depicts the manually-pointed radius and the corresponding regression line for the RCA in one dataset. The regression slope is negative, that confirms the general decreasing trend expected along a vessel. However, the absolute Pearson correlation coefficient  $r$  is lower than  $\sqrt{3}/2$ , meaning that the dispersion around the regression line prevents a correct radius prediction. Results over the whole database show the same slowly-decreasing radius along the arterial segments but also a comparable variability of the estimated radii.

2) *Intensity measurement*: Figure 5 shows the intensity profile along the RCA of the volume #1 and the simple regression line. Although the slope of the regression lines are closed to zero reflecting an almost-constant intensity at centreline, the correlation coefficient highlights a highly-varying intensity along the vessels. The figure 2 shows that this variability is also encountered between different datasets, where mean intensity along the whole trees ranges from 186 to 469.



(a) Proximal left coronary artery

(b) Distal right coronary artery, right posterior segments and distal left coronary artery

Fig. 3. MRA coronary artery annotation. Examples of two labelled slices

RCA(p)	RCA(m)	RCA(d)	RPD	RPA	RCA-AM
100%	100%	100%	70%	80%	30%

TABLE III

SUMMARY OF EXTRACTED RCA SEGMENTS.

LM	LAP(p)	LAD(m)	LAD(d)	DIAG(1)	DIAG(2)	DIAG(3)	CX(p)	CX(md)
100%	100%	90%	60%	70%	10%	20%	100%	100%

TABLE IV

SUMMARY OF EXTRACTED LCA SEGMENTS.

#### IV. PRELIMINARY TESTING OF A SEMI-AUTOMATIC SEGMENTATION METHOD

The findings of the previous section support the need for automatic or at least semi-automatic methods. They will avoid inter- and intra operator variability as well as inter- and intra-patient and fasten the extraction process. The challenging points concern the low vessel resolution, the high intensity variability along a vessel and between patients, loss of signal due to either pathology or artefacts and finally the proximity of bright structures (veins, ventricles).

##### A. State-of-the art methods

The fast evolving capabilities of MRI make it really appealing for CAD diagnostic. However, the amount of data increases with image quality. Therefore a comprehensive analysis of a whole-heart coronary artery MRA examination will take more and more time.

A challenging problem today is thus to propose methods that help clinicians by extracting the entire coronary tree together with the required measurements, also for pathological cases, in a reasonable time. One can refer to [8] for a review on vessel extraction methods and to [9] for an evaluation framework dedicated to coronary artery segmentation methods. The existing segmentation methods have been mainly tested on X-Ray angiography or MDCT modalities. In the following, we assess a recent geometrical moment-based tracking method integrating multiple hypothesis testing

and regularization (MH-GMT) [6] and compare it with the manual extraction, considered here as ground truth.

##### B. Extraction results

Briefly speaking, the geometrical moment-based tracking methods are designed to extract a 3D curve from a volume, following a particular feature. As geometrical moments are able to compute the local orientation of a cylinder from image intensities, they are well-suited for vessel centreline extraction. The tracking starts from a seed point and iteratively build a curve from the estimated orientations until a stopping criterion is reached. The multiple hypotheses framework attenuates the tedious parameter tuning step. Figure 6 shows the ten arterial trees obtained together with the seed point locations.

In the following, we define over-detection and under-detection distances to assess the quality of the extracted arterial tree. Let  $\mathcal{T}_S$  be the tree obtained from MH-GMT and  $\mathcal{T}_R$  the manually extracted one. If  $p$  is a point from  $\mathcal{T}_S$  and  $q$  a point from  $\mathcal{T}_R$ , we define the over-detection distance  $OD$  as :

$$\forall p \in \mathcal{T}_S, OD_p = \min_{q \in \mathcal{T}_R} (\|pq\|) \quad (1)$$

This measure allows to detect points that belong to the semi-automatically extracted tree  $\mathcal{T}_S$  but do not belong to the reference tree. Figure 7(a) shows the over-detection distance ( $OD$ ) for each point.

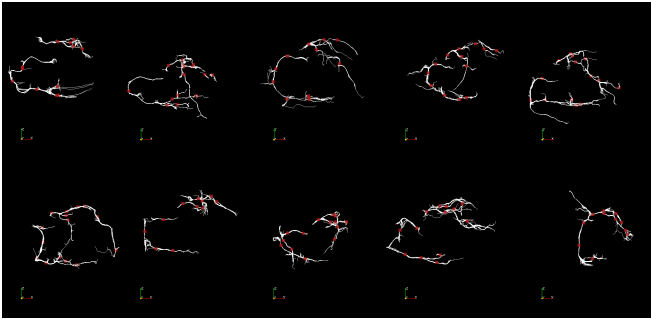


Fig. 6. Coronal view of the ten arterial tree obtained with MH-GMT method. Red squares depict the seed points locations.

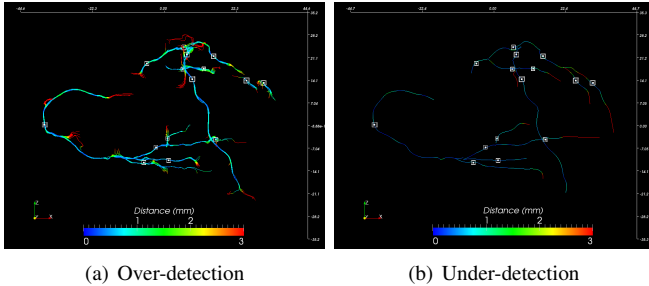


Fig. 7. A quality assessment through over- and under-detection

The symmetric measure of (1) is able to detect vessels from  $\mathcal{T}_R$  that cannot be find in  $\mathcal{T}_S$ . It is called the under-detection distance  $UD$  and is defined as :

$$\forall q \in \mathcal{T}_R, UD_q = \min_{p \in \mathcal{T}_S} (||pq||) \quad (2)$$

The visualization of  $UD$  for each reference point (figure 7(b)) underlines the missing segments in  $\mathcal{T}_S$ .

An average of the results over the ten processed datasets gives the following figures : 13 seed points have been used, computation time was 61s, 90% of the MH-GMT extracted points are less than 2mm far from the manually extracted ones ( $OD$  distance) and 85% of the manually extracted points are less than 2mm far from the MH-GMT extracted ones ( $UD$  distance).

## V. CONCLUSIONS

In this work, we have shown an unambiguous labelling of large parts of coronary arteries acquired by MR. To our knowledge, such a proof of the potential of MR imaging for coronary analysis at this depth was lacking. A global coronary anatomy should be reconstructed, bringing useful information for interventional planning.

We also showed that a MH-GMT is able to retrieve the labelled vessels thanks to 10 to 15 seed points. Therefore, without using any contrast product, MR leads to a performance comparable to MDCT [10].

Future works will deal with the capability of automatic method to delineate the vessel lumen with an high accuracy. This information is necessary for a reliable diagnosis and intervention planning.

## ACKNOWLEDGEMENTS

The research leading to these results has received funding from the European Community's Seventh Framework Programme (FP7/2007-2013) under grant agreement n° 224495 (euHeart project). We are also grateful toward Olivier Ecaibert and Juergen Weese from Philips Research Aachen for providing the MRA data sets.

## REFERENCES

- [1] M. Stuber, R. G. Weiss, Coronary magnetic resonance angiography., *J Magn Reson Imaging* 26 (2) (2007) 219–234.
- [2] B. Giorgi, S. Dymarkowski, F. Maes, M. Kouwenhoven, J. Bogaert, Improved Visualization of Coronary Arteries Using a New Three-Dimensional Submillimeter MR Coronary Angiography Sequence with Balanced Gradients, *Am. J. Roentgenol.* 179 (4) (2002) 901–910.
- [3] M. Ozgun, A. Hoffmeier, M. Kouwenhoven, R. M. Botnar, M. Stuber, H. H. Scheld, W. J. Manning, W. Heindel, D. Maintz, Comparison of 3D Segmented Gradient-Echo and Steady-State Free Precession Coronary MRI Sequences in Patients with Coronary Artery Disease, *Am. J. Roentgenol.* 185 (1) (2005) 103–109.
- [4] P. G. Danias, A. Roussakis, J. P. A. Ioannidis, Diagnostic performance of coronary magnetic resonance angiography as compared against conventional X-ray angiography : a meta-analysis., *J Am Coll Cardiol* 44 (9) (2004) 1867–1876.
- [5] P. Beerbaum, S. Sarikouch, K.-T. Laser, G. Greil, W. Burchert, H. Krperich, Coronary anomalies assessed by whole-heart isotropic 3D magnetic resonance imaging for cardiac morphology in congenital heart disease., *J Magn Reson Imaging* 29 (2) (2009) 320–327.
- [6] J. Velut, C. Toumoulin, J.-L. Coatrieux, 3D coronary structure tracking algorithm with regularization and multiple hypotheses in MRI, in : *ISBI, IEEE*, 2010, pp. 37–40.
- [7] P. J. Scanlon, D. P. Faxon, A. M. Audet, B. Carabello, G. J. Dehmer, K. A. Eagle, R. D. Legako, D. F. Leon, J. A. Murray, S. E. Nissen, C. J. Pepine, R. M. Watson, J. L. Ritchie, R. J. Gibbons, M. D. Cheitlin, T. J. Gardner, A. Garson, R. O. Russell, T. J. Ryan, S. C. Smith, ACC/AHA guidelines for coronary angiography. A report of the American College of Cardiology/American Heart Association Task Force on practice guidelines (Committee on Coronary Angiography). Developed in collaboration with the Society for Cardiac Angiography and Interventions., *J Am Coll Cardiol* 33 (6) (1999) 1756–1824.
- [8] D. Lesage, E. D. Angelini, I. Bloch, G. Funka-Lea, A review of 3D vessel lumen segmentation techniques : models, features and extraction schemes., *Med Image Anal* 13 (6) (2009) 819–845.
- [9] M. Schaap, C. T. Metz, T. van Walsum, A. G. van der Giessen, A. C. Weustink, N. R. Mollet, C. Bauer, H. Bogunović, C. Castro, X. Deng, E. Dikici, T. O'Donnell, M. Frenay, O. Friman, M. H. Hoyos, P. H. Kitslaar, K. Krissian, C. Khnel, M. A. Luengo-Oroz, M. Orkisz, O. Smedby, M. Styner, A. Szymczak, H. Tek, C. Wang, S. K. Warfield, S. Zambal, Y. Zhang, G. P. Krestin, W. J. Niessen, Standardized evaluation methodology and reference database for evaluating coronary artery centerline extraction algorithms., *Med Image Anal* 13 (5) (2009) 701–714.
- [10] A. Larralde, C. Boldak, M. Garreau, C. Toumoulin, D. Boulmier, Y. Rolland, Evaluation of a 3D Segmentation Software for the Coronary Characterization in Multi-slice Computed Tomography, in : *Functional Imaging and Modeling of the Heart*, 2003, pp. 39–51.