

Molecular characterization of a de novo 6q24.2q25.3 duplication interrupting UTRN in a patient with arthrogryposis.

Anne-Claude Tabet, Azzedine Aboura, Marion Gérard, Marion Pilorge, Céline Dupont, Jean-François Gadiouseux, Nadège Hervy, Eva Pipiras, Andrée Delahaye, Samia Kanafani, et al.

► **To cite this version:**

Anne-Claude Tabet, Azzedine Aboura, Marion Gérard, Marion Pilorge, Céline Dupont, et al.. Molecular characterization of a de novo 6q24.2q25.3 duplication interrupting UTRN in a patient with arthrogryposis.. American Journal of Medical Genetics Part A, Wiley, 2010, 152A (7), pp.1781-8. 10.1002/ajmg.a.33433 . inserm-00520796

HAL Id: inserm-00520796

<https://www.hal.inserm.fr/inserm-00520796>

Submitted on 24 Sep 2010

HAL is a multi-disciplinary open access archive for the deposit and dissemination of scientific research documents, whether they are published or not. The documents may come from teaching and research institutions in France or abroad, or from public or private research centers.

L'archive ouverte pluridisciplinaire **HAL**, est destinée au dépôt et à la diffusion de documents scientifiques de niveau recherche, publiés ou non, émanant des établissements d'enseignement et de recherche français ou étrangers, des laboratoires publics ou privés.

Molecular Characterization of a *De Novo* 6q24.2q25.3 Duplication Interrupting *UTRN* in a Patient With Arthrogryposis

Anne-Claude Tabet¹, Azzedine Aboura¹, Marion Gérard², Marion Pilorge^{3,4,5}, Céline Dupont^{1,6,7}, Jean-François Gadisseux², Nadège Hervy¹, Eva Pipiras⁷, Andrée Delahaye⁷, Samia Kanafani⁷, Alain Verloes², Brigitte Benzacken^{1,6,7}, Catalina Betancur^{3,4,5}

¹ AP-HP, Robert Debré Hospital, Department of Genetics, Cytogenetics Unit, Paris, France

² AP-HP, Robert Debré Hospital, Department of Genetics, Clinical Unit, Paris, France

³ Inserm U952, Paris, France

⁴ CNRS UMR 7224, Paris, France

⁵ UPMC Univ Paris 06, Paris, France

⁶ Inserm U676, Paris, France

⁷ AP-HP, Jean-Verdier Hospital, Cytogenetics Unit, Bondy, France

Corresponding author: Dr Anne-Claude Tabet, Cytogenetics Unit, Department of Genetics, Robert Debré Hospital, 48 Boulevard Serurier, 75019 Paris, France. E-mail: anne-claude.tabet@rdb.aphp.fr

ABSTRACT

Chromosome 6q duplications have been documented repeatedly, allowing the delineation of a “6q duplication syndrome”, characterized by hypertelorism, downslanting palpebral fissures, tented upper lip, short neck, severe mental and growth retardation, and joint contractures. Most reported cases result from malsegregation of a reciprocal translocation leading to a terminal 6q duplication and partial monosomy of another chromosome. Only 11 cases of *de novo* pure duplication have been reported so far. The breakpoints do not appear to be recurrent, but in most cases they have not been characterized molecularly, precluding genotype-phenotype correlation. We report on an 8-year-old girl with a phenotype consistent with mild 6q duplication syndrome, including characteristic physical findings, mild mental retardation, and joint contractures. She carries a 13 Mb *de novo* 6q24.2q25.3 duplication, diagnosed by high-resolution karyotype and confirmed by array-CGH. Molecular characterization of the duplicated segment with quantitative PCR showed that the proximal breakpoint is localized within the *UTRN* gene, encoding utrophin, the autosomal homologue of dystrophin. We discuss the possible implication of *UTRN* in arthrogryposis associated with duplications spanning the 6q23q26 region.

Key words: 6q duplication syndrome, joint contracture, utrophin, array-CGH, qPCR

INTRODUCTION

Chromosome 6q duplications have been documented repeatedly during the last 20 years [Dallapiccola *et al.*, 1978; Tipton *et al.*, 1979; Turleau and de Grouchy, 1981; Pivnick *et al.*, 1990; Uhrich *et al.*, 1991]. Even if the breakpoints on 6q are not recurrent, patients share a distinct phenotype, referred to as “6q duplication syndrome”, characterized by severe mental retardation, short stature, feeding difficulties, microcephaly, prominent forehead, downslanting palpebral fissures, flat nasal bridge, tented upper lip, micrognathia, short webbed neck, and joint contractures. Most reported cases result from malsegregation of a reciprocal translocation, leading to terminal 6q duplication and partial monosomy of another chromosome. Most duplications have not been characterized molecularly, precluding genotype-phenotype correlation studies.

Eleven cases of *de novo* pure duplications have been reported. Five cases cover the 6q21q23 region [Pratt *et al.*, 1998; Zneimer *et al.*, 1998; Pazooki *et al.*, 2007], one is restricted to the 6q23 region [Causio *et al.*, 2001], 4 span the 6q23.3q25.3 region [Ohta *et al.*, 1993; Henegariu *et al.*, 1997; Cappon *et al.*, 2000; Zweier *et al.*, 2008], and one is restricted to 6q26q27 [Brøndum-Nielsen *et al.*, 1993]. However, the breakpoints have not been defined precisely. Most cases were only studied by standard karyotype and fluorescent *in situ* hybridization (FISH) using whole chromosome painting probes [Ohta *et al.*, 1993; Henegariu *et al.*, 1997; Pratt *et al.*, 1998; Zneimer *et al.*, 1998; Cappon *et al.*, 2000], or yeast artificial chromosome (YAC) clones [Causio *et al.*, 2001; Pazooki *et al.*, 2007], while only one report used single nucleotide polymorphism (SNP) array [Zweier *et al.*, 2008].

Here we report on a girl with findings consistent with the 6q duplication syndrome, joint contractures and mental retardation. She carries a 13 Mb *de novo* 6q24.2q25.3 duplication, detected by high resolution karyotype and characterized by array comparative genomic hybridization (CGH) and quantitative PCR (qPCR). The proximal breakpoint is located within the *UTRN* gene, which shows both structural and functional similarities with the dystrophin gene, and could be involved in joint contractures.

CLINICAL REPORT

The girl is the second child of young, nonconsanguineous parents of French origin. The family history is unremarkable. During pregnancy, amniocentesis was prompted by a 1/80 risk of trisomy 21 by maternal serum markers. Chromosome analyses on amniocytes were considered to be normal. The ultrasound scan in the third trimester showed intra-uterine growth retardation. Fetal distress occurred during labor. At birth, at 38 weeks of gestation, weight was 2,250 g (1st centile), length 46 cm (5th centile), and occipitofrontal head circumference (OFC) 33 cm (20th centile). Apgar scores at 1, 5 and 10 min were 4, 5 and 7, respectively. She presented with generalized hypotonia, hypertelorism, thin horizontal eyebrows, micrognathia, and small mouth. Standard neonatal karyotype was also considered to be normal. On examination at 4 years 11 months of age, weight was 21.7 kg (+2.5 SD), height 118.5 cm (+3 SD; father's height: 190 cm, +3 SD), and OFC 49 cm (-1 SD). She had developmental delay; she began to walk at 23 months, and her speech was delayed (first words at 3 years and first sentences at

4 years). The minor anomalies were more apparent, and included thin horizontal eyebrows, midface hypoplasia with relative exophthalmia, and tented upper lip (Fig. 1A,B). Hands were long and narrow, with long palms and apparently normal creases (Fig. 1D). She had bilateral syndactyly of the 2nd and 3rd toes (Fig. 1C). Cutaneous dimples were present around the scapulae and proximal humeri (Fig. 1E). The knees and ankles were stiff, with calf amyotrophy, whereas the interphalangeal and metacarpophalangeal joints had normal mobility. Reflexes were brisk. During infancy, she had recurrent otitis media leading to mild conductive deafness. She was a late sleeper without nocturnal awakenings. She attended nursery school with extra help and received speech therapy; she was described as friendly and cooperative. A cerebral magnetic resonance imaging and an electroencephalogram were normal. Metabolic and fragile X syndrome screening were negative. A high-resolution karyotype performed at that time identified a *de novo* 6q24.2q25.3 duplication (see below).

At 7 years 10 months (Fig. 1B), the patient was seen for pain in the right forefoot. The growth curves remained unchanged: weight 29.5 kg (+2 SD), height 1.41 m (+3.5 SD), and OFC 50.5 cm (-1 SD). Developmental age was estimated to be around 4 years of age. She had joint contractures of both ankles, and generalized stiffness at articulations. Mild swelling at the right ankle and tendinous retraction of the right foot limiting flexion and extension were noted. The left foot showed the beginning of varus malposition, pes cavus, and hyperkeratosis under the third metatarsal, while the right foot showed a valgus deformity. Knees were stiff and painful at mobilization. Trophic limb changes included thin skin, tightness of tegument, and cold stiff limb segments. She had no pyramidal, cerebellar or vestibular dysfunction at neurological examination. An electromyogram was performed but was limited because of pain on the right leg; the surface study showed normal sensory and motor conduction. Skeletal X-rays studies did not find any osseous lesions. Hand X-ray showed slender and tubular-shaped metacarpals and phalanges, and disproportionately long proximal phalanges and first metacarpal (Fig. 2). Blood inflammatory markers were not elevated. Kinesitherapy and positional ankle casts were recommended.

METHODS

Standard Cytogenetic Analyses

High resolution banded chromosomes were analyzed on RBG and GTG from peripheral lymphocyte cultures of the patient and her parents.

Molecular Analyses

Array-CGH

Array-CGH was performed using an IntegraChip array (IntegraGen, Evry, France), containing 4895 bacterial artificial chromosome (BAC) and P1-based artificial chromosome (PAC) clones, with an average resolution of 1 Mb. For each hybridization, 400 ng of test and control DNA were random prime labeled using the BioPrime array-CGH Genomic Labeling kit (Invitrogen, Carlsbad, CA). Labeled products were purified with Qiaquick PCR purification kit (Qiagen, Valencia, CA). Slides were incubated

in a sealed hybridization chamber for 72 h at 55°C. Posthybridization treatments were performed as described previously [Guillaud-Bataille *et al.*, 2004], with minor modifications. Slides were scanned (Agilent, Santa Clara, CA), and data were extracted with GenePix Pro 6.0 software (Axon, Molecular Devices, Silicon Valley, CA). Copy number analysis was performed with GenoCensus (IntegraGen), which includes block Loess normalization.

FISH analyses

We used whole chromosome painting probe of chromosome 6 (WCP6, Oncor, Gaithersburg, MD) and a subtelomeric 6p/6q probe (Vysis, Downers Grove, IL). Probes were hybridized to metaphase slides of the patient. Specific BACs flanking the duplicated segment, RP11-320C12 localized on 6q24.3 and RP11-321K11 localized on 6q25.2, were nick-translated with fluorescein 12-dUTP and rhodamine 6-dUTP, respectively, and hybridized on metaphase spreads of the patient and her parents.

Real-time qPCR

Real time qPCR was used to confirm the duplication identified by array-CGH and to map the breakpoints. We used the Universal Probe Library (UPL) system (Roche, Indianapolis, IN). Probes were chosen using ProbeFinder v2.45 software (Roche, <http://www.universalprobelibrary.com>). Primers to be used with the UPL probes were also designed with the ProbeFinder application. Ten microliter reactions were assembled with 25 ng DNA, 400 nM of each primer, 100 nM UPL probe, and 1X LightCycler 480 Probe Master mix (Roche). All reactions were performed in triplicate. In addition to the DNA sample and the genes to be assayed for copy number, each 384-well plate included 3 control samples and 3 reference genes, as well as a no-template control for each gene. PCR conditions were as follows: 10 min denaturation at 95°C, then 40 cycles of 95°C for 15 sec and 60°C for 30 sec, followed by 30 sec cooling at 40°C. The plate was analyzed with a LightCycler 480 real time PCR system (Roche). Raw data were obtained with the LightCycler 480 software and exported for analysis into the qBase software [Hellemans *et al.*, 2007].

To map the proximal breakpoint, we used four probes in the *UTRN* gene, two intergenic probes localized between *UTRN* and *EPM2A*, one probe in *EPM2A*, and one probe in *GRM1*. To map the distal breakpoint, we analyzed one probe in each of *NOX3*, *ARID1B*, *ZDHHC14*, and *SNX9* genes, and three probes between *ZDHHC14* and *SNX9*.

RESULTS

Standard Cytogenetic Analyses

High-resolution karyotype (800 bands) suggested an interstitial duplication of the distal region of the long arm of chromosome 6 in the patient (Fig. 3A). High-resolution karyotypes of both parents were normal.

Molecular Analyses

FISH results

The WCP6 probe completely painted both chromosomes 6, confirming that the extra material was from chromosome 6. The subtelomeric 6p/6q probe hybridized the subtelomeric regions of both chromosomes 6, indicating that the 6q duplication was interstitial (data not shown). Two BAC specific probes flanking the duplicated region, RP11-320C12 localized on 6q24.3 (green) and RP11-321K11 localized on 6q25.2 (red), showed that it was a tandem interstitial duplication (Fig. 3B). The same BACs were hybridized on prometaphase spreads of both parents and no paracentric inversion was noted.

Array-CGH

Array-CGH analysis showed increased test/reference ratios for eight adjacent clones in the 6q24.3-q25.3 region, confirming the duplication (Fig. 4). The centromeric breakpoint was located between 145,415,000 Mb (end of the last disomic clone) and 146,065,000 (start of the first duplicated clone). The distal breakpoint laid between 157,912,000 Mb (end of the last duplicated clone) and 158,244,000 Mb (first non-duplicated clone after the duplicated segment). Thus, the minimal size of the duplication was 11.847 Mb overlapping the 6q24.3q25.3 region, and the maximal size was 12.829 Mb, at 6q24.2q25.3.

qPCR results

We used genomic qPCR to further delineate the breakpoints of the 6q duplication. At the proximal boundary, the *EPM2A* and *GRM1* genes, as well as two amplicons between *UTRN* and *EPM2A* were duplicated (Fig. 5). In the *UTRN* gene, the two proximal probes, in intron 1 and exon 42, appeared to be non duplicated, whereas the two distal probes, in exon 54 and intron 73, were duplicated, indicating that the proximal breakpoint lies within the *UTRN* gene, between exons 42 and 54 (144,854,245-145,069,547 Mb).

In the distal region, *NOX3*, *ARID1B*, *ZDHHC14*, and two probes in the 3' region of *ZDHHC14* were duplicated. A more distal probe in the 5' region of *SNX9* and another in *SNX9* appeared to be not duplicated (Fig. 5). These findings indicate that the distal breakpoint was localized in the 6q25.3 region, between *ZDHHC14* and *SNX9* (158,167,432-158,231,751 Mb).

From these analyses, the chromosomal anomaly was an interstitial duplication of the 6q24.2q25.3 region, with a length comprised between 13.10 and 13.38 Mb (proximal breakpoint, chr6:144,854,245-145,069,547; distal breakpoint, chr6:158,167,432-158,231,751).

DISCUSSION

Figure 6 shows a map of distal chromosome 6q and the previous cases compared to ours. In our patient, the breakpoints were fine mapped with qPCR and the minimal size of the duplication was determined to be 13,098 Mb (145.069-158.167 Mb). The proximal breakpoint was shown by qPCR to be located within the *UTRN* gene. This gene was not included in the duplicated segment according to the array-CGH results, which underestimated the size of the duplication, between 11.23 and 12.82 Mb.

According to the UCSC genome browser, the duplicated region in our patient encompasses 57 RefSeq genes (Fig. 6). Five of them are associated with distinct disorders. *EPM2A* is implicated in autosomal recessive progressive myoclonic epilepsy type 2 (EPM2), also known as Lafora disease [Minassian *et al.*, 1998]; *ESR1* is involved in breast cancer (somatic mutations), autosomal recessive estrogen resistance and susceptibility to atherosclerosis and myocardial infarction [Herrington *et al.*, 2002]; *SYNE1* is involved in autosomal recessive spinocerebellar ataxia type 8 [Gros-Louis *et al.*, 2007], and *IYD* causes autosomal recessive congenital hypothyroidism due to dysmorphogenesis type 4 [Moreno *et al.*, 2008]. Our patient did not exhibit any clinical sign of these disorders.

The proximal breakpoint of the duplication in our patient intersects the *UTRN* gene, between exons 42 and 54. Thus, this rearrangement could act like a deletion and result in haploinsufficiency of *UTRN*. *UTRN* encodes utrophin, a large skeletal muscle protein that shows both structural and functional similarities with the dystrophin gene [Burton *et al.*, 1999]. The utrophin protein is present in a wide variety of tissues, with the highest level of expression in lung and kidney. In skeletal muscle, utrophin is located at neuromuscular and myotendinous junctions, where it participates in the structural stability of the post-synaptic membrane and acetylcholine receptor clustering [Rafael and Brown, 2000]. Studies with double knockout mice for dystrophin and utrophin show that these mice exhibit a more severe phenotype than the two single phenotypes [Rafael and Brown, 2000], suggesting that utrophin and dystrophin play synergistic roles in functional or developmental pathways in skeletal muscle. Accordingly, over-expression of utrophin in muscles of dystrophin-null transgenic mice completely prevents the phenotype arising from dystrophin deficiency [Perkins and Davies, 2002]. Given the role of utrophin in the neuromuscular and myotendinous junction, we hypothesize that disruption of *UTRN* could explain the progressive development of stiff joint contractures and calf amyotrophy in our patient.

Four previous cases of 6q duplication span the 6q23q26 region and have breakpoints close to those of our patient [Ohta *et al.*, 1993; Henegariu *et al.*, 1997; Cappon *et al.*, 2000; Zweier *et al.*, 2008]. Ohta *et al.* do not give any clinical description of their patient [Ohta *et al.*, 1993]. Interestingly, the phenotype of our patient is very similar to the subjects described by the three other authors, including hypertelorism, almond-shaped palpebral fissures, tented upper lip, midface hypoplasia with relative exophthalmia, mild mental retardation, unusual cutaneous dimples, abnormalities of hands with ulnar deviation of fingers and joint contractures with calf amyotrophy [Henegariu *et al.*, 1997; Cappon *et al.*, 2000; Zweier *et al.*, 2008]. The patient reported by Cappon *et al.* [2000] was initially diagnosed as having Freeman-Sheldon syndrome, a disorder with characteristic face and distal arthrogryposis, indicating that the muscular and articular anomalies were significant. Furthermore, Grati *et al.* [2005] reported a fetus with a complex chromosome rearrangement including a 6q23q25.1 duplication with severe arthrogryposis assessed by ultrasound scan. The authors suggested the presence in 6q23q25 of a candidate gene involved in the fetal akinesia deformation sequence. In these four cases, even if the breakpoints of the duplication were not molecularly defined, *UTRN* (6q24.2) would be implicated in the duplication. Taken together, these findings suggest that increased copy number of *UTRN* and disruption of the gene may both deregulate *UTRN* function and result in similar phenotypic consequences. Notably, although the phenotype of the “6q duplication syndrome” often includes arthrogryposis, this is

not present in patients with proximal duplications not encompassing *UTRN* [Pratt et al., 1998; Zneimer et al., 1998; Pazooki et al., 2007]. The only exception is a patient with arthrogryposis and a duplication of the 6q23 band not including *UTRN* described by Causio et al. [2001]. Because this duplication was characterized by FISH using YAC probes, we hypothesize that there could be a mistake in the YAC position and the duplication could extend more distally to include *UTRN*, or alternatively, the duplication might exert a positional effect on *UTRN*.

In utrophin-deficient mice, despite the alteration of the ultrastructural postsynaptic region, there are only minimal electrophysiological alterations [Deconinck et al., 1997]. We suggest that *UTRN* could be a good candidate gene involved in joint contractures in cases of 6q duplication spanning the 6q24.2 region.

UTRN is also expressed at high levels in many nonmuscle tissues, and is known to have a role in brain function [Haenggi and Fritschy, 2006]. However, null mice for utrophin do not appear to have anomalies in other tissues [Rafael et al., 1999] and other genes likely contribute to the neurological phenotype. Mild to severe mental retardation is constant in the "6q duplication syndrome". In our patient, the duplicated segment encompasses *GRM1*, localized in 6q24.3. *GRM1* encodes for the metabotropic glutamate 1 (mGlu1) receptor, involved in synaptic activity and neurotransmitter release which are important for brain development, learning and memory. mGlu1 receptors have been implicated in the pathophysiology of several neurological and psychiatric disorders [Ferraguti et al., 2008]. Mutations in another glutamate receptor, *GRIK2*, are associated with autosomal recessive mental retardation [Motzack et al., 2007]. Overexpression of *GRM1* could be involved in the pathogenesis of mental retardation. Molecular studies of other patients are necessary to further define the genotype-phenotype correlation in the "6q duplication syndrome".

ACKNOWLEDGEMENTS

We thank the patient and her parents for their cooperation. M.P. is supported by a PhD fellowship from the French Ministry of Research.

REFERENCES

- Brøndum-Nielsen K, Bajalica S, Wulff K, Mikkelsen M. 1993. Chromosome painting using FISH (fluorescence in situ hybridization) with chromosome-6-specific library demonstrates the origin of a de novo 6q+ marker chromosome. *Clin Genet* 43:235-9.
- Burton EA, Tinsley JM, Holzfeind PJ, Rodrigues NR, Davies KE. 1999. A second promoter provides an alternative target for therapeutic up-regulation of utrophin in Duchenne muscular dystrophy. *Proc Natl Acad Sci U S A* 96:14025-30.
- Cappon SL, Duncan AM, Khalifa MM. 2000. Interstitial 6q duplication in an adult male without growth delay or severe mental retardation. *Med Sci Monit* 6:581-5.
- Causio F, Fischetto R, Carnevale F, Pansini A, Rocchi M. 2001. Trisomy 6q syndrome: a case with a de novo 6q23 tandem duplication. *Genet Couns* 12:145-50.

- Dallapiccola B, Bricarelli FD, Quartino AR, Mazzilli MC, Chisci R, Gandini E. 1978. Delineation of syndromes due to partial 6q imbalances. Trisomy 6q21 leads to qter and monosomy 6q221 leads to qter in two unrelated patients. *Acta Genet Med Gemellol (Roma)* 27:57-66.
- Deconinck AE, Rafael JA, Skinner JA, Brown SC, Potter AC, Metzinger L, Watt DJ, Dickson JG, Tinsley JM, Davies KE. 1997. Utrophin-dystrophin-deficient mice as a model for Duchenne muscular dystrophy. *Cell* 90:717-27.
- Ferraguti F, Crepaldi L, Nicoletti F. 2008. Metabotropic glutamate 1 receptor: current concepts and perspectives. *Pharmacol Rev* 60:536-81.
- Grati FR, Lalatta F, Turolla L, Cavallari U, Gentilin B, Rossella F, Cetin I, Antonazzo P, Bellotti M, Dulcetti F, Baldo D, Tenconi R, Simoni G, Miozzo M. 2005. Three cases with de novo 6q imbalance and variable prenatal phenotype. *Am J Med Genet A* 136:254-8.
- Gros-Louis F, Dupre N, Dion P, Fox MA, Laurent S, Verreault S, Sanes JR, Bouchard JP, Rouleau GA. 2007. Mutations in SYNE1 lead to a newly discovered form of autosomal recessive cerebellar ataxia. *Nat Genet* 39:80-5.
- Guillaud-Bataille M, Valent A, Soularue P, Perot C, Inda MM, Receveur A, Smaili S, Roest Crollius H, Benard J, Bernheim A, Gidrol X, Danglot G. 2004. Detecting single DNA copy number variations in complex genomes using one nanogram of starting DNA and BAC-array CGH. *Nucleic Acids Res* 32:e112.
- Haenggi T, Fritschy JM. 2006. Role of dystrophin and utrophin for assembly and function of the dystrophin glycoprotein complex in non-muscle tissue. *Cell Mol Life Sci* 63:1614-31.
- Hellemans J, Mortier G, De Paepe A, Speleman F, Vandesompele J. 2007. qBase relative quantification framework and software for management and automated analysis of real-time quantitative PCR data. *Genome Biol* 8:R19.
- Henegariu O, Heerema NA, Vance GH. 1997. Mild "duplication 6q syndrome": a case with partial trisomy (6)(q23.3q25.3). *Am J Med Genet* 68:450-4.
- Herrington DM, Howard TD, Hawkins GA, Reboussin DM, Xu J, Zheng SL, Brosnihan KB, Meyers DA, Bleecker ER. 2002. Estrogen-receptor polymorphisms and effects of estrogen replacement on high-density lipoprotein cholesterol in women with coronary disease. *N Engl J Med* 346:967-74.
- Minassian BA, Lee JR, Herbrick JA, Huizenga J, Soder S, Mungall AJ, Dunham I, Gardner R, Fong CY, Carpenter S, Jardim L, Satishchandra P, Andermann E, Snead OC, 3rd, Lopes-Cendes I, Tsui LC, Delgado-Escueta AV, Rouleau GA, Scherer SW. 1998. Mutations in a gene encoding a novel protein tyrosine phosphatase cause progressive myoclonus epilepsy. *Nat Genet* 20:171-4.
- Moreno JC, Klootwijk W, van Toor H, Pinto G, D'Alessandro M, Leger A, Goudie D, Polak M, Gruters A, Visser TJ. 2008. Mutations in the iodotyrosine deiodinase gene and hypothyroidism. *N Engl J Med* 358:1811-8.
- Motazacker MM, Rost BR, Hucho T, Garshasbi M, Kahrizi K, Ullmann R, Abedini SS, Nieh SE, Amini SH, Goswami C, Tzschach A, Jensen LR, Schmitz D, Ropers HH, Najmabadi H, Kuss AW. 2007. A defect in the ionotropic glutamate receptor 6 gene (GRIK2) is associated with autosomal recessive mental retardation. *Am J Hum Genet* 81:792-8.
- Ohta T, Tohma T, Soejima H, Fukushima Y, Nagai T, Yoshiura K, Jinno Y, Niikawa N. 1993. The origin of cytologically unidentifiable chromosome abnormalities: six cases ascertained by targeted chromosome-band painting. *Hum Genet* 92:1-5.
- Pazooki M, Lebbar A, Roubergues A, Baverel F, Letessier D, Dupont JM. 2007. Pure familial 6q21q22.1 duplication in two generations. *Eur J Med Genet* 50:60-5.
- Perkins KJ, Davies KE. 2002. The role of utrophin in the potential therapy of Duchenne muscular dystrophy. *Neuromuscul Disord* 12 Suppl 1:S78-89.
- Pivnick EK, Qumsiyeh MB, Tharapel AT, Summitt JB, Wilroy RS. 1990. Partial duplication of the long arm of chromosome 6: a clinically recognizable syndrome. *J Med Genet* 27:523-6.
- Pratt VM, Roberson JR, Weiss L, Van Dyke DL. 1998. Duplication 6q21q23 in two unrelated patients. *Am J Med Genet* 80:112-4.
- Rafael JA, Brown SC. 2000. Dystrophin and utrophin: genetic analyses of their role in skeletal muscle. *Microsc Res Tech* 48:155-66.
- Rafael JA, Trickett JI, Potter AC, Davies KE. 1999. Dystrophin and utrophin do not play crucial roles in nonmuscle tissues in mice. *Muscle Nerve* 22:517-9.

- Tipton RE, Berns JS, Johnson WE, Wilroy RS, Jr., Summitt RL. 1979. Duplication 6q syndrome. *Am J Med Genet* 3:325-30.
- Turleau C, de Grouchy J. 1981. Trisomy 6qter. *Clin Genet* 19:202-6.
- Uhrich S, FitzSimmons J, Easterling TR, Mack L, Disteché CM. 1991. Duplication (6q) syndrome diagnosed in utero. *Am J Med Genet* 41:282-3.
- Zneimer SM, Ziel B, Bachman R. 1998. Partial trisomy of chromosome 6q: an interstitial duplication of the long arm. *Am J Med Genet* 80:133-5.
- Zweier C, Trautmann U, Ekici A, Rauch A. 2008. A 15Mb duplication of 6q24.1-q25.3 associated with typical but milder features of the duplication 6q syndrome. *Eur J Med Genet* 51:358-61.

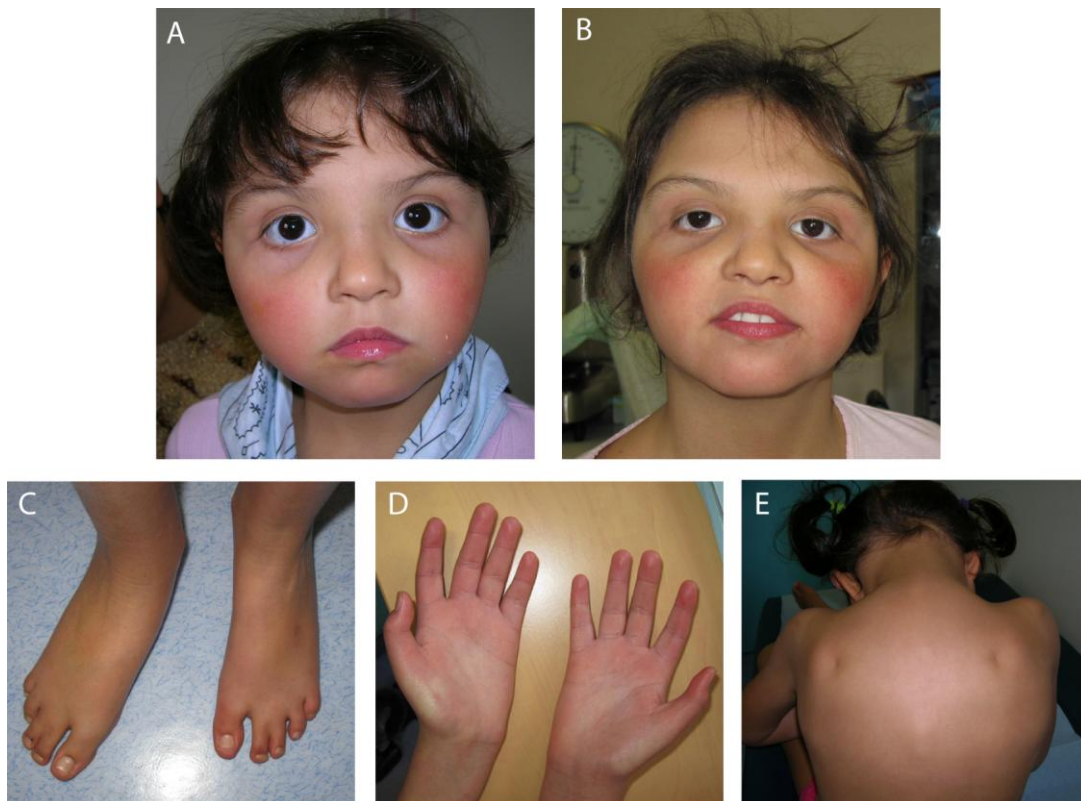

Figure 1. A,B. Photos of the patient at 4 years 11 months and 7 years 10 months showing hypertelorism, horizontal eyebrows, midface hypoplasia with relative exophthalmia, small tented upper lip, and microretrognathia. C,D. Bilateral syndactyly of the 2nd and 3rd toes, long palms of feet and hands compared to length of toes/fingers. E. Backside dimples.

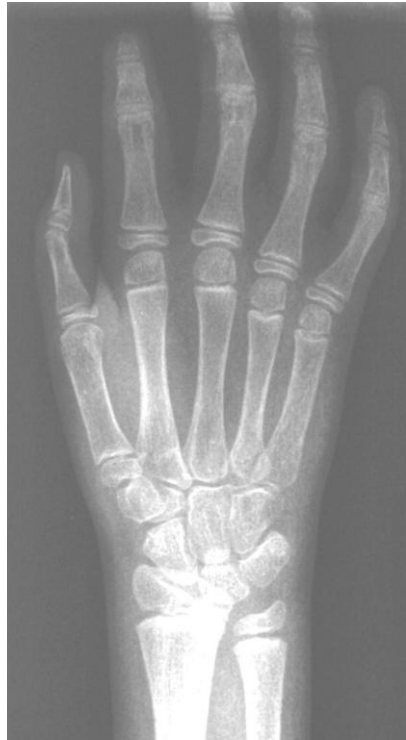

Figure 2. Hand X-ray showing elongated and tubular-shaped metacarpal and phalanges, and disproportionately long first metacarpal and proximal phalanges compared to the second and third. Note joint stiffness preventing normal extension of fingers.

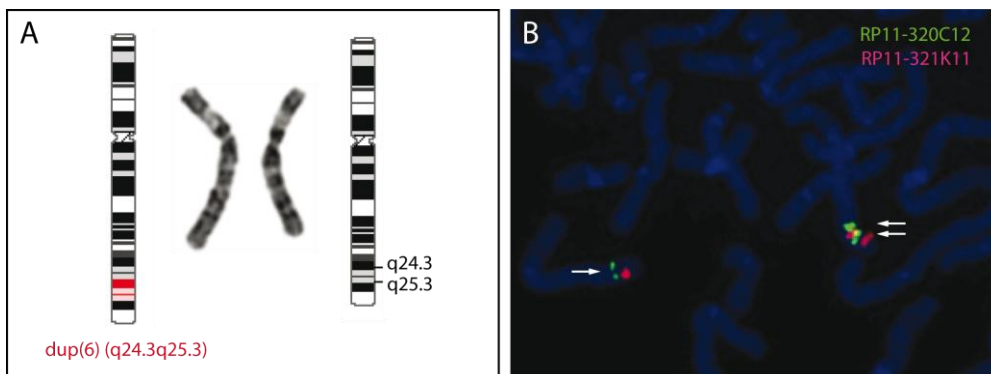


Figure 3. A. Partial high resolution karyotype, GTG banding showing the interstitial duplication: dup(6)(?q24.3q25.3). **B.** Tandem duplication of the 6q24.2q25.3 region (two arrows) compared to the normal chromosome 6 (single arrow). RP11-320C12 (green) maps to 6q24.3 and RP11-321K11 (red) maps to 6q25.2, demonstrating that the two copies are adjacent and oriented in the same sense.

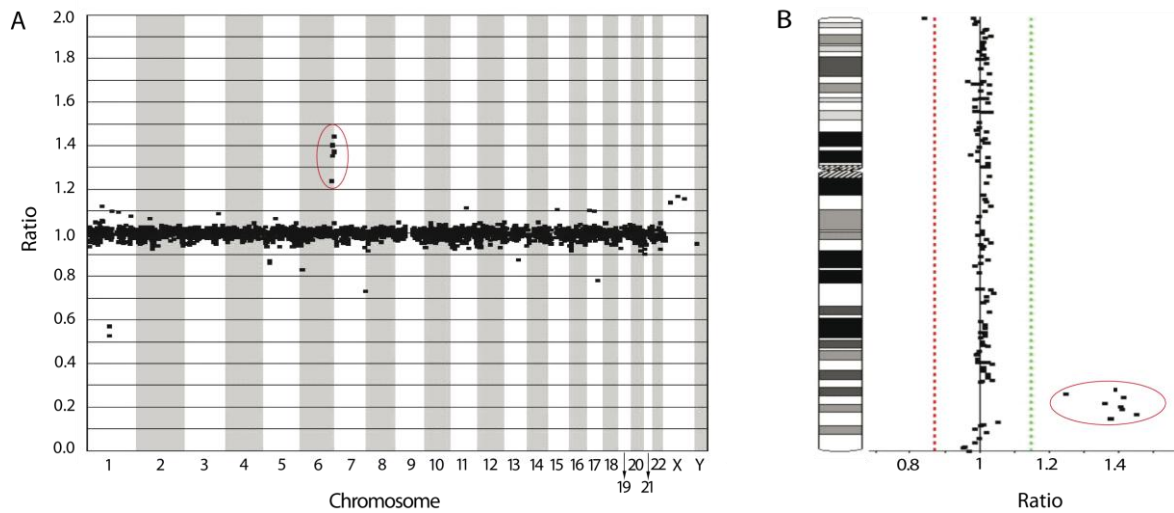


Figure 4. **A.** Global analysis of the genome with array-CGH showing an excess of material on chromosome 6. **B.** Partial array-GCH results for chromosome 6 showing the duplication of eight adjacent clones in the 6q24.3q25.3 region.

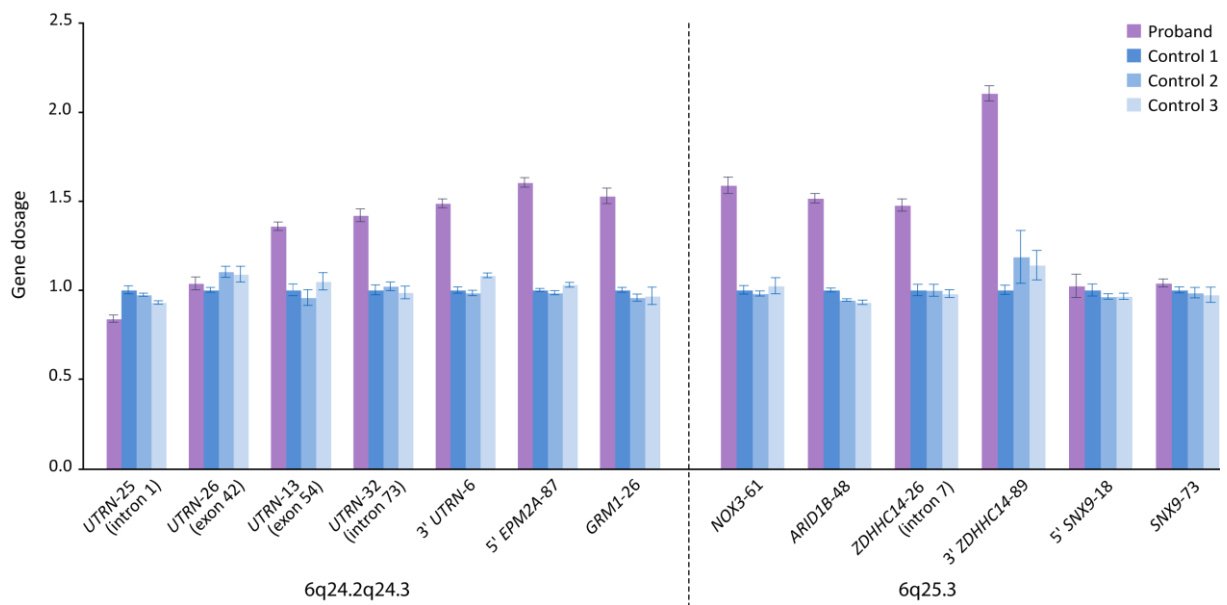


Figure 5. Quantitative PCR probes were designed to detect copy number changes in the 6q24q25 region in the patient (violet) and three controls (blue). The names of the genes are followed by the number of the UPL probe used. A gene dosage ratio of 1 indicates the presence of 2 alleles and is considered normal; values above 1.5 correspond to a duplication (3 alleles). Data represent mean \pm SD. The centromeric breakpoint of the duplication lies within the gene *UTRN*, between exon 42 and exon 54; the distal breakpoint is located between *ZDHHC14* and *SNX9*.

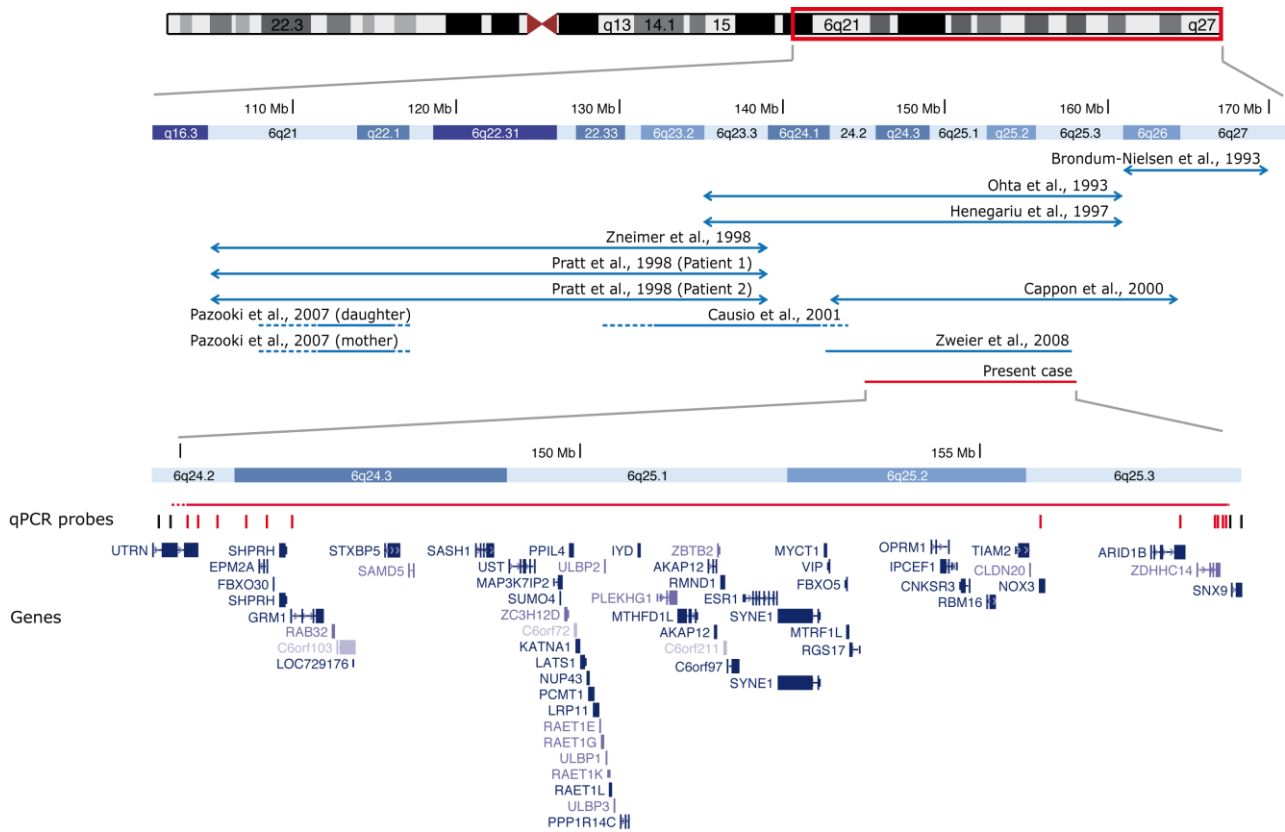


Figure 6. Map of chromosome 6 showing the 6q24.2q25.3 duplication in our patient (red) and 11 other pure 6q duplications (blue). The approximate location of the previously described duplications characterized only by cytogenetic banding is represented by arrows, those mapped with FISH are represented by full lines with approximate location of breakpoints depicted as dotted lines, and one duplication mapped with SNP array is represented as a full line. The 13 Mb duplication in the present case contains 57 RefSeq genes, with the proximal breakpoint in the *UTRN* gene and the distal breakpoint between *ZDHHC14* and *SNX9* (dotted line). The position of qPCR probes is shown by vertical bars; black bars represent a normal copy number while red bars indicate a duplication.