

**ENHANCED SURVIVAL AND CURE OF F98 GLIOMA BEARING RATS
FOLLOWING INTRACEREBRAL DELIVERY OF CARBOPLATIN IN
COMBINATION WITH PHOTON IRRADIATION.**

Authors: Julia Rousseau^{1,2,3}, Caroline Boudou^{1,2,3}, Rolf F. Barth⁴, Jacques Balosso^{1,2,3,5},
François Estève^{1,2,3,5} and H  l  ne Elleaume^{1,2,3,5}.

¹ INSERM U836, Equipe 6, Grenoble, France;

² Universit   Joseph Fourier, Grenoble, France;

³ European Synchrotron Radiation Facility, Medical Beamline ID17, Grenoble, France;

⁴ Department of Pathology, The Ohio State University, Columbus, OH 43210;

⁵ Centre Hospitalier Universitaire, Grenoble, France;

Corresponding Author:

H  l  ne Elleaume, Ph.D., INSERM Unit   836, ESRF, Medical Beamline, BP 220, 38043
Grenoble Cedex 9, France. Tel: (+33) 4-7688-2343; Fax: (+33) 4-7688-2885;

E-mail: h.elleaume@esrf.fr

Keywords: F98 rat glioma, carboplatin, convection-enhanced delivery, radiotherapy.

Short title: Carboplatin CED and photon irradiation against glioma.

Acknowledgments. We are indebted to the European Synchrotron Radiation Facility medical beamline for providing the necessary beam time and technical assistance in all the steps of the experimental studies. We thank Dr. Melvin Moeschberger and Mr. Kevin Tordoff for assistance with statistical evaluation of the data. Special thanks to Dr. Stéphanie Corde, Mrs. Géraldine Michel-Amadry, Mrs. Catherine Massart, Mr. Thierry Brochard, Dr. Christian Nemoz for their help during the experiments, to Mr. Dominique Dallery for animal care and to Dr. Dominique Charlety (Grenoble university hospital pharmacy) for providing carboplatin.

Conflicts of interest notification. there are no conflicts of interest.

Abstract

Purpose: The goal of the present study was to evaluate the efficacy of intracerebral (i.c.) administration of carboplatin by means of convection-enhanced delivery (CED) in combination with fractionated, external beam photon irradiation for the treatment of F98 glioma-bearing rats.

Experimental Design: Carboplatin (20 µg/20 µl) was administered i.c. by CED to F98 glioma-bearing rats, thirteen days following stereotactic implantation of 10^3 tumor cells. One day following initiation of CED a 24 Gy X-ray dose was administered in 3 daily fractions of 8 Gy each. Photon irradiation was carried out using either a conventional (6 MV) linear accelerator (LINAC) or a (80 keV) monochromatic synchrotron source at the European Synchrotron Radiation Facility (ESRF). The primary endpoint of this study was overall survival.

Results: The median survival times were 79 days and 60 days and the corresponding percent increase in life spans were 182% and 114%, respectively, for the combination of carboplatin chemotherapy and irradiation with either 6 MV or 80 keV photons. A subset of long-term survivors (>200 days) were observed in both chemo-radiotherapy groups: 16.6% and 8.3% for 6 MV and 80 keV, respectively. In contrast, the median survival times for 6 MV or 80 keV irradiated controls, chemotherapy alone, and untreated controls, were 42, 51, 45 and 28 days, respectively.

Conclusions: Our results convincingly demonstrate the therapeutic efficacy of i.c. administration of carboplatin by means of CED in combination with either 6 MV or 80 keV photons. Further studies are warranted to optimize this combination of chemo-radiotherapy for malignant gliomas.

Introduction

Up until recently, the overall median survival of patients with high-grade gliomas usually has been less than one year after diagnosis (1, 2). Standard treatment consists of surgical resection of the tumor followed by radiation and chemotherapy. Although such treatment has generally increased lifespan by several months, the tumor inevitably recurs (3, 4) and long-term survivors are extremely rare. Recently, however, Stupp *et al.* (5) have reported that the combination of temozolomide and radiotherapy, followed by temozolomide alone, significantly prolonged the overall median lifespan of glioblastoma patients by two months. Although small, this was highly significant ($p < 0.001$) and the percent patients surviving at 30 months was approximately 25% compared to 5% for patients who had not received temozolomide (5). This major advance has set a new standard for the treatment of patients with glioblastoma multiforms (GBM), against which other therapeutic approaches will now be measured. Among all chemotherapeutic agents available, platinum-derived drugs have played an important role in the treatment of solid tumors (6, 7) but their systemic administration has been limited by their toxicity. Carboplatin is a cisplatin analogue, which produces fewer side effects than cisplatin, but has a similar range of clinical activity (8). Hongo *et al.* have shown that carboplatin induces the same platinum-DNA adducts as cisplatin, although *in vitro* it requires a 10-fold higher drug concentration and a 7.5-fold longer incubation time to produce an equivalent effect (8, 9).

The clinical effectiveness of carboplatin for the treatment of brain tumors is limited by the blood-brain barrier (BBB), which effectively reduces its uptake following systemic administration (10). Although the BBB may be partially disrupted in some regions of the brain tumor, it is largely intact in more distant areas, thereby reducing the chemotherapeutic effectiveness in the surrounding in which there are infiltrating tumor cells. Strategies have been developed to improve drug delivery, such as the disruption of the BBB or local

administration of drug within the central nervous system (CNS) by the mean of implantable pumps, biodegradable polymers and convection-enhanced delivery (CED). CED has been used to enhance the distribution of drugs to brain tumors in an homogeneous and targeted manner (10-23). Its advantages over diffusion-dependent methods include greater volumes of distribution, more uniform drug concentrations within the treatment volume, and relative independence from molecular weight. It has been used experimentally by one of us (R.F.B.) to enhance the delivery of boronated anti-EGF monoclonal antibodies for boron neutron capture therapy (BNCT) (24, 25).

Recently, we reported on the efficacy of synchrotron stereotactic radiotherapy (SSR) in combination with direct intratumoral (i.t.) injection of cisplatin (3 $\mu\text{g}/5 \mu\text{l}$ of CDDP) for the treatment of F98 glioma-bearing rats. This combined modality treatment resulted in survival times greater than 1 year in Fischer rats bearing F98 gliomas (26). Our initial hypothesis was that therapeutic efficacy was related to the production of Auger electrons and photoelectrons following irradiation of platinum atoms with beams of monochromatic X-rays tuned just above the Pt K-edge energy (Pt K-edge: 78.4 keV). Above this energy, extraction of electrons from the K-shell by the photoelectric effect results in the creation of K-shell vacancies. After removal of inner-shell electrons, the resulting vacancies are successively filled up by radiative and non-radiative transitions from outer-shell electrons whereby several low energy photons and electrons are released. These emitted electrons have short pathlengths in tissue, thereby producing high local energy deposition on a nanometer scale (27). The photoelectric cross-section of Pt is 4.8 times greater at 78.8 keV compared with 78.0 keV (2860 and 593 barns/atom, respectively). Therefore, *if* the treatment efficacy were related to Auger electron emissions, a therapeutic gain should be obtained with an irradiation above the Pt K-edge, compared to irradiation with X-rays below the Pt K-edge.

This enhancement was indeed observed *in vitro* at the molecular level. A larger number

of double-strand breaks (DSBs) was measured when tumor cells were pre-treated with cisplatin (CDDP) and subsequently irradiated above the Pt K-edge, compared to irradiation below the K-edge. Three times more DSBs were measured with human SQ20B carcinoma cells pre-treated with 30 μM CDDP for 6 hours (3×10^8 atoms of platinum per cell) (28) and 1.5 times more DSBs using F98 glioma cells (26). However, such an enhancement was not obtained *in vitro*, when the cells were pretreated with 3 μM CDDP for 6 hours, a treatment compatible with cell survival (cells survival rate 25%; 4×10^6 atoms of Pt per cell) (28, 29). *In vivo*, the combined intratumoral (i.t.) administration of CDDP (3 μg in 5 μl), followed 24 hours later by 15 Gy irradiation, resulted in enhanced survival of F98 glioma-bearing rats, irrespective of whether the irradiation was performed below or above the Pt K-edge (33 % cure rate, in both groups) (26).

Taken together, these findings suggested that therapeutic efficacy was *not* related to the emission of Auger electrons from the Pt atoms, when it was incorporated into tumor cells at therapeutic levels. This led us to postulate that the Pt-based chemo-radiotherapy also could be carried out using high energy X-rays from a linear accelerator (LINAC). We hypothesized that local administration of carboplatin by CED in combination with external photon radiation therapy could improve the survival of F98 glioma-bearing rats. In the present study, we first evaluated the toxicity and efficiency of intracerebral (i.c.) delivery of carboplatin by CED in syngeneic Fischer rats bearing F98 gliomas at varying carboplatin concentrations and dosing schedules. Based on these data, we then evaluated the efficacy of carboplatin, administered by CED, followed by fractionated radiation therapy using either 6 MV photons produced by a LINAC or SSR using monochromatic 80 keV X-rays. Our data demonstrate the efficacy of this chemo-radiotherapeutic approach using both radiation modalities, and considerably broadens the clinical applicability of this approach since LINACs are widely available in hospitals.

Materials and Methods

F98 glioma model. Following i.c. implantation into syngeneic Fischer rats, the F98 glioma forms a progressively growing, infiltrative tumor with characteristics similar to those of human high-grade gliomas, including a lack of response to a variety of therapeutic modalities (30, 31). Up until recently, the best survival data with this tumor model have been obtained using either boron neutron capture therapy (BNCT) (32), or more recently, SSR in combination with direct i.t. injection of CDDP (26).

Tumor implantation. All operative procedures and animal care were carried out in conformity with the guidelines of the French Government (decree 87-848 of October the 19th 1987, license 7593 and A38071) and in accordance with the Laboratory Animal Care and Use Committee of the European Synchrotron Radiation Facility (ESRF). F98 glioma cells were routinely cultured as monolayers in Dulbecco's Modified Eagle's Medium (DMEM) (Gibco-Invitrogen-France, Cergy-Pontoise, France), supplemented with 10% fetal calf serum (FCS), penicillin, and streptomycin. Male Fischer 344 rats (Charles River Laboratories, L'Abresles, France), weighing 230-260g, were anesthetized with an isoflurane inhalational technique followed by an intraperitoneal (i.p.) injection of a mixture of ketamine (64.5 mg/kg of body weight [b.w.]) and xylazine (5.4 mg/kg of b.w.) Additional i.p. injections of ketamine and xylazine were administrated as needed to maintain anesthesia throughout the surgical procedures. The animals' eyes were lubricated with an ocular lubricant. For therapy experiments, 10^3 F98 cells in 5 μ l of serum-free DMEM were implanted i.c. into the right caudate nucleus (3.5 mm right to the bregma and 5.5 mm in depth). The syringe pump (model KDS 310, GENEQ inc., Montréal, Québec, Canada; infusion rate 2.5 μ l/min) was directly mounted on the stereotactic frame (David Kopf Instruments, Tujunga, CA) and the syringe (model 701 N, Hamilton, Bonaduz, Switzerland) was attached to the pump. Prior to infusion

using the same stereotactic coordinates, a 26s-gauge needle was inserted to a depth of 6 mm and then withdrawn to a target depth of 5.5 mm from the skull surface. Upon completion of the infusion, the needle was left in place for two minutes and withdrawn slowly. The hole in the calvarium then was filled with bone wax and the operative field was cleaned with betadine before closure of the scalp incision.

Chemotherapeutic drug delivery by CED. Carboplatin was kindly supplied by the Grenoble University Hospital Pharmacy (M.W. 371.25; Carboplatine Faulding 10 mg/ml, Pharmaceuticals S.A. Asnières, France). The carboplatin solution was diluted in isotonic NaCl solution to obtain the required concentrations for i.c. infusion. Thirteen days following tumor implantation, the rats were anesthetized as previously described. Carboplatin was administered by means of CED, using a syringe pump (model KDS 310, GENEQ inc., Montréal, Québec, Canada) at a rate of 0.5 $\mu\text{L}/\text{min}$ (17). A 32-gauge needle attached to a 50 μl syringe (model 1700, gastight, Hamilton) was placed in the tumor bed by using the same coordinates as those used for tumor implantation.

Chemotherapy studies. To evaluate toxicity and/or efficacy of i.c. delivery of carboplatin in F98 glioma-bearing rats, two experiments were performed. In the first, 6 to 10 animals per group received carboplatin by CED, at day 13 after tumor inoculation. Animals were stratified as follows: Group 1: untreated controls (n = 7); Group 2: 20 μg in 20 μl (n = 10); Group 3: 40 μg in 40 μl (n = 7); Group 4: 100 μg in 20 μl (n = 6). Animals were weighed and monitored clinically. In a second study, the influence of the chemotherapy schedule relative to the time of tumor implantation was investigated. Another group of animals (Group 5, n = 8) received carboplatin (dose: 40 μg in 40 μl) on day 8 after tumor implantation and this was compared to the same treatment delivered on day 13 (Group 3). The side effects of carboplatin infusion were evaluated by determining loss of body weight and clinical status.

Mean and median survival times were the endpoint of these studies.

Fractionated irradiations. SSR at 80 keV was carried out at the ESRF Medical Beamline and 6 MV irradiation was performed at the Grenoble University Hospital. The X-ray dose was delivered over 3 days, with the first fraction given on day 14 after tumor implantation. In our previous studies (26, 33), the X-ray dose was delivered on day 14 in a single-fraction of 15 Gy at the tumor. The biologically equivalent dose-fraction (BED) in a three-fraction regimen was calculated using the classic linear quadratic (LQ) equation (34, 35):

$$\text{BED} = nd \left(1 + \frac{d}{\alpha/\beta} \right), \quad \text{Equation 1}$$

where, n is the number of fractions, d is the dose per fraction in Gy, α and β are two parameters that indicate the sensitivity of tumor or normal tissue to changes in dose fractionation. The α/β ratio is usually taken to be 10 for tumor and early reacting tissues, and 3 for late reacting tissues like brain. The biologically effective dose (BED) for 15 Gy, delivered in a single fraction, using the α/β ratios indicated above, was 37.5 Gy in acute and tumor effects, and 90 Gy in late effects (36). To obtain the same BED for tumor and early reacting tissues, in a three-fraction regimen, the fraction-size was determined by solving equation 1 using a BED=37.5 Gy and $\alpha/\beta=10$, which gave $d = 7.3$ Gy. Using the same equation for normal brain and late responding tissues (BED = 90 Gy and $\alpha/\beta=3$), the fraction-size d was 8.1 Gy, given in three fractions. Based on these evaluations, we chose to deliver the radiation dose in 3 fractions with 8 Gy per fraction to be biologically comparable to a single 15 Gy fraction previously used in our preclinical studies (26, 33).

Stereotactic Synchrotron Radiation. Anesthetized animals were irradiated as previously described (26, 33). Briefly, the irradiations were performed with monochromatic X-rays from the ESRF ID17 beamline (37). The radiation beam energy was tuned at 80 keV (80 eV

energy bandwidth). The right hemisphere was centred on the rotation axis of the irradiation system and the beam was shaped by tungsten slits to 10 mm in width and 1 mm in height. The dose was delivered while the rat was being rotated, and translating upwards between each of the thirteen adjacent 360° arcs so that the irradiated target volume encompassed a 10 mm in diameter and 13 mm in height cylinder. A GafChromic film (MD-55, International Specialty Products, Wayne, NJ) was exposed during the rats' irradiation for checking the irradiation homogeneity. The X-ray dose rate was determined using an ion chamber (PTW Unidos, PTW, Freiburg, Germany) and a high purity germanium detector (Eurysis, Lingolsheim, France). The dose rate at the tumor was 0.27 Gy/s. The dose distributions were determined using Monte Carlo simulations (38) with rat head CT images, the X-ray dose rate and the beam geometry as input parameters.

LINAC irradiation. Irradiations were performed using a 6 MV medical irradiator (SLI, Elekta, Crawley, UK). Rats were irradiated, two at a time, in a polystyrene box. The head of each animal was aligned in the middle of an 8×4 cm² aperture, defined by the beam collimator. Only the right cerebral hemisphere was irradiated. A wax block was positioned between the rats' heads and a 0.5 cm tissue equivalent bolus was placed on top to ensure electronic equilibrium. The dose of 8 Gy was prescribed at a 1.5 cm depth at a dose rate of 200 cGy/min (dosimetry treatment planning system: Dosigray, DosiSoft, Cachan, France). After treatment was completed, the animals were transferred to the Animal Care Facility at the ESRF.

Chemo-radiotherapy experimental groups. Chemotherapy was initiated 13 days following stereotactic implantation of 10³ F98 glioma cells and X-ray irradiations were started 24 hours later. The animals were randomized into 6 experimental groups of 6 to 12 animals each. For those experiments carried out at the University Hospital (6 MV LINAC irradiation), the

groups were stratified as follows: Group 6: untreated controls (n = 9); Group 2: chemotherapy controls, which received carboplatin (20 µg in 20 µl by CED) (n = 10); Group 7: irradiated controls at 6 MV (n = 11); Group 8: carboplatin (20 µg in 20 µl administered by CED), followed by three 8 Gy fractions (6 MV) administered over three days (n = 12). For those experiments carried out at the ESRF (80 keV), the groups were stratified as follows: Group 9: untreated controls (n = 6); Group 10: irradiated controls at 80 keV (n = 11); Group 11: carboplatin (20 µg in 20 µl administered by CED), followed by three 8 Gy fractions at 80 keV over three days (n = 12).

Monitoring of clinical status and neuropathologic evaluation. After therapy, the animals were weighed three times per week and their clinical status was monitored. The combination of sustained weight loss, ataxia and peri-orbital hemorrhage has been shown to be indicative of progressively growing tumors (39). In such cases, the animals were euthanized by an intracardiac injection of Dolethal (150 mg/kg; Vetoquinol, Lure, France) and survival times were determined by adding 1 day to the time between tumor implantation and euthanasia. The long-term survivors were defined as rats living more than 200 days and the surviving animals were euthanized at this time point. Following euthanization, the brains of selected animals in the therapy studies were removed, fixed in 10% buffered formalin, and then cut coronally at the level of the optic chiasm and 2 mm anterior and posterior to it. Coronal slices were embedded in paraffin, cut at 4 µm, stained with hematoxylin and eosin (H&E), and then examined microscopically to assess histopathologic changes.

Statistical evaluation of survival data. Kaplan-Meier survival curves were plotted for each group. Differences between various treatment groups were assessed for statistical significance by means of the log-rank test (JMP[®], SAS Institute Inc., Cary, NC). Those rats still alive at 200 days after tumor cell implantation were euthanized. Minimal statistical

significance was defined at p value < 0.05. The mean survival time (MST), standard error (SE), and median survival time (MeST) were calculated with a value of 200 days for the rats still alive at the end of the study. When the last observations in each group are the only ones censored, then the estimate of the mean is approximately the arithmetic mean of the survival times with the last censoring observations included in the mean (40). Percentage of increased life span (%ILS) was determined relative to MST or MeST of untreated controls as:

$$\%ILS = \frac{MST - MST_{Control}}{MST_{Control}} \times 100$$

Results

Chemotherapy study in rats bearing glioma. All animals that received i.t. carboplatin by CED lost weight within 7 days after treatment. Three out of seven rats that received 40µg/40µl carboplatin by CED at day 13 lost more than 10 % of their b.w. (Table 1), and one rat in that group died early on day 16 (Fig. 1 and Table 2). One early death (day 16) also was observed in chemotherapy Group 4 that received 100 µg/20 µl of carboplatin at day 13. Conversely, the weight lost was mild (<10% of b.w.) in the Group 2, which received 20 µg/20 µl on day 13. The survival of rats in this group was significantly different from the untreated controls group (p < 0.0001). The log-rank test was not used for the other groups, since the survival plots crossed each other due to early deaths. In such cases the log-rank test is unlikely to detect differences between groups (40). In the second pilot study, 7 of 8 rats that received chemotherapy 8 days after tumor implantation had a small loss in weight (<5%), and no early deaths. It is noteworthy that one rat was still alive at the end of the study (200 days).

Therapeutic response following chemo-radiotherapy. For the chemo-radiotherapy study,

20 µg/20 µl carboplatin was administered by CED at a rate of 0.5 µl/min, 13 days after implantation of 10^3 F98 tumor cells, and radiotherapy was initiated 24 h later. Survival data are summarized in Table 3 and Kaplan-Meier survival plots are shown in Figure 2. The untreated rats had a median survival time (MeST) of 28 days, and a mean survival (MST) of 28 ± 1 days (range 26-32 days) compared to a MeST of 51 days and MST of 52 ± 2 days (range 42-65 days), for the irradiated controls at 80 keV ($p < 0.0001$). Similarly, the 6 MV, photon irradiated controls had a modest increase in MeST to 42 days and MST of 43 ± 2 days (range 35-56 days), compared to a MeST of 28 days and a MST of 29 ± 1 days for the untreated rats ($p < 0.0001$). Animals bearing F98 gliomas, which had received carboplatin (dose = 20 µg/20 µl) by CED had a MeST of 45 days and MST of 55 ± 8 days with one rat surviving 120 days, which was significantly different from the untreated control group ($p < 0.0001$). The corresponding %ILS relative to the median were 63 %, 82 % and 50 % for chemotherapy alone, and irradiation alone at 80 keV, or 6 MV, respectively. The combination of carboplatin and irradiation resulted in the greatest prolongation in survival time. Animals that received chemotherapy followed by SSR at 80 keV had a MeST of 60 days and a MST of 81 ± 16 days (biased, range 47-200⁺ days). Animals that received chemotherapy, followed by irradiation with 6 MV photons, had a MeST of 79 days and a MST of 97 ± 15 days (biased, range 50-200⁺ days). Most significantly, there was a cure rate of 16.6% for animals that received carboplatin followed by fractionated, 6 MV photon irradiation, with a 182% ILS of the MeST compared to that of untreated controls. There were also long-term survivors and/or cured animals in the chemo-radiotherapy group irradiated at 80 keV. One rat was still alive at 200 days and another died on day 198. Survival of the animals that received chemo-radiotherapy was significantly different from the irradiated controls that received either 6 MV ($p < 0.0001$) or 80 keV photons ($p = 0.041$). Although the mean and median survival times of the chemo-radiotherapy groups were greater than the chemotherapy alone group, the

differences were statistically significant only for chemo-radiotherapy group irradiated with 6 MV photons ($p = 0.004$) and not with 80 keV X-rays ($p = 0.176$). Most importantly, the survival times of the two chemo-radiotherapy groups (6 MV and 80 keV X-rays) were not significantly different from one another ($p = 0.173$).

Histopathologic studies. Microscope examination of the brains of three rats that had received carboplatin and 6 MV photons (2 rats) or 80 keV (1 rat) and that were euthanized at day 200, showed no evidence of tumor. One animal that had received 80 keV X-rays and died at day 198 also had no evidence of residual tumor. The brains of two animals that received carboplatin alone were examined. One, which received 100 $\mu\text{g}/20 \mu\text{l}$ on day 13 after tumor implantation and died on day 16, showed a small focus of necrotic tumor cells, rarefaction of white matter and microfoci of haemorrhage. These findings suggest that this was a therapy-related death. The other one, which received 40 $\mu\text{g}/40 \mu\text{l}$ on day 8 after tumor implantation, was still alive at termination of the study (day 200) and showed no evidence of tumor.

Discussion

The major finding in the present study was that carboplatin, administered by CED in combination with external beam X-irradiation, resulted in a significant enhancement in mean survival time, and cure of a subset of F98 glioma-bearing rats, *independently* of the X-ray beam energy. Rats that received chemotherapy, followed by 6 MV X-irradiation, had a MeST of 79 days, a corresponding %ILS of 182% (MeST), and a cure rate of 16.6% at 200 days. The chemo-radiotherapy group irradiated at 80 keV had a MeST of 60 days (114% ILS) with one long-term survivor (one rat died at day 198), and one cured animal (8.3%). Using the same experimental tumor model, one of us (RFB) has obtained a 25% cure rate following boron neutron capture therapy (BNCT) (32). In a previous study (26), we reported a 33 % cure rate of F98 glioma-bearing rats after i.t. injection of cisplatin (3 $\mu\text{g}/5\mu\text{l}$) in combination

with 15 Gy of synchrotron radiation. In that study, animals that received chemo-radiotherapy had a MeST of 214 and 194 days at 78.0 and 78.8 keV, respectively in the first experiment; and 131 and 91 days in the second, which was carried out 4 months later under the same conditions. The survival of the animals irradiated with an X-ray beam tuned above the Pt K-edge was not statistically different compared to irradiation below the K-edge. In both cases 33% of the treated rats were still alive one year later. In the same way, using non-toxic cisplatin concentrations, we have not observed any significant *in vitro* difference in the survival of SQ20B cells, when they were irradiated either above or below the Pt K-edge (29).

The results obtained in the present study confirm our initial findings, but suggest an alternative explanation relating to the role of DNA damage induced by atomic inner-shell relaxation, following a photoelectric event. If the efficacy of chemo-radiotherapy was primarily related to inner-shell ionizations of Pt atoms and subsequent Auger electrons cascades, synchrotron radiation, tuned above the Pt K-edge should have been much more effective than the same treatment with 6 MV photons from a linear accelerator. These results suggest that the therapeutic gain obtained with interstitial injection of platinum compounds followed by X-irradiation is *not* predominantly due to Auger electrons emitted from the Pt atoms, but rather involved other mechanisms (27). However, these findings do not refute the premise upon which SSR is based, namely the irradiation of high Z number atoms with energies at the energy of K-shell electrons.

Carboplatin, by itself, is an active cytoreductive chemotherapeutic agent (41). In the present study, animals that received carboplatin at a dose of 20 µg/20 µl had a MeST of 45 days (median %ILS =63%), and there was one long term survivor (120 days) with no early deaths. The highest doses of carboplatin tested (40 µg/40 µl and 100 µg/20 µl) were toxic, as evidenced by significant weight loss of F98 glioma-bearing rats within the first week after drug administration, which strongly suggests that this was drug-related. However, it is

noteworthy that one rat that received 40 µg/40 µl of carboplatin 8 days after tumor implantation was still alive at the end of the study (200 days). Intracerebral administration of carboplatin has been evaluated for the treatment of glioma-bearing rats in several other studies (10, 42-44). Degen and co-workers (10) have shown that carboplatin delivered by CED was effective in the treatment of 9L gliosarcoma-bearing rats. In their study, among the rats that received carboplatin (40 µg/40 µl) on day 7, 3 of 4 animals survived to 120 days at which time the study was terminated. There was one early death on day 19. In the same study, the toxicity of carboplatin, delivered by CED, into the striatum of non-tumor bearing rats was evaluated. Rats treated with the lowest doses of carboplatin (1 µg/10 µl or 10 µg/10 µl) did not exhibit any clinical signs or histological evidence of toxicity over a 3-day observation period. In contrast, four rats infused with the highest dose (100 µg/10 µl) died within the 3 days of infusion. Carboplatin has been shown to be less neurotoxic than other platinum-based compounds (41), when delivered directly into the CNS. Strege *et al.* (45) have investigated the neurotoxicity of carboplatin after chronic i.c. infusion into the monkey brainstem. Neurotoxicity was the most important side effect of i.c. infusion of carboplatin and doses exceeding 400 µg were neurotoxic in monkeys. Strege *et al.* concluded that the pharmacokinetics of local and systemic delivery were different for carboplatin. Based on our own data, we have concluded that further studies are required to evaluate the most effective platinum compound, to optimize its i.c. delivery with variable dosing schedules, and to carefully balance its tumoricidal activity and drug related neurotoxicity.

In conclusion, our data demonstrate the therapeutic efficacy of i.c. administration of carboplatin by means of CED in combination with fractionated radiotherapy in F98 glioma-bearing rats. Chemotherapy by itself improved the survival of F98 glioma-bearing rats, but this was enhanced by the addition of external beam photon irradiation. It remains to be determined if this effect was additive or synergistic. Our data show that high-energy X-ray

irradiation (6 MV) was as effective as synchrotron X-ray irradiation for the treatment of the F98 glioma. This significantly broadens the applicability of this chemotherapeutic approach for the treatment of patients with high-grade malignant brain tumors, since it could be more easily translated into a clinical trial using 6 MV photons instead of synchrotron derived X-rays.

Tables legend

Table 1: *Rat weight loss percentage, 7 days after chemotherapy treatment of F98 glioma.*

This table indicates the number of animal that died within 7 days after chemotherapy treatment, and the number of animals that lost weight, comparatively to their initial weight. The weight lost was classified in various ranges (<5%, 6-10% and 11-30%).

Table 2: *Survival times of F98 glioma-bearing rats after carboplatin chemotherapy.*

Carboplatin was delivered by CED on day 13 after tumor inoculation for groups 2, 3 and 4; and on day 8 for group 5. A survival time of 200 days was considered as the endpoint of the study. Rats still alive at 200 days after inoculation of 10^3 F98 glioma cells were euthanized.

Table 3: *Survival times of F98 glioma-bearing rats after chemo-radiotherapy.*

Carboplatin (20 μ g/20 μ l) was injected by CED on day 13 after tumor inoculation and was followed by radiotherapy (three fractions of 8 Gy), delivered on day 14, 15 and 16 after inoculation of 10^3 F98 glioma cells. A survival time of 200 days was considered as the endpoint of the study. Rats still alive at 200 days were euthanized.

Figures Legend

Figure 1: *Kaplan Meier survival plots for F98 glioma-bearing rats after carboplatin chemotherapy.*

Survival times in days after tumor implantation have been plotted for untreated animals (\diamond), CED of carboplatin 40 $\mu\text{g}/$ 40 μl delivered on day 13 after tumor implantation ($*$), or on day 8 after tumor implantation (\bullet), CED of carboplatin 20 $\mu\text{g}/$ 20 μl delivered on day 13 after tumor implantation (\square), CED of carboplatin 100 $\mu\text{g}/$ 20 μl delivered on day 13 after tumor implantation (\triangle). One animal that received carboplatin at a dose of 40 $\mu\text{g}/$ 40 μl , on day 8 after tumor implantation, was still alive at day 200.

Figure 2: *Kaplan Meier survival curves for F98 glioma-bearing rats after chemo-radiotherapy.*

Survival times in days after tumor implantation have been plotted for untreated animals (\diamond) and (l), CED of carboplatin 20 $\mu\text{g}/$ 20 μl alone (\square), irradiation at 6 MV alone (3 fractions of 8 Gy) (\circ), or in combination with CED of carboplatin 20 $\mu\text{g}/$ 20 μl (\bullet), irradiation at 80 keV alone (3 fractions of 8 Gy) (\times), or in combination with CED of carboplatin 20 $\mu\text{g}/$ 20 μl ($*$). Carboplatin was administered on day 13 and X-ray dose fractions were delivered on day 14, 15, 16 after tumor implantation.

References

1. Curran, W. J., Jr., Scott, C. B., Horton, J., Nelson, J. S., Weinstein, A. S., Fischbach, A. J., Chang, C. H., Rotman, M., Asbell, S. O., Krisch, R. E., and et al. Recursive partitioning analysis of prognostic factors in three Radiation Therapy Oncology Group malignant glioma trials. *J Natl Cancer Inst*, 85: 704-710, 1993.
2. Lacroix, M., Abi-Said, D., Fourney, D. R., Gokaslan, Z. L., Shi, W., DeMonte, F., Lang, F. F., McCutcheon, I. E., Hassenbusch, S. J., Holland, E., Hess, K., Michael, C., Miller, D., and Sawaya, R. A multivariate analysis of 416 patients with glioblastoma multiforme: prognosis, extent of resection, and survival. *J Neurosurg*, 95: 190-198, 2001.
3. Behin, A., Hoang-Xuan, K., Carpentier, A. F., and Delattre, J. Y. Primary brain tumours in adults. *Lancet*, 361: 323-331, 2003.
4. Bredel, M. Anticancer drug resistance in primary human brain tumors. *Brain Res Brain Res Rev*, 35: 161-204, 2001.
5. Stupp, R., Mason, W. P., van den Bent, M. J., Weller, M., Fisher, B., Taphoorn, M. J., Belanger, K., Brandes, A. A., Marosi, C., Bogdahn, U., Curschmann, J., Janzer, R. C., Ludwin, S. K., Gorlia, T., Allgeier, A., Lacombe, D., Cairncross, J. G., Eisenhauer, E., and Mirimanoff, R. O. Radiotherapy plus concomitant and adjuvant temozolomide for glioblastoma. *N Engl J Med*, 352: 987-996, 2005.
6. Wang, D. and Lippard, S. J. Cellular processing of platinum anticancer drugs. *Nat Rev Drug Discov*, 4: 307-320, 2005.
7. Go, R. S. and Adjei, A. A. Review of the comparative pharmacology and clinical activity of cisplatin and carboplatin. *J Clin Oncol*, 17: 409-422, 1999.
8. Knox, R. J., Friedlos, F., Lydall, D. A., and Roberts, J. J. Mechanism of cytotoxicity of anticancer platinum drugs: evidence that cis-diamminedichloroplatinum(II) and cis-

- diammine-(1,1-cyclobutanedicarboxylato)platinum(II) differ only in the kinetics of their interaction with DNA. *Cancer Res*, 46: 1972-1979, 1986.
9. Hongo, A., Seki, S., Akiyama, K., and Kudo, T. A comparison of in vitro platinum-DNA adduct formation between carboplatin and cisplatin. *Int J Biochem*, 26: 1009-1016, 1994.
 10. Degen, J. W., Walbridge, S., Vortmeyer, A. O., Oldfield, E. H., and Lonser, R. R. Safety and efficacy of convection-enhanced delivery of gemcitabine or carboplatin in a malignant glioma model in rats. *J Neurosurg*, 99: 893-898, 2003.
 11. Saito, R., Bringas, J. R., McKnight, T. R., Wendland, M. F., Mamot, C., Drummond, D. C., Kirpotin, D. B., Park, J. W., Berger, M. S., and Bankiewicz, K. S. Distribution of liposomes into brain and rat brain tumor models by convection-enhanced delivery monitored with magnetic resonance imaging. *Cancer Res*, 64: 2572-2579, 2004.
 12. Saito, R., Bringas, J. R., Panner, A., Tamas, M., Pieper, R. O., Berger, M. S., and Bankiewicz, K. S. Convection-enhanced delivery of tumor necrosis factor-related apoptosis-inducing ligand with systemic administration of temozolomide prolongs survival in an intracranial glioblastoma xenograft model. *Cancer Res*, 64: 6858-6862, 2004.
 13. Bobo, R. H., Laske, D. W., Akbasak, A., Morrison, P. F., Dedrick, R. L., and Oldfield, E. H. Convection-enhanced delivery of macromolecules in the brain. *Proc Natl Acad Sci U S A*, 91: 2076-2080, 1994.
 14. Mardor, Y., Rahav, O., Zauberman, Y., Lidar, Z., Ocherashvili, A., Daniels, D., Roth, Y., Maier, S. E., Orenstein, A., and Ram, Z. Convection-enhanced drug delivery: increased efficacy and magnetic resonance image monitoring. *Cancer Res*, 65: 6858-6863, 2005.
 15. Morrison, P. F., Chen, M. Y., Chadwick, R. S., Lonser, R. R., and Oldfield, E. H. Focal

- delivery during direct infusion to brain: role of flow rate, catheter diameter, and tissue mechanics. *Am J Physiol*, 277: R1218-1229, 1999.
16. Morrison, P. F., Laske, D. W., Bobo, H., Oldfield, E. H., and Dedrick, R. L. High-flow microinfusion: tissue penetration and pharmacodynamics. *Am J Physiol*, 266: R292-305, 1994.
 17. Chen, M. Y., Lonser, R. R., Morrison, P. F., Governale, L. S., and Oldfield, E. H. Variables affecting convection-enhanced delivery to the striatum: a systematic examination of rate of infusion, cannula size, infusate concentration, and tissue-cannula sealing time. *J Neurosurg*, 90: 315-320, 1999.
 18. Laske, D. W., Morrison, P. F., Lieberman, D. M., Corthesy, M. E., Reynolds, J. C., Stewart-Henney, P. A., Koong, S. S., Cummins, A., Paik, C. H., and Oldfield, E. H. Chronic interstitial infusion of protein to primate brain: determination of drug distribution and clearance with single-photon emission computerized tomography imaging. *J Neurosurg*, 87: 586-594, 1997.
 19. Lieberman, D. M., Laske, D. W., Morrison, P. F., Bankiewicz, K. S., and Oldfield, E. H. Convection-enhanced distribution of large molecules in gray matter during interstitial drug infusion. *J Neurosurg*, 82: 1021-1029, 1995.
 20. Lonser, R. R., Corthesy, M. E., Morrison, P. F., Gogate, N., and Oldfield, E. H. Convection-enhanced selective excitotoxic ablation of the neurons of the globus pallidus internus for treatment of parkinsonism in nonhuman primates. *J Neurosurg*, 91: 294-302, 1999.
 21. Lonser, R. R., Walbridge, S., Garmestani, K., Butman, J. A., Walters, H. A., Vortmeyer, A. O., Morrison, P. F., Brechbiel, M. W., and Oldfield, E. H. Successful and safe perfusion of the primate brainstem: in vivo magnetic resonance imaging of macromolecular distribution during infusion. *J Neurosurg*, 97: 905-913, 2002.

22. Kaiser, M. G., Parsa, A. T., Fine, R. L., Hall, J. S., Chakrabarti, I., and Bruce, J. N. Tissue distribution and antitumor activity of topotecan delivered by intracerebral clysis in a rat glioma model. *Neurosurgery*, *47*: 1391-1398; discussion 1398-1399, 2000.
23. Rousseau, J., Boudou, C., Estève, F., and Elleaume, H. Convection-enhanced delivery of an iodine tracer into rat brain for synchrotron stereotactic radiotherapy. *Int J Radiat Oncol Biol Phys*, *in press*, 2007.
24. Wu, G., Yang, W., Barth, R. F., Kawabata, S., Swindall, M., Bandyopadhyaya, A. K., Tjarks, W., Khorsandi, B., Blue, T. E., Ferketich, A. K., Yang, M., Christoforidis, G. A., Sferra, T. J., Binns, P. J., Riley, K. J., Ciesielski, M. J., and Fenstermaker, R. A. Molecular targeting and treatment of an epidermal growth factor receptor-positive glioma using boronated cetuximab. *Clin Cancer Res*, *13*: 1260-1268, 2007.
25. Yang, W., Barth, R. F., Wu, G., Kawabata, S., Sferra, T. J., Bandyopadhyaya, A. K., Tjarks, W., Ferketich, A. K., Moeschberger, M. L., Binns, P. J., Riley, K. J., Coderre, J. A., Ciesielski, M. J., Fenstermaker, R. A., and Wikstrand, C. J. Molecular targeting and treatment of EGFRvIII-positive gliomas using boronated monoclonal antibody L8A4. *Clin Cancer Res*, *12*: 3792-3802, 2006.
26. Biston, M. C., Joubert, A., Adam, J. F., Elleaume, H., Bohic, S., Charvet, A. M., Esteve, F., Foray, N., and Balosso, J. Cure of Fisher rats bearing radioresistant F98 glioma treated with cis-platinum and irradiated with monochromatic synchrotron X-rays. *Cancer Res*, *64*: 2317-2323, 2004.
27. Bernhardt, P., Friedland, W., and Paretzke, H. G. The role of atomic inner shell relaxations for photon-induced DNA damage. *Radiat Environ Biophys*, *43*: 77-84, 2004.
28. Corde, S., Balosso, J., Elleaume, H., Renier, M., Joubert, A., Biston, M. C., Adam, J. F., Charvet, A. M., Brochard, T., Le Bas, J. F., Esteve, F., and Foray, N. Synchrotron

- photoactivation of cisplatin elicits an extra number of DNA breaks that stimulate RAD51-mediated repair pathways. *Cancer Res*, 63: 3221-3227, 2003.
29. Corde, S., Biston, M. C., Elleaume, H., Esteve, F., Charvet, A. M., Joubert, A., Ducros, V., Bohic, S., Simionovici, A., Brochard, T., Nemoz, C., Renier, M., Tropres, I., Fiedler, S., Bravin, A., Thomlinson, W., Le Bas, J. F., and Balosso, J. Lack of cell death enhancement after irradiation with monochromatic synchrotron X rays at the K-shell edge of platinum incorporated in living SQ20B human cells as cis-diamminedichloroplatinum (II). *Radiat Res*, 158: 763-770, 2002.
 30. Barth, R. F. Rat brain tumor models in experimental neuro-oncology: the 9L, C6, T9, F98, RG2 (D74), RT-2 and CNS-1 gliomas. *J Neurooncol*, 36: 91-102, 1998.
 31. Koestner, A., Swenberg, J. A., and Wechsler, W. Transplacental production with ethylnitrosourea of neoplasms of the nervous system in Sprague-Dawley rats. *Am J Pathol*, 63: 37-56, 1971.
 32. Barth, R. F., Yang, W., Rotaru, J. H., Moeschberger, M. L., Boesel, C. P., Soloway, A. H., Joel, D. D., Nawrocky, M. M., Ono, K., and Goodman, J. H. Boron neutron capture therapy of brain tumors: enhanced survival and cure following blood-brain barrier disruption and intracarotid injection of sodium borocaptate and boronophenylalanine. *Int J Radiat Oncol Biol Phys*, 47: 209-218, 2000.
 33. Adam, J. F., Joubert, A., Biston, M. C., Charvet, A. M., Peoc'h, M., Le Bas, J. F., Balosso, J., Esteve, F., and Elleaume, H. Prolonged survival of Fischer rats bearing F98 glioma after iodine-enhanced synchrotron stereotactic radiotherapy. *Int J Radiat Oncol Biol Phys*, 64: 603-611, 2006.
 34. Dale, R. G. The application of the linear-quadratic dose-effect equation to fractionated and protracted radiotherapy. *Br J Radiol*, 58: 515-528, 1985.
 35. Douglas, B. G. and Fowler, J. F. Letter: Fractionation schedules and a quadratic dose-

- effect relationship. *Br J Radiol*, *48*: 502-504, 1975.
36. Liu, L., Bassano, D. A., Prasad, S. C., Hahn, S. S., and Chung, C. T. The linear-quadratic model and fractionated stereotactic radiotherapy. *Int J Radiat Oncol Biol Phys*, *57*: 827-832, 2003.
 37. Elleaume, H., Charvet, A. M., Berkvens, P., Berruyer, G., Brochard, T., Dabin, Y., Dominguez, M. C., Draperi, A., Fiedler, S., Goujon, G., Le Duc, G., Mattenet, M., Nemoz, C., Perez, M., Renier, M., Schulze, C., Spanne, P., Suortti, P., Thomlinson, W., Esteve, F., Bertrand, B., and Le Bas, J. F. Instrumentation of the ESRF medical imaging facility. *Nuclear Instruments and Methods in Physics Research Section A*, *428*: 513-527, 1999.
 38. Boudou, C., Balosso, J., Esteve, F., and Elleaume, H. Monte Carlo dosimetry for synchrotron stereotactic radiotherapy of brain tumours. *Phys Med Biol*, *50*: 4841-4851, 2005.
 39. Redgate, E. S., Deutsch, M., and Boggs, S. S. Time of death of CNS tumor-bearing rats can be reliably predicted by body weight-loss patterns. *Lab Anim Sci*, *41*: 269-273, 1991.
 40. Klein, J. P. and Moeschberger, M. L. Survival analysis techniques for censored and truncated data, 2nd edition. New York: Springer, 2003.
 41. Olivi, A., Gilbert, M., Duncan, K. L., Corden, B., Lenartz, D., and Brem, H. Direct delivery of platinum-based antineoplastics to the central nervous system: a toxicity and ultrastructural study. *Cancer Chemother Pharmacol*, *31*: 449-454, 1993.
 42. Carson, B. S., Sr., Wu, Q., Tyler, B., Sukay, L., Raychaudhuri, R., DiMeco, F., Clatterbuck, R. E., Olivi, A., and Guarnieri, M. New approach to tumor therapy for inoperable areas of the brain: chronic intraparenchymal drug delivery. *J Neurooncol*, *60*: 151-158, 2002.

43. Olivi, A., Ewend, M. G., Utsuki, T., Tyler, B., Domb, A. J., Brat, D. J., and Brem, H. Interstitial delivery of carboplatin via biodegradable polymers is effective against experimental glioma in the rat. *Cancer Chemother Pharmacol*, 39: 90-96, 1996.
44. Emerich, D. F., Winn, S. R., Snodgrass, P., LaFreniere, D., Agostino, M., Wiens, T., Xiong, H., and Bartus, R. T. Injectable chemotherapeutic microspheres and glioma II: enhanced survival following implantation into deep inoperable tumors. *Pharm Res*, 17: 776-781, 2000.
45. Strege, R. J., Liu, Y. J., Kiely, A., Johnson, R. M., Gillis, E. M., Storm, P., Carson, B. S., Jallo, G. I., and Guarnieri, M. Toxicity and cerebrospinal fluid levels of carboplatin chronically infused into the brainstem of a primate. *J Neurooncol*, 67: 327-334, 2004.

Table 1: Rat weight loss percentage and number of deaths within 7 days after chemotherapy treatment of F98 glioma.

Group	N*	Number of death	<5%	6-10%	11-30%
20 µg/20 µl at day 13	10	0	7	3	0
40 µg/40 µl at day 8	8	0	7	0	1
40 µg/40 µl at day 13	7	1	3	0	3
100 µg/20 µl at day 13	6	1	3	1	1

* N is the number of animals per group.

Table 2: Survival of F98 glioma-bearing rats after carboplatin chemotherapy.

Group	N*	Carboplatin CED treatment (dose/volume)	Survival time (days)			% Increased life span	
			Range	Mean \pm SE [‡]	Median	Mean	Median
1	7	Untreated	22-34	29 \pm 2	30	-	-
2	10	20 μ g/20 μ l	32-120	55 \pm 8	45	90	63
3	7	40 μ g/40 μ l	16-59	37 \pm 6	32	26	7
4	6	100 μ g/20 μ l	16-52	29 \pm 5	26	0	-13
5	8	40 μ g/40 μ l (at day 8)	27-200 [§]	64 \pm 22 (biased)	33	120 (biased)	10

* N is the number of animals per group.

[§] One rat was still alive at day 200.

[‡] SE is the standard error of the mean.

Table 3: Survival times of F98 glioma bearing rats following CED of carboplatin (20 μ g/20 μ l) and 3 fractions of 8 Gy delivered on days 14, 15 and 16 after tumor inoculation.

Irradiation Energy	Treatment	N*	Survival time (days)			% Increased life span	
			Range	Mean \pm SE ‡	Median	Mean	Median
6 MV	Untreated controls	9	25-36	29 \pm 1	28	-	-
	Chemotherapy controls	10	32-120	55 \pm 8	45	90	63
	Irradiated controls	11	35-56	43 \pm 2	42	50	50
	Chemo-radiotherapy	12	50-200 ‡ (2) §	97 \pm 15 (biased)	79	234 (biased)	182
80 keV	Untreated	6	26-32	28 \pm 1	28	-	-
	Irradiated controls	11	42-65	52 \pm 2	51	85	82
	Chemo-radiotherapy	12	47-200 ‡ (1) §	81 \pm 16 (biased)	60	184 (biased)	114

* N is the number of animals per group.

‡ Rats still alive after 200 days were euthanized at this date.

§ The number in parentheses indicates the number of rats surviving >200 days.

‡ SE is the standard error of the mean.

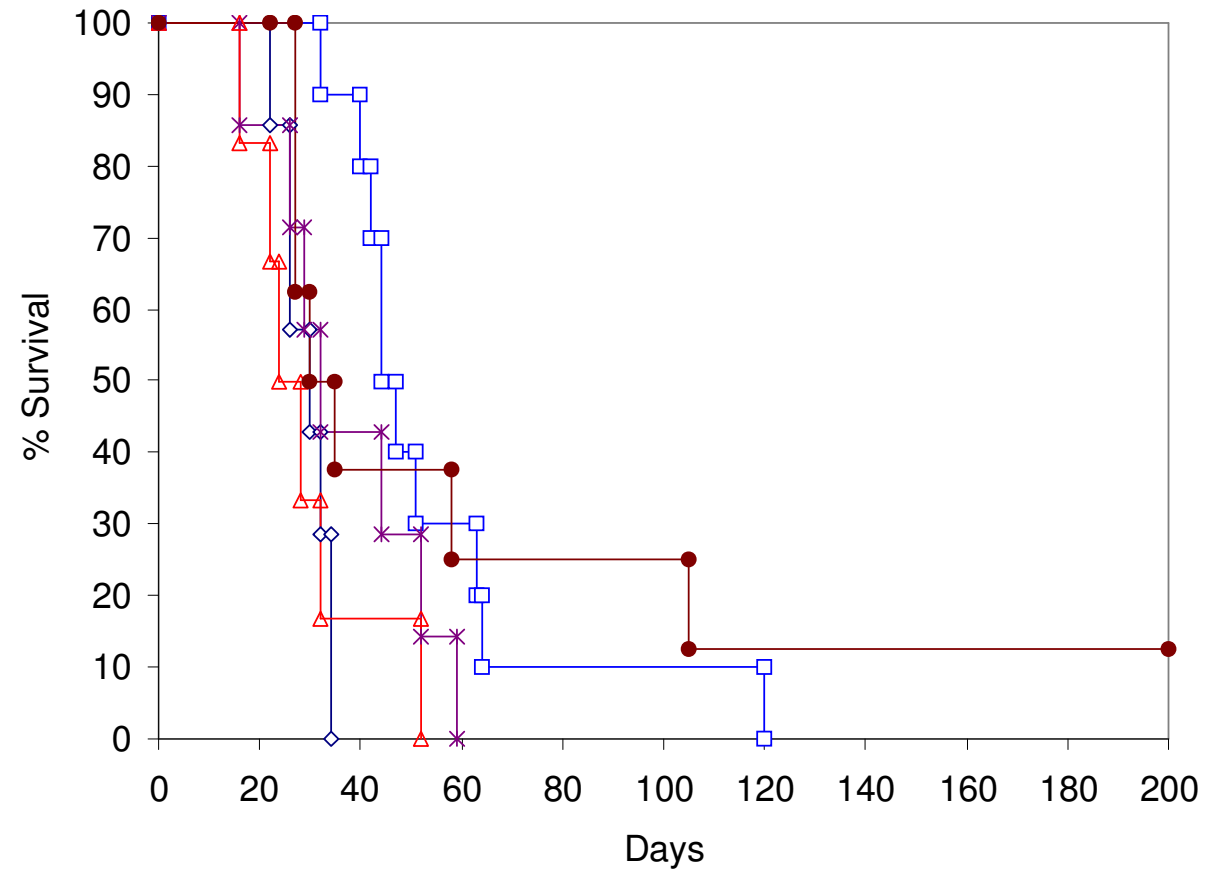


Figure 1: Kaplan Meier survival plots for F98 glioma-bearing rats after chemotherapy alone. Survival times in days after tumor implantation have been plotted for untreated animals (◇), CED of carboplatin 40 µg/ 40 µl delivered on day 13 after tumor implantation (*), or on day 8 after tumor implantation (●), CED of carboplatin 20 µg/ 20 µl delivered on day 13 after tumor implantation (□), CED of carboplatin 100 µg/ 20 µl delivered on day 13 after tumor implantation (△). One animal that received carboplatin at a dose of 40 µg/ 40 µl, on day 8 after tumor implantation, was still alive at day 200.

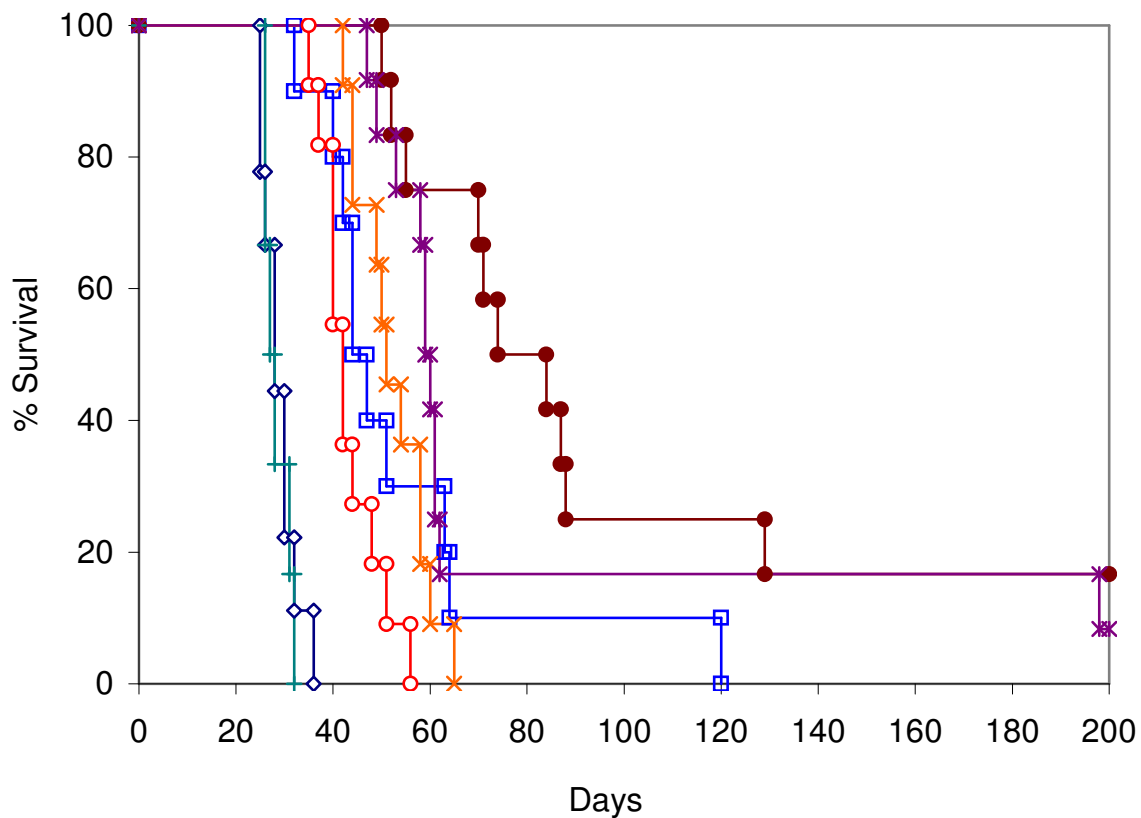


Figure 2: Kaplan Meier survival curves for F98 glioma-bearing rats after chemo-radiotherapy. Survival times in days after tumor implantation have been plotted for untreated animals (◇) and (◻), CED of carboplatin 20 µg/ 20 µl alone (◻), irradiation at 6 MV alone (3 fractions of 8 Gy) (○), or in combination with CED of carboplatin 20 µg/ 20 µl (●), irradiation at 80 keV alone (3 fractions of 8 Gy) (×), or in combination with CED of carboplatin 20 µg/ 20 µl (*).

