

Molecular pathogenesis of focal nodular hyperplasia and hepatocellular adenoma

Sandra Rebouissou^{1,2}, Paulette Bioulac-Sage^{3,4}, Jessica Zucman-Rossi^{1,2}

¹Inserm, U674, Génomique fonctionnelle des tumeurs solides, Paris, F-75010, France

²Université Paris 7 Denis Diderot, Institut Universitaire d'Hématologie, CEPH, Paris, F-75010, France

³Inserm, U889; Université Victor Segalen Bordeaux 2, IFR66, Bordeaux, F-33076, France

⁴CHU de Bordeaux, Hopital Pellegrin, Service d'Anatomie Pathologique, Bordeaux, F-33076, France

Corresponding Author: Jessica Zucman-Rossi, Inserm, U674, Génétique des tumeurs hépatiques, 27 rue Juliette Dodu, 75010 Paris, tel: 33 1 53 72 51 66; FAX: 33 1 53 72 51 58; Email: zucman@cephb.fr

Key Words: Hepatocellular adenoma, focal nodular hyperplasia, chromosome, gene mutation, hepatocyte nuclear factor 1, beta-catenin, inflammation, benign tumor, genetic alteration, SAA, CRP, FABP1, estrogen, steatosis.

Abbreviations:

APC (adenomatosis polyposis coli)

CTNNB1 (gene coding for β -catenin)

FAP (familial adenomatous polyposis coli)

FNH (focal nodular hyperplasia)

HCA (hepatocellular adenoma)

HCC (hepatocellular carcinoma)

HNF1 α (hepatocyte nuclear factor 1 alpha)

HUMARA (human androgen receptor)

TCF1 (transcription factor 1 coding for HNF1 α)

Abstract

Focal nodular hyperplasia (FNH) and hepatocellular adenomas (HCA) are benign tumors that occur in otherwise normal liver parenchyma. FNH is considered to be the result of a hyperplastic response to increased blood flow secondary to vascular malformations. Most FNH are polyclonal and to date, the molecular pathway and mechanisms that are altered in FNH have yet to be elucidated. In contrast, HCA are consistently monoclonal tumors, which have been divided up into 3 subtypes of tumors depending on the molecular alteration detected in the tumors: HNF1 α inactivation, β -catenin activation and/or an acute inflammatory response in the tumor. These molecular features are closely related to clinical and pathological characteristics, and one of the most critical correlations is the higher risk of malignant transformation for β -catenin activated HCA cases. Moreover, various risk factors, such as oral contraception and obesity, are associated with HCA occurrence and may collaborate with constitutional genetic predisposition related to HNF1 α or CYP1B1 germline mutations. Altogether, the recent identification of different molecular pathways that contribute to the tumor development has significantly increased our knowledge of benign hepatocellular tumorigenesis. These findings may modify our clinical practice, particularly in the diagnosis and follow-up of HCA patients.

Focal nodular hyperplasia and hepatocellular adenomas are benign liver tumors that may be sometimes difficult to diagnose. The recent identification of various molecular pathways altered in these tumors has significantly increased our knowledge of benign hepatocellular tumorigenesis. Moreover, analysis of the genotype-phenotype correlation in hepatocellular adenoma also enabled the identification of a patho-molecular classification of these tumors. Novel markers specific to these subtypes have been developed, implicating a potential for use in clinical practice. In this review, we will focus on the recent progress in understanding of the molecular mechanisms in these two hepatocellular tumors.

1 - Focal Nodular Hyperplasia (FNH)

1.1 - Clinical and pathological characteristics of FNH

Focal nodular hyperplasia (FNH), first described by Edmondson, are the second most frequent benign liver tumors after hemangioma (1). FNH more frequently develops in women (M/F=1/8) between 20 to 50 years old (2). An increased risk linked to oral contraceptive use is still under debate; however, some studies suggest that use of contraceptive pills may increase the size of the nodules (3-5). In 1985, Wanless and collaborators proposed that FNH is an hyperplastic response of the hepatic parenchyma to a preexisting local arterial spider-like malformation, likely with a developmentally abnormal origin (6). FNH is also related to well-known vascular diseases, such as the hereditary hemorrhagic telangiectasia (Rendu–Osler–Weber disease) or the congenital absence of the portal vein (7-9).

FNH usually occurs in normal liver and is multinodular, composed of normal hepatocytes arranged in 1-2 cell-thick plates. Bile ductules are usually found at the interface between hepatocytes and fibrous regions (10, 11). Increased arterial flow is thought to hyperperfuse the local parenchyma, leading to secondary hepatocellular hyperplasia. FNH is therefore considered the result of a hyperplastic response to increased blood flow (6, 12-14), and, accordingly, FNH usually does not bleed or undergo malignant transformation, justifying therapeutic abstention.

1.2 - Molecular features associated with FNH

Only few data describing molecular disorders observed in FNH have been described in the literature. Clonal analysis using the HUMARA test demonstrated the reactive polyclonal nature of liver cells in FNH in 50 to 100% of the cases, depending on the series (15-19) (Table 1). Other studies analyzing chromosome gains and losses by comparative genomic hybridization, allelotyping, or karyotype identified chromosome alterations, indicating a clonal origin of the FNH nodules in 14 to 50% of the cases (19-23) (Table 1). However, genetic analysis of FNH failed to identify somatic gene mutations in β -catenin gene (*CTNNB1*), *TP53*, *APC* or *HNF1 α* (19, 24, 25). Recent studies showed that the mRNA expression levels of the angiopoietin genes (*ANGPT1* and *ANGPT2*) involved in vessel maturation are altered, with the *ANGPT1/ANGPT2* ratio increased in all FNH samples analyzed (18, 19). Apart from the dystrophic vessels, the phenotypic characteristics of parenchymal vessels in FNH confirms that the lesion retains the overall organization of the normal liver tissue (26). The deposition of vitronectin in the central fibrous scar is likely a result of local hemodynamic disturbance, further strengthening the role of vascular abnormalities as a main determinant of FNH (26). Recently, we identified an activation of the β -catenin pathway in FNH without β -catenin or Axin1 mutation (unpublished results). β -catenin pathway activation was restricted to enlarged periveinous areas in FNH, which may explain the slight polyclonal over-proliferation of hepatocytes at the origin of the lesion.

Table 1. Summary of FNH Molecular Analyses

Published Studies	Number of analyzed cases	Monoclonal lesions (%)
Gaffey 1996*	8	6 (75)
Paradis 1997*	13	0
Chen TC 2001*	1	1
Bioulac-Sage 2005***	18	7 (38)
Zhang SH 2004*	1	0
Chen YJ** 2002	6	3 (50)
Raidl M 2004*	3	1 (33)
Kellner U 2003*	7	1 (14)
Nakayama S, 2006	1	0
Heimann P 1995***	1	1
Overall studies	59	20 (34)

*HUMARA test, **gain or loss of chromosome by CGH or allelotype, ***karyotype

2 - Hepatocellular adenoma (HCA)

2.1 - Clinical and pathological characteristics of HCA

In occidental countries, hepatocellular adenomas (HCA) are rare tumors that usually develop in women who use oral contraceptives. The relationship between oral contraception and HCA occurrence has been suggested by Baum and collaborators in 1973 (27) and was subsequently confirmed in several case-control studies (28-32). HCA occurrence may also be related to androgenic-anabolic steroids use (33-37), glycogenosis type I and III (38-43). HCA is a benign proliferation of hepatocytes in an otherwise normal liver. The HCA nodule, rarely encapsulated, varies from 0.5 to 15 cm in diameter with arterial vascularization. Proliferating hepatocytes usually resemble normal cells that may be steatotic or show glycogen storage. The tumor is also characterized by the lack of frequent mitosis, portal tract and cholangiolar proliferation (11, 44). HCA nodules are generally solitary, but two or three nodules occasionally develop simultaneously. The development of more than 10 HCA nodules is rare and has been specifically defined as adenomatosis by Flejou and collaborators in 1985. In this context, HCA development was described to be less significantly related to oral contraception and with women (45); however, adenomatosis is also described more frequently in women (46, 47), and is also frequently associated with diabetes, sometimes in a familial context (46, 48).

During its natural evolution, HCA may remain stable, increase in size, or regress (49-52). Regression is more frequently described in HCA related to androgenic-anabolic steroids and glycogenosis after hormone withdrawal, or after an appropriate alimentary regiment (53-56). HCA occasionally bleeds and this risk increases with the nodule's size (27, 57, 58). Malignant transformation in hepatocellular carcinoma is considered to be extremely rare but has been consistently described (59-63). The risk of malignant transformation seems to be more critical in HCA related to androgenic-anabolic steroid exposure or glycogenosis type I (36, 37, 64, 65).

2.2 - Molecular features associated with HCA

HCA are monoclonal tumors (18, 19, 66). However, in contrast with hepatocellular carcinomas that show a large number of recurrent chromosome and genetic alterations (see (67) for review), prior to 2002 only a few chromosome losses and gains were identified in HCA (68-71). In 2002, several recurrent mutations were identified in the *TCF1* gene encoding hepatocyte nuclear factor 1 α (HNF1 α), *CTNNB1* encoding β -catenin, and APC (adenomatosis polyposis coli). Methylation of p14(ARF) and p16(INK4a) have also been found in approximately 20% of HCA cases (72).

a- HNF1 α inactivation

The *TCF1* gene is located at chromosome 12q24.2 (73), and encodes the hepatocyte nuclear factor 1 α (HNF1 α), a 681 amino-acid homeodomain transcription factor that is involved in hepatocyte differentiation (74). HNF1 α controls the expression of liver-specific genes, such as β -fibrinogen, α 1-antitrypsin and albumin (74). HNF1 α is also expressed in several polarized epithelia, and inactivation of the protein in mice revealed its important role in renal, pancreatic and liver function (75-78). In mice, loss of HNF1 α activity was associated with the development of fatty liver, hepatomegaly, hepatocyte dysplasia and proliferation (75, 76, 79). Moreover, the mouse model also revealed a critical role for HNF1 α in cholesterol/HDL and bile acid metabolism (77). We identified HNF1 α as a human tumor suppressor gene involved in liver tumorigenesis, as we found biallelic inactivating mutations of this gene in ~35-50% of HCA as well as a few cases of well-differentiated hepatocellular carcinomas that developed in the absence of cirrhosis (80-82). The mutations were predicted to inactivate the protein as they included mainly nonsense and frame-shift mutations within the N-terminal portion of the protein, or mutations leading to amino-acid substitutions within the homeodomain (80-82). Mutations of HNF1 α or HNF1 β have also been identified in rare cases of colon, renal, breast and endometrial cancers (83-86).

In two comprehensive analyses of genotype-phenotype correlations in large series of HCA, we showed that HNF1 α mutations define a homogeneous group of tumors phenotypically characterized by the recurrent presence of marked steatosis without inflammation or cytological abnormalities (81, 82). Furthermore, we identified a repression of gluconeogenesis coordinated with an activation of glycolysis, citrate shuttle and fatty acid synthesis, which predicted elevated rates of lipogenesis in HCA tumors harboring mutations in HNF1 α (87). In these tumors, lipid composition was dramatically modified and, surprisingly, lipogenesis activation did not operate through SREBP-1 and ChREBP, both of which instead were repressed. We also found a silencing of L-FABP, which encodes liver fatty acid binding protein 1, suggesting that impaired fatty acid trafficking may also contribute to the fatty phenotype. We showed that absence of L-FABP staining in HCA was specific to HNF1 α inactivation among the different benign liver tumor subtypes (82, 87). Together this indicates that steatosis, frequently observed in HCA, may contribute to tumorigenesis, and this occurs through a constant and specific mechanism in the HNF1 α inactivated tumor subtype.

b- β -catenin activation

Chen and collaborators sought to analyze potential alterations of candidate critical genes in HCA (24). They focused on the Wnt/ β -catenin pathway, as activating mutations of β -catenin are found in 20 to 34% of hepatocellular carcinomas, suggesting that β -catenin is the

most frequently activated oncogene in HCC (67, 88, 89). Furthermore, this pathway plays a key role in liver physiological phenomena, such as lineage specification, differentiation, stem cell renewal, epithelial-mesenchymal transition, zonation, proliferation, cell adhesion and liver regeneration (90-97). Chen et al. identified a β -catenin activating mutation in 3 of a series of 10 tested HCA cases. Simultaneously, a β -catenin activating mutation was also identified in an HCA occurring in a female child (98). Nuclear accumulation of β -catenin was also identified in 46% of 18 analyzed HCA cases by Torbenson and al, but none were activating mutated (99). Other genes in the Wnt pathways, however, such as adenomatous polyposis coli (APC) or the Axin family genes, did not show any mutations in sporadic adenomas (24, 99).

In our two series of approximately 160 different genotyped HCAs, we identified an activating β -catenin mutation in 15 to 19% of the cases (81, 82). In 67% of these cases, the mutations consist of a large in-frame deletion of exon 3 that excludes the amino acids normally phosphorylated by GSK3 β . In contrast to the other subtype of HCA, β -catenin activated adenomas were frequently found in males (38%), characterized by cytological abnormalities and an acinar pattern, and were frequently associated with malignant transformation (81, 82). We did not find any HCA cases with both β -catenin mutations and biallelic inactivation of HNF1 α , suggesting that these two tumorigenic pathways are mutually exclusive. Recently, we showed that β -catenin activated HCA may be robustly diagnosed using immunochemistry by assessing the over-expression of β -catenin and glutamine synthetase, a target of β -catenin, (11). This finding is important in a routine practice to identify HCA at highest risk of malignant transformation, while remembering that such a transformation also occurs in other molecular subtypes of HCA but at a lower frequency.

c- other molecular alterations

In 2005, Lehmann and collaborators analyzed the methylation levels of nine genes in a series of HCA, FNH, HCC, adjacent and unrelated normal liver tissues (100). This analysis revealed that hepatocellular adenomas display a methylation profile much more similar to normal liver tissues and focal nodular hyperplasias than to hepatocellular carcinomas. Moreover, the lack of significant difference between methylation profiles observed in FNH when compared to HCA suggest that aberrant methylation may not play a major role in adenoma pathogenesis in contrast to HCC. Vander Borgh and collaborators evaluated the expression and localization of hepatic transporters in HCA, different types of FNH and well- to moderately differentiated HCC in non-cirrhotic liver and compared them with normal liver (101). They observed diffuse over-expression of MRP3 and down-regulation of OATP2/8 in HCA, while FNHs had a completely different expression profile explaining their cholestatic features. In HCCs, canalicular transporters were largely absent, probably as a consequence of dedifferentiation. Whereas transporter dysregulations can easily explain specific features, their role in benign tumor pathogenesis remained to be elucidated.

In our genotype-phenotype correlation study of HCA, we defined a subgroup of lesions characterized by the presence of inflammatory infiltrates (81). Representing 35% of HCA cases, these nodules exhibited additional features such as sinusoidal dilatation, dystrophic vessels and ductular reaction, and included most of the previously described so-called “telangiectatic focal nodular hyperplasia” cases (19). In these tumors, we detected elevated expression of members of the acute phase inflammatory response (serum amyloid protein, SAA, and C-reactive protein, CRP) at both the mRNA and protein levels (82). Interestingly, our immunohistochemical analysis showed that SAA was sharply over-expressed in the tumor lesion without particular reinforcement in proximity of the inflammatory infiltrates, which

remained negative, as well as Kupffer cells and other sinusoidal cells in the HCA that did not over-express SAA. These results suggested that the inflammatory pathway was intrinsically deregulated in tumor hepatocytes, and inflammatory infiltrates could be a secondary effect. According to this hypothesis, we identified a typical case of inflammatory HCA with clinical manifestation of an inflammatory syndrome and SAA expression in the tumor; after complete resection of the nodule, the inflammatory syndrome disappeared, indicating that peripheral inflammatory proteins were effectively secreted by the tumor (102). We also found that inflammatory HCAs more frequently developed in patients presenting a high body mass index and excessive alcohol consumption (82). These results suggest that alcohol intake and obesity could have a direct role in the initiation of tumorigenesis of inflammatory HCA. Additional molecular studies are required to identify the molecular defect at the origin of these tumors and to better understand the relationship with β -catenin activation, as SAA over-expression and β -catenin activation are not mutually exclusive and coexist in a subset of cases. The main molecular findings in HCA are represented in Figure 1.

2.3- Genetic predisposition to HCA development.

Heterozygous germline mutations in the gene encoding HNF1 α are responsible for an autosomal dominant form of non-insulin-dependent diabetes mellitus, or maturity onset diabetes of the young type 3 (MODY3, OMIM#600496), in which subjects usually develop hyperglycemia before 25 years of age (103). In our series of 85 HCA cases exhibiting biallelic HNF1 α inactivation, one allele was germline mutated in 8 cases and these patients developed adenomatosis. Familial analyses performed in 4 independent germline adenomatosis showed that all 11 relatives who developed adenomatosis displayed a germline HNF1 α mutation (104, 105), and most of the patients who developed adenomatosis also had diabetes. Clearly, in these families, HNF1 α germline mutations are predisposing to both diabetes and liver adenomatosis, and such an association between familial adenomas and diabetes was first described by Foster and collaborators in 1978 (48). However, in our French families, 16 individuals with a germline HNF1 α mutation did not develop any liver tumors. These observations suggested that germline HNF1 α mutations predisposed to liver adenomatosis with an incomplete penetrance, and raised the possibility for modifier genes. In contrast, among the patients with somatic HNF1 α inactivation, we identified 4 women who developed multiple HNF1 α -mutated adenomas simultaneously. These cases could be due to a genetic predisposition to develop HNF1 α mutated adenomas, possibly associated with estrogen metabolism and in the absence of HNF1 α germline mutation.

Recently, as described by Chen (106), we identified 7 HCA cases with a monoallelic HNF1 α mutation without inactivation of the second allele or modification of the HNF1 α targeted gene expression (unpublished data). Six of these cases corresponded to a novel HNF1 α germline missense mutation in the carboxy-terminal part of the protein, mutations never before detected in HCA. Moreover, 3 of these cases were mutated for β -catenin. We thus hypothesize that in rare cases, HNF1 α germline missense mutations could participate in genetic predisposition towards and subsequent development of HCA via a carcinogenic pathway other than the complete HNF1 α inactivation.

In order to identify a genetic predisposition in women with HCA with somatic mutations in HNF1 α or to identify a gene modifying the penetrance of adenomatosis in germline HNF1 α mutated patients, we searched for alterations in candidate genes involved in estrogen metabolism (*CYP1A1*, *CYP1A2*, *CYP1B1*, *CYP3A4*, *CYP3A5*, *COMT*, *UGT2B7*, *NQO1*, *GSTM1*, *GSTP1*, and *GSTT1*). We identified CYP1B1 germline heterozygous

mutations in 14% of the women presenting HNF1 α mutated HCA (107), and all mutations resulted in decreased enzymatic activity. Thus, CYP1B1 germline inactivating mutations appear to predispose women to the development of sporadic HNF1 α mutated HCA. In addition, mutation of CYP1B1 modifies the penetrance of the liver adenomatosis phenotype in HNF1 α germline mutated patients, as we found that all relatives in a large family presenting an adenomatosis were also germline mutated in both the HNF1 α and CYP1B1 genes (107).

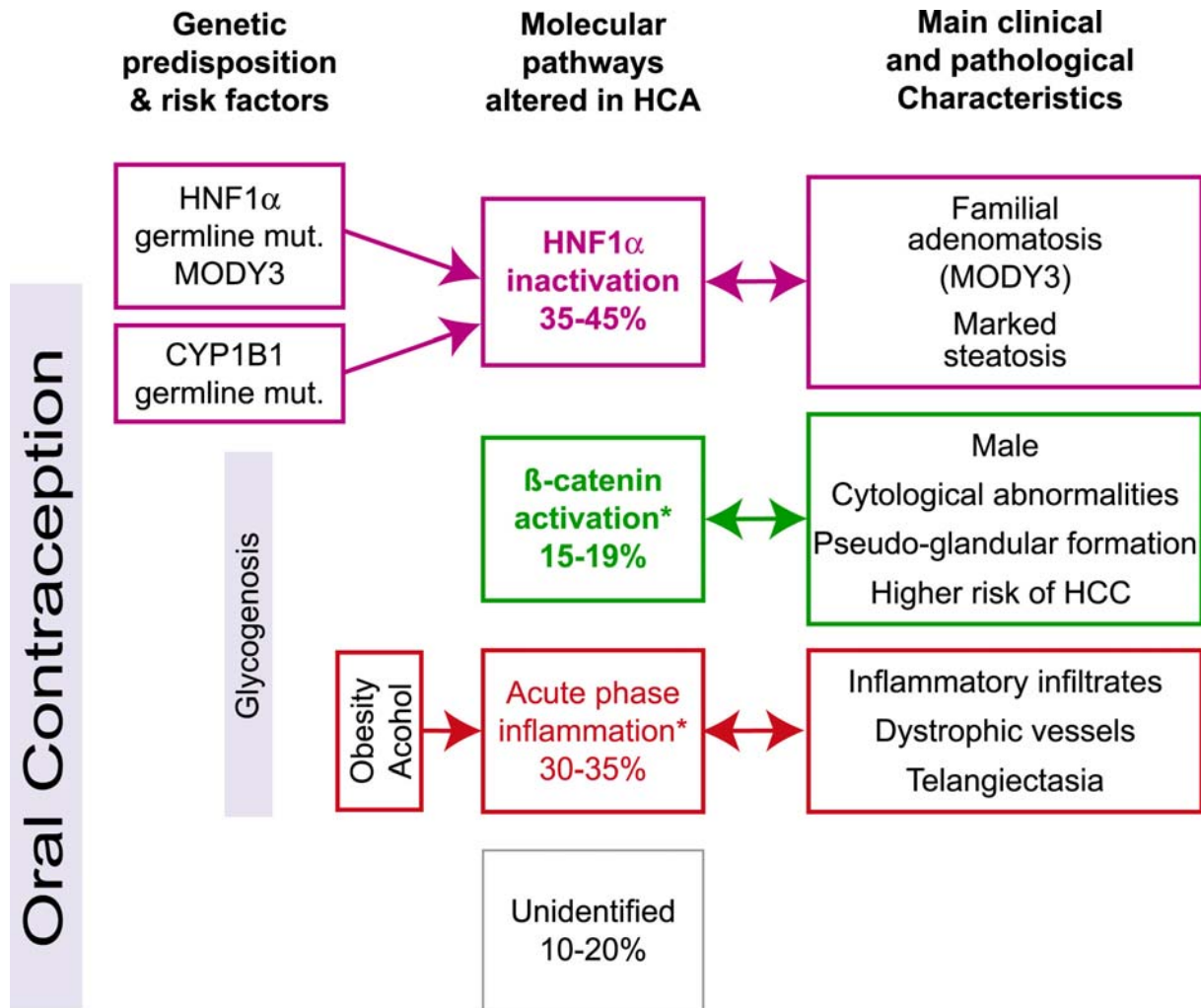
HCA is also detected as a rare extracolonic tumor developed in patients presenting familial adenomatous polyposis coli (FAP, OMIM #175100 (108, 109)). In colorectal tumors associated with FAP, biallelic inactivation of the APC gene is consistently detected, and inactivation of the APC gene in tumors leads to β -catenin accumulation, thus the activation of the Wnt/wingless pathway. Biallelic inactivation of the APC gene was recently described in two HCA cases that developed in FAP patients (25, 110). We also reported the case of a FAP woman presenting a hepatocellular adenoma after oestrogenic oral contraception use. In this steatotic adenoma, we identified an inactivating biallelic mutation of HNF1 α without inactivation of the second APC allele or an activation of the β -catenin target genes. These results suggest that benign hepatocellular tumorigenesis may be dependent or independent of the Wnt/ β -catenin pathway in patients with FAP. Finally, we genotyped three cases of HCA related to glycogenesis type 1a, and two nodules were inflammatory since one was β -catenin activated showing various possible alterations of carcinogenesis pathways related to the germline deficiency of glucose-6-phosphatase (G6Pase) catalytic activity.

Conclusion

Focal nodular hyperplasia are hyperplastic responses to a hemodynamic disturbance related to vascular abnormalities. Molecular pathways altered in these tumors are poorly understood. In contrast, in hepatocellular adenomas, at least 3 different molecular pathways (HNF1 α inactivation, β -catenin and inflammatory activation) are known to be altered (Figure 1). These molecular findings have enabled the division of HCA into homogenous subtypes of tumors closely related to specific predisposition, clinical and pathological features.

Acknowledgements: We warmly thank all the other participants to the GENTHEP (Groupe d'étude Génétique des Tumeurs Hépatiques) network. This work was supported by the Inserm (Réseau de Recherche clinique et en santé des populations), ARC n°5188 and the SNFGE. SR is supported by a Ligue Nationale Contre le Cancer doctoral fellowship

Fig. 1. Schematic representation of the different molecular pathways altered in HCA. The main risk factors and known genetic predispositions are indicated on the left; the principal clinical and pathological features of the HCA subtypes defined by their molecular pathways altered are indicated on the right. Arrows indicate the significant relationships; mut.=mutation.



*some tumors may be simultaneously inflammatory and β-catenin activated

Reference

1. Edmondson HA. Tumors of the liver and intrahepatic bile ducts. In: Atlas of tumor pathology. In: Washington, DC: Armed Forces Institute of Pathology; 1958.
2. Nguyen BN, Flejou JF, Terris B, Belghiti J, Degott C. Focal nodular hyperplasia of the liver: a comprehensive pathologic study of 305 lesions and recognition of new histologic forms. *Am J Surg Pathol* 1999;23:1441-54.
3. Heinemann LA, Weimann A, Gerken G, Thiel C, Schlaud M, DoMinh T. Modern oral contraceptive use and benign liver tumors: the German Benign Liver Tumor Case-Control Study. *Eur J Contracept Reprod Health Care* 1998;3:194-200.
4. Mathieu D, Kobeiter H, Cherqui D, Rahmouni A, Dhumeaux D. Oral contraceptive intake in women with focal nodular hyperplasia of the liver. *Lancet* 1998;352:1679-80.
5. Scalori A, Tavani A, Gallus S, La Vecchia C, Colombo M. Oral contraceptives and the risk of focal nodular hyperplasia of the liver: a case-control study. *Am J Obstet Gynecol* 2002;186:195-7.
6. Wanless IR, Mawdsley C, Adams R. On the pathogenesis of focal nodular hyperplasia of the liver. *Hepatology* 1985;5:1194-200.
7. Altavilla G, Guariso G. Focal nodular hyperplasia of the liver associated with portal vein agenesis: a morphological and immunohistochemical study of one case and review of the literature. *Adv Clin Path* 1999;3:139-45.
8. Buscarini E, Danesino C, Plauchu H, de Fazio C, Olivieri C, Brambilla G, et al. High prevalence of hepatic focal nodular hyperplasia in subjects with hereditary hemorrhagic telangiectasia. *Ultrasound Med Biol* 2004;30:1089-97.
9. De Gaetano AM, Gui B, Macis G, Manfredi R, Di Stasi C. Congenital absence of the portal vein associated with focal nodular hyperplasia in the liver in an adult woman: imaging and review of the literature. *Abdom Imaging* 2004;29:455-9.
10. Makhlof HR, Abdul-Al HM, Goodman ZD. Diagnosis of focal nodular hyperplasia of the liver by needle biopsy. *Hum Pathol* 2005;36:1210-6.
11. Bioulac-Sage P, Balabaud C, Bedossa P, Scoazec JY, Chiche L, Dhillon AP, et al. Pathological diagnosis of liver cell adenoma and focal nodular hyperplasia: Bordeaux update. *J Hepatol* 2007;46:521-7.
12. Fukukura Y, Nakashima O, Kusaba A, Kage M, Kojiro M. Angioarchitecture and blood circulation in focal nodular hyperplasia of the liver. *J Hepatol* 1998;29:470-5.
13. Gaiani S, Piscaglia F, Serra C, Bolondi L. Hemodynamics in focal nodular hyperplasia. *J Hepatol* 1999;31:576.
14. Wanless IR, Albrecht S, Bilbao J, Frei JV, Heathcote EJ, Roberts EA, et al. Multiple focal nodular hyperplasia of the liver associated with vascular malformations of various organs and neoplasia of the brain: a new syndrome. *Mod Pathol* 1989;2:456-62.
15. Gaffey MJ, Iezzoni JC, Weiss LM. Clonal analysis of focal nodular hyperplasia of the liver. *Am J Pathol* 1996;148:1089-96.
16. Chen TC, Chou TB, Ng KF, Hsieh LL, Chou YH. Hepatocellular carcinoma associated with focal nodular hyperplasia. Report of a case with clonal analysis. *Virchows Arch* 2001;438:408-11.
17. Zhang SH, Cong WM, Wu MC. Focal nodular hyperplasia with concomitant hepatocellular carcinoma: a case report and clonal analysis. *J Clin Pathol* 2004;57:556-9.
18. Paradis V, Laurent A, Flejou JF, Vidaud M, Bedossa P. Evidence for the polyclonal nature of focal nodular hyperplasia of the liver by the study of X-chromosome inactivation. *Hepatology* 1997;26:891-5.

19. Bioulac-Sage P, Rebouissou S, Sa Cunha A, Jeannot E, Lepreux S, Blanc JF, et al. Clinical, morphologic, and molecular features defining so-called telangiectatic focal nodular hyperplasias of the liver. *Gastroenterology* 2005;128:1211-8.
20. Raidl M, Pirker C, Schulte-Hermann R, Aubele M, Kandioler-Eckersberger D, Wrba F, et al. Multiple chromosomal abnormalities in human liver (pre)neoplasia. *J Hepatol* 2004;40:660-8.
21. Kellner U, Jacobsen A, Kellner A, Mantke R, Roessner A, Rocken C. Comparative genomic hybridization. Synchronous occurrence of focal nodular hyperplasia and hepatocellular carcinoma in the same liver is not based on common chromosomal aberrations. *Am J Clin Pathol* 2003;119:265-71.
22. Heimann P, Ogur G, Debusscher C, De Valck C, Sariban E, Deprez C, et al. Multiple clonal chromosome aberrations in a case of childhood focal nodular hyperplasia of the liver. *Cancer Genet Cytogenet* 1995;85:138-42.
23. Chen YJ, Chen PJ, Lee MC, Yeh SH, Hsu MT, Lin CH. Chromosomal analysis of hepatic adenoma and focal nodular hyperplasia by comparative genomic hybridization. *Genes Chromosomes Cancer* 2002;35:138-43.
24. Chen YW, Jeng YM, Yeh SH, Chen PJ. P53 gene and Wnt signaling in benign neoplasms: beta-catenin mutations in hepatic adenoma but not in focal nodular hyperplasia. *Hepatology* 2002;36:927-35.
25. Blaker H, Sutter C, Kadmon M, Otto HF, Von Knebel-Doeberitz M, Gebert J, et al. Analysis of somatic APC mutations in rare extracolonic tumors of patients with familial adenomatous polyposis coli. *Genes Chromosomes Cancer* 2004;41:93-8.
26. Scoazec JY, Flejou JF, D'Errico A, Couvelard A, Kozyraki R, Fiorentino M, et al. Focal nodular hyperplasia of the liver: composition of the extracellular matrix and expression of cell-cell and cell-matrix adhesion molecules. *Hum Pathol* 1995;26:1114-25.
27. Baum JK, Bookstein JJ, Holtz F, Klein EW. Possible association between benign hepatomas and oral contraceptives. *Lancet* 1973;2:926-9.
28. Edmondson HA, Henderson B, Benton B. Liver-cell adenomas associated with use of oral contraceptives. *N Engl J Med* 1976;294:470-2.
29. Lansing PB, McQuitty JT, Bradburn DM. Benign liver tumors: what is their relationship to oral contraceptives? *Am Surg* 1976;42:744-60.
30. Vana J, Murphy GP, Aronoff BL, Baker HW. Primary liver tumors and oral contraceptives. Results of a survey. *Jama* 1977;238:2154-8.
31. Christopherson WM, Mays ET, Barrows G. A clinicopathologic study of steroid-related liver tumors. *Am J Surg Pathol* 1977;1:31-41.
32. Rooks JB, Ory HW, Ishak KG, Strauss LT, Greenspan JR, Hill AP, et al. Epidemiology of hepatocellular adenoma. The role of oral contraceptive use. *Jama* 1979;242:644-8.
33. Farrell GC, Joshua DE, Uren RF, Baird PJ, Perkins KW, Kronenberg H. Androgen-induced hepatoma. *Lancet* 1975;1:430-2.
34. Lesna M, Spencer I, Walker W. Letter: Liver nodules and androgens. *Lancet* 1976;1:1124.
35. Sale GE, Lerner KG. Multiple tumors after androgen therapy. *Arch Pathol Lab Med* 1977;101:600-3.
36. Johnson FL, Lerner KG, Siegel M, Feagler JR, Majerus PW, Hartmann JR, et al. Association of androgenic-anabolic steroid therapy with development of hepatocellular carcinoma. *Lancet* 1972;2:1273-6.
37. Henderson JT, Richmond J, Sumerling MD. Androgenic-anabolic steroid therapy and hepatocellular carcinoma. *Lancet* 1973;1:934.

38. Bianchi L. Glycogen storage disease I and hepatocellular tumours. *Eur J Pediatr* 1993;152 Suppl 1:S63-70.
39. Lee P, Mather S, Owens C, Leonard J, Dicks-Mireaux C. Hepatic ultrasound findings in the glycogen storage diseases. *Br J Radiol* 1994;67:1062-6.
40. Smit GP, Fernandes J, Leonard JV, Matthews EE, Moses SW, Odievre M, et al. The long-term outcome of patients with glycogen storage diseases. *J Inherit Metab Dis* 1990;13:411-8.
41. de Parscau L, Guibaud P, Maire I. [Glycogenoses type 1b and 1c]. *Pediatrie* 1988;43:661-5.
42. Talente GM, Coleman RA, Alter C, Baker L, Brown BI, Cannon RA, et al. Glycogen storage disease in adults. *Ann Intern Med* 1994;120:218-26.
43. Labrune P, Trioche P, Duvaltier I, Chevalier P, Odievre M. Hepatocellular adenomas in glycogen storage disease type I and III: a series of 43 patients and review of the literature. *J Pediatr Gastroenterol Nutr* 1997;24:276-9.
44. Terminology of nodular hepatocellular lesions. International Working Party. *Hepatology* 1995;22:983-93.
45. Flejou JF, Barge J, Menu Y, Degott C, Bismuth H, Potet F, et al. Liver adenomatosis. An entity distinct from liver adenoma? *Gastroenterology* 1985;89:1132-8.
46. Chiche L, Dao T, Salame E, Galais MP, Bouvard N, Schmutz G, et al. Liver adenomatosis: reappraisal, diagnosis, and surgical management: eight new cases and review of the literature. *Ann Surg* 2000;231:74-81.
47. Grazioli L, Federle MP, Ichikawa T, Balzano E, Nalesnik M, Madariaga J. Liver adenomatosis: clinical, histopathologic, and imaging findings in 15 patients. *Radiology* 2000;216:395-402.
48. Foster JH, Donohue TA, Berman MM. Familial liver-cell adenomas and diabetes mellitus. *N Engl J Med* 1978;299:239-41.
49. Buhler H, Pirovino M, Akobiantz A, Altorfer J, Weitzel M, Maranta E, et al. Regression of liver cell adenoma. A follow-up study of three consecutive patients after discontinuation of oral contraceptive use. *Gastroenterology* 1982;82:775-82.
50. Steinbrecher UP, Lisbona R, Huang SN, Mishkin S. Complete regression of hepatocellular adenoma after withdrawal of oral contraceptives. *Dig Dis Sci* 1981;26:1045-50.
51. Mariani AF, Livingstone AS, Pereiras RV, Jr., van Zuiden PE, Schiff ER. Progressive enlargement of an hepatic cell adenoma. *Gastroenterology* 1979;77:1319-25.
52. Svrcek M, Jeannot E, Arrive L, Poupon R, Fromont G, Flejou JF, et al. Regressive liver adenomatosis following androgenic progestin therapy withdrawal: a case report with a 10-year follow-up and a molecular analysis. *Eur J Endocrinol* 2007;156:617-21.
53. Westaby D, Portmann B, Williams R. Androgen related primary hepatic tumors in non-Fanconi patients. *Cancer* 1983;51:1947-52.
54. Touraine RL, Bertrand Y, Foray P, Gilly J, Philippe N. Hepatic tumours during androgen therapy in Fanconi anaemia. *Eur J Pediatr* 1993;152:691-3.
55. Socas L, Zumbado M, Perez-Luzardo O, Ramos A, Perez C, Hernandez JR, et al. Hepatocellular adenomas associated with anabolic androgenic steroid abuse in bodybuilders: a report of two cases and a review of the literature. *Br J Sports Med* 2005;39:e27.
56. Parker P, Burr I, Slonim A, Ghishan FK, Greene H. Regression of hepatic adenomas in type Ia glycogen storage disease with dietary therapy. *Gastroenterology* 1981;81:534-6.
57. Kerlin P, Davis GL, McGill DB, Weiland LH, Adson MA, Sheedy PF, 2nd. Hepatic adenoma and focal nodular hyperplasia: clinical, pathologic, and radiologic features. *Gastroenterology* 1983;84:994-1002.

58. Kent DR, Nissen ED, Nissen SE, Ziehm DJ. Effect of pregnancy on liver tumor associated with oral contraceptives. *Obstet Gynecol* 1978;51:148-51.
59. Foster JH, Berman MM. The malignant transformation of liver cell adenomas. *Arch Surg* 1994;129:712-7.
60. Grigsby P, Meyer JS, Sicard GA, Huggins MB, Lamar DJ, DeSchryver-Kecskemeti K. Hepatic adenoma within a spindle cell carcinoma in a woman with a long history of oral contraceptives. *J Surg Oncol* 1987;35:173-9.
61. Gyorffy EJ, Bredfeldt JE, Black WC. Transformation of hepatic cell adenoma to hepatocellular carcinoma due to oral contraceptive use. *Ann Intern Med* 1989;110:489-90.
62. Korula J, Yellin A, Kanel G, Campofiori G, Nichols P. Hepatocellular carcinoma coexisting with hepatic adenoma. Incidental discovery after long-term oral contraceptive use. *West J Med* 1991;155:416-8.
63. Tao LC. Oral contraceptive-associated liver cell adenoma and hepatocellular carcinoma. Cytomorphology and mechanism of malignant transformation. *Cancer* 1991;68:341-7.
64. Conti JA, Kemeny N. Type Ia glycogenosis associated with hepatocellular carcinoma. *Cancer* 1992;69:1320-2.
65. Franco LM, Krishnamurthy V, Bali D, Weinstein DA, Arn P, Clary B, et al. Hepatocellular carcinoma in glycogen storage disease type Ia: a case series. *J Inherit Metab Dis* 2005;28:153-62.
66. Gong L, Su Q, Zhang W, Li AN, Zhu SJ, Feng YM. Liver cell adenoma: a case report with clonal analysis and literature review. *World J Gastroenterol* 2006;12:2125-9.
67. Laurent-Puig P, Zucman-Rossi J. Genetics of hepatocellular tumors. *Oncogene* 2006;25:3778-86.
68. Wilkens L, Bredt M, Flemming P, Becker T, Klempnauer J, Kreipe HH. Differentiation of liver cell adenomas from well-differentiated hepatocellular carcinomas by comparative genomic hybridization. *J Pathol* 2001;193:476-82.
69. Nasarek A, Werner M, Nolte M, Klempnauer J, Georgii A. Trisomy 1 and 8 occur frequently in hepatocellular carcinoma but not in liver cell adenoma and focal nodular hyperplasia. A fluorescence in situ hybridization study. *Virchows Arch* 1995;427:373-8.
70. Wilkens L, Bredt M, Flemming P, Schwarze Y, Becker T, Mengel M, et al. Diagnostic impact of fluorescence in situ hybridization in the differentiation of hepatocellular adenoma and well-differentiated hepatocellular carcinoma. *J Mol Diagn* 2001;3:68-73.
71. De Souza AT, Hankins GR, Washington MK, Fine RL, Orton TC, Jirtle RL. Frequent loss of heterozygosity on 6q at the mannose 6-phosphate/insulin-like growth factor II receptor locus in human hepatocellular tumors. *Oncogene* 1995;10:1725-9.
72. Tannapfel A, Busse C, Geissler F, Witzigmann H, Hauss J, Wittekind C. INK4a-ARF alterations in liver cell adenoma. *Gut* 2002;51:253-8.
73. Bach I, Galcheva-Gargova Z, Mattei MG, Simon-Chazottes D, Guenet JL, Cereghini S, et al. Cloning of human hepatic nuclear factor 1 (HNF1) and chromosomal localization of its gene in man and mouse. *Genomics* 1990;8:155-64.
74. Courtois G, Morgan JG, Campbell LA, Fourel G, Crabtree GR. Interaction of a liver-specific nuclear factor with the fibrinogen and alpha 1-antitrypsin promoters. *Science* 1987;238:688-92.
75. Pontoglio M, Barra J, Hadchouel M, Doyen A, Kress C, Bach JP, et al. Hepatocyte nuclear factor 1 inactivation results in hepatic dysfunction, phenylketonuria, and renal Fanconi syndrome. *Cell* 1996;84:575-85.
76. Lee YH, Sauer B, Gonzalez FJ. Laron dwarfism and non-insulin-dependent diabetes mellitus in the Hnf-1alpha knockout mouse. *Mol Cell Biol* 1998;18:3059-68.

77. Shih DQ, Bussen M, Sehayek E, Ananthanarayanan M, Shneider BL, Suchy FJ, et al. Hepatocyte nuclear factor-1alpha is an essential regulator of bile acid and plasma cholesterol metabolism. *Nat Genet* 2001;27:375-82.
78. Shih DQ, Screenan S, Munoz KN, Philipson L, Pontoglio M, Yaniv M, et al. Loss of HNF-1alpha function in mice leads to abnormal expression of genes involved in pancreatic islet development and metabolism. *Diabetes* 2001;50:2472-80.
79. Akiyama TE, Ward JM, Gonzalez FJ. Regulation of the liver fatty acid-binding protein gene by hepatocyte nuclear factor 1alpha (HNF1alpha). Alterations in fatty acid homeostasis in HNF1alpha-deficient mice. *J Biol Chem* 2000;275:27117-22.
80. Bluteau O, Jeannot E, Bioulac-Sage P, Marques JM, Blanc JF, Bui H, et al. Bi-allelic inactivation of TCF1 in hepatic adenomas. *Nat Genet* 2002;32:312-5.
81. Zucman-Rossi J, Jeannot E, Nhieu JT, Scoazec JY, Guettier C, Rebouissou S, et al. Genotype-phenotype correlation in hepatocellular adenoma: new classification and relationship with HCC. *Hepatology* 2006;43:515-24.
82. Bioulac-Sage P, Rebouissou S, Thomas C, Blanc JF, Sa Cunha A, Rullier A, et al. Hepatocellular adenoma subtype classification using molecular markers and immunohistochemistry. *Hepatology* 2007;46:740-8.
83. Laurent-Puig P, Plomteux O, Bluteau O, Zinzindohoue F, Jeannot E, Dahan K, et al. Frequent mutations of hepatocyte nuclear factor 1 in colorectal cancer with microsatellite instability. *Gastroenterology* 2003;124:1311-4.
84. Rebouissou S, Rosty C, Lecuru F, Boisselier S, Bui H, Le Frere-Belfa MA, et al. Mutation of TCF1 encoding hepatocyte nuclear factor 1alpha in gynecological cancer. *Oncogene* 2004;23:7588-92.
85. Rebouissou S, Vasiliu V, Thomas C, Bellanne-Chantelot C, Bui H, Chretien Y, et al. Germline hepatocyte nuclear factor 1alpha and 1beta mutations in renal cell carcinomas. *Hum Mol Genet* 2005;14:603-14.
86. Sjoblom T, Jones S, Wood LD, Parsons DW, Lin J, Barber TD, et al. The consensus coding sequences of human breast and colorectal cancers. *Science* 2006;314:268-74.
87. Rebouissou S, Imbeaud S, Balabaud C, Boulanger V, Bertrand-Michel J, Terce F, et al. HNF1alpha inactivation promotes lipogenesis in human hepatocellular adenoma independently of SREBP-1 and carbohydrate-response element-binding protein (ChREBP) activation. *J Biol Chem* 2007;282:14437-46.
88. Miyoshi Y, Iwao K, Nagasawa Y, Aihara T, Sasaki Y, Imaoka S, et al. Activation of the beta-catenin gene in primary hepatocellular carcinomas by somatic alterations involving exon 3. *Cancer Res* 1998;58:2524-7.
89. de La Coste A, Romagnolo B, Billuart P, Renard CA, Buendia MA, Soubrane O, et al. Somatic mutations of the beta-catenin gene are frequent in mouse and human hepatocellular carcinomas. *Proc Natl Acad Sci U S A* 1998;95:8847-51.
90. Nagafuchi A, Takeichi M. Transmembrane control of cadherin-mediated cell adhesion: a 94 kDa protein functionally associated with a specific region of the cytoplasmic domain of E-cadherin. *Cell Regul* 1989;1:37-44.
91. Micsenyi A, Tan X, Sneddon T, Luo JH, Michalopoulos GK, Monga SP. Beta-catenin is temporally regulated during normal liver development. *Gastroenterology* 2004;126:1134-46.
92. Suksaweang S, Lin CM, Jiang TX, Hughes MW, Widelitz RB, Chuong CM. Morphogenesis of chicken liver: identification of localized growth zones and the role of beta-catenin/Wnt in size regulation. *Dev Biol* 2004;266:109-22.
93. Monga SP, Monga HK, Tan X, Mule K, Padiaditakis P, Michalopoulos GK. Beta-catenin antisense studies in embryonic liver cultures: role in proliferation, apoptosis, and lineage specification. *Gastroenterology* 2003;124:202-16.

94. Benhamouche S, Decaens T, Godard C, Chambrey R, Rickman DS, Moinard C, et al. Apc tumor suppressor gene is the "zonation-keeper" of mouse liver. *Dev Cell* 2006;10:759-70.
95. Cadoret A, Ovejero C, Terris B, Souil E, Levy L, Lamers WH, et al. New targets of beta-catenin signaling in the liver are involved in the glutamine metabolism. *Oncogene* 2002;21:8293-301.
96. Monga SP, Pediaditakis P, Mule K, Stolz DB, Michalopoulos GK. Changes in WNT/beta-catenin pathway during regulated growth in rat liver regeneration. *Hepatology* 2001;33:1098-109.
97. Tan X, Behari J, Cieply B, Michalopoulos GK, Monga SP. Conditional deletion of beta-catenin reveals its role in liver growth and regeneration. *Gastroenterology* 2006;131:1561-72.
98. Takayasu H, Motoi T, Kanamori Y, Kitano Y, Nakanishi H, Tange T, et al. Two case reports of childhood liver cell adenomas harboring beta-catenin abnormalities. *Hum Pathol* 2002;33:852-5.
99. Torbenson M, Lee JH, Choti M, Gage W, Abraham SC, Montgomery E, et al. Hepatic adenomas: analysis of sex steroid receptor status and the Wnt signaling pathway. *Mod Pathol* 2002;15:189-96.
100. Lehmann U, Berg-Ribbe I, Wingen LU, Brakensiek K, Becker T, Klempnauer J, et al. Distinct methylation patterns of benign and malignant liver tumors revealed by quantitative methylation profiling. *Clin Cancer Res* 2005;11:3654-60.
101. Vander Borgh S, Libbrecht L, Blokzijl H, Faber KN, Moshage H, Aerts R, et al. Diagnostic and pathogenetic implications of the expression of hepatic transporters in focal lesions occurring in normal liver. *J Pathol* 2005;207:471-82.
102. Sa Cunha A, Blanc JF, Lazaro E, Mellottee L, Le Bail B, Zucman-Rossi J, et al. Inflammatory syndrome with liver adenomatosis: the beneficial effects of surgical management. *Gut* 2007;56:307-9.
103. Yamagata K, Oda N, Kaisaki PJ, Menzel S, Furuta H, Vaxillaire M, et al. Mutations in the hepatocyte nuclear factor-1alpha gene in maturity-onset diabetes of the young (MODY3). *Nature* 1996;384:455-8.
104. Bacq Y, Jacquemin E, Balabaud C, Jeannot E, Scotto B, Branchereau S, et al. Familial liver adenomatosis associated with hepatocyte nuclear factor 1alpha inactivation. *Gastroenterology* 2003;125:1470-5.
105. Reznik Y, Dao T, Coutant R, Chiche L, Jeannot E, Clauin S, et al. Hepatocyte nuclear factor-1 alpha gene inactivation: cosegregation between liver adenomatosis and diabetes phenotypes in two maturity-onset diabetes of the young (MODY)3 families. *J Clin Endocrinol Metab* 2004;89:1476-80.
106. Chen PJ. Genetic mutation in hepatic adenoma: seeing is believing. *J Hepatol* 2006;45:767-9.
107. Jeannot E, Poussin K, Chiche L, Bacq Y, Sturm N, Scoazec JY, et al. Association of CYP1B1 germ line mutations with hepatocyte nuclear factor 1alpha-mutated hepatocellular adenoma. *Cancer Res* 2007;67:2611-6.
108. Joslyn G, Carlson M, Thliveris A, Albertsen H, Gelbert L, Samowitz W, et al. Identification of deletion mutations and three new genes at the familial polyposis locus. *Cell* 1991;66:601-13.
109. Groden J, Thliveris A, Samowitz W, Carlson M, Gelbert L, Albertsen H, et al. Identification and characterization of the familial adenomatous polyposis coli gene. *Cell* 1991;66:589-600.

110. Bala S, Wunsch PH, Ballhausen WG. Childhood hepatocellular adenoma in familial adenomatous polyposis: mutations in adenomatous polyposis coli gene and p53. *Gastroenterology* 1997;112:919-22.