



HAL
open science

The anatomy of cerebral achromatopsia: A reappraisal and comparison of two case reports.

Paolo Bartolomeo, Anne-Catherine Bachoud-Lévi, Michel Thiebaut de Schotten

► To cite this version:

Paolo Bartolomeo, Anne-Catherine Bachoud-Lévi, Michel Thiebaut de Schotten. The anatomy of cerebral achromatopsia: A reappraisal and comparison of two case reports.: Anatomy of cerebral achromatopsia. *Cortex*, 2014, 56, pp.138-44. 10.1016/j.cortex.2013.01.013 . inserm-00803853

HAL Id: inserm-00803853

<https://inserm.hal.science/inserm-00803853>

Submitted on 23 Mar 2013

HAL is a multi-disciplinary open access archive for the deposit and dissemination of scientific research documents, whether they are published or not. The documents may come from teaching and research institutions in France or abroad, or from public or private research centers.

L'archive ouverte pluridisciplinaire **HAL**, est destinée au dépôt et à la diffusion de documents scientifiques de niveau recherche, publiés ou non, émanant des établissements d'enseignement et de recherche français ou étrangers, des laboratoires publics ou privés.

**The anatomy of cerebral achromatopsia:
A reappraisal and comparison of two case reports**

Paolo Bartolomeo¹⁻³, Anne-Catherine Bachoud-Lévi⁴⁻⁷, Michel Thiebaut de Schotten^{1,8}

¹ Inserm U975; UPMC-Paris6, UMR_S 975; CNRS UMR 7225, Centre de Recherche de l'Institut du Cerveau et de la Moelle épinière, Groupe Hospitalier Pitié-Salpêtrière, 75013 Paris, France

² AP-HP, Groupe Hospitalier Pitié-Salpêtrière, Fédération de Neurologie, 75013 Paris, France

³ Dipartimento di Psicologia, Università Cattolica, 20123 Milano, Italia

⁴ Inserm U955, Equipe 01 Neuropsychologie interventionnelle, Institut Mondor de Recherche Biomédicale, 94000 Créteil, France

⁵ Ecole Normale Supérieure, Institut d'Etudes Cognitives, 75005 Paris, France

⁶ Université Paris Est, Faculté de Médecine, 94000 Créteil, France

⁷ AP-HP, Hôpital Henri Mondor - Albert Chenevier, Centre de référence Maladie de Huntington, 94000 Créteil, France

⁸ Natbrainlab, Department of Forensic and Neurodevelopmental Sciences, Institute of Psychiatry, King's College London, London, UK

Acknowledgement. We acknowledge with thanks the help of Dr Laura Robotham for the English translation of Louis Verrey's paper.

Abstract

Brain damage can produce acquired deficits of color perception, or cerebral achromatopsia. In these patients, lesions tend to overlap on a restricted region in the ventral occipitotemporal cortex, close to the reported locations of the putative V4 complex and to foci of increased BOLD activity related to color perception in normal participants. Unilateral lesions give rise to achromatopsia in the contralateral visual field (hemiachromatopsia). Here we present a partial English translation of the first case report of a hemiachromatopsic patient with detailed anatomical evidence (Madame R, Verrey, 1888), and discuss these results in relation to a more recent case report (Madame D, Bartolomeo et al., 1997) of a patient with two consecutive hemorrhagic lesions in the occipitotemporal regions of the two hemispheres. Strikingly, Madame D developed full-field achromatopsia after the second lesion in the right hemisphere, without having shown any signs of hemiachromatopsia after the first lesion in the left hemisphere. Thanks to the comparison of the reconstructed lesion patterns between the two patients and with the putative location of color-related areas in the human brain, we offer a possible, if speculative, account of this puzzling pattern of anatomo-clinical correlations, based on intra- and inter-hemispheric connectivity.

Key words: Color processing; occipital lobe; temporal lobe; brain damage; achromatopsia

1. Introduction

The question of the neural mechanisms of color processing in the brain has been the source of intense debate during the last century and it is not yet completely settled. The core question of the debate was: is color processed in V1 along with other visual features, or does it require a specialized color center (Zeki, 1990)? Crucial evidence for the existence of brain regions devoted to color processing came from the study of patients who acquired color processing deficits (so-called cerebral achromatopsia), in the context of reasonably preserved other visual abilities such as form vision (although many achromatopsic patients do seem to show at least subtle deficits of form vision, see Bouvier and Engel, 2006). As noted by Zeki (1993), a turning point in the history of cerebral achromatopsia was made by a case report made in 1888 by a Swiss ophthalmologist, Louis Verrey. Verrey described the case of Madame R, who lost her ability to perceive colors (but not shapes) in her right hemifield after a lesion involving the left fusiform and lingual gyri (Verrey, 1888).

Verrey's demonstration of a visual impairment specific to color, with possible sparing of other visual attributes such as form, should have prompted the search for a "color center" in the brain. It generated instead a fierce debate (reviewed by Zeki, 1990, 1993) about the very possibility that such center could exist, contrasted with the alternative hypothesis that color vision could simply be achieved by the striate cortex.

Major contributions to this debate came in the '70s, by the demonstration of color and wavelength selectivity in monkey V4 area (Zeki, 1973), immediately followed by the influential review by Meadows (1974) of 14 human patients with cerebral achromatopsia. Meadows stressed that these patients had a *perceptual* color deficit, as shown by their failure in tests such as those devised by Farnsworth (1947) or Ishihara (1974). Achromatopsia had thus to be distinguished from color agnosia (e.g. Beauvois and Saillant, 1985; Miceli et al., 2001). Patients with color agnosia can perform normally on these perceptual tests, but have impaired knowledge of colors. As a consequence, they are unable to attribute the correct color to objects presented in black and white, or to select the correct crayon to color them. Meadows (1974) also noted that in all the cases he reviewed the lesions involved the fusiform gyrus, the lingual gyrus, or both, and stated that the rarity of the condition may be due to the fact that there must be involvement of areas lying close to the striate cortex; as a consequence, large lesions would destroy the striate cortex and produce homonymous hemianopia or cerebral blindness. Since the publication of Meadows's review, there have been several other reports of acquired color processing deficits, both full-field and concerning a visual hemifield (reviews in Bouvier and Engel, 2006; Damasio et al., 1980; Short and Graff-Radford, 2001; Zeki, 1990).

Of note, the patient described by Short and Graff-Radford (2001) developed right hemiachromatopsia (of which she was not aware) after ischemic damage to nearly all the fusiform gyrus and the lingual gyrus and smaller portions of the parahippocampus and hippocampus in the left hemisphere. The authors summarized 11 other cases of cerebral achromatopsia with neuroimaging, five of whom had bilateral achromatopsia, one right-sided and five left-sided hemiachromatopsia. Thus, although the numbers are necessarily small due to the rarity of the condition, it does not seem to exist any preferential pattern of laterality for the occurrence of hemiachromatopsia.

Even if the existence of areas important for color processing in the fusiform gyrus is now accepted, their location and precise functions are still debated. Neurophysiological and brain imaging studies in the monkey suggest that, after V1, color is handled by several regions located from V4 to the inferotemporal cortex (areas TE and TEO, which includes PIT whose posterior boundary adjoins area V4), rather than by a single entire extrastriate visual area (Conway et al., 2010). Moreover, the relationships between these regions and their putative human homologues remain controversial (Hadjikhani et al., 1998; Zeki, 2003). The collective term V4 complex (Zeki and Bartels, 1999) includes a posterior V4

and a more anterior $V4\alpha$, which according to Zeki and Bartels (1999) corresponds to area V8 described by Hadjikhani et al (1998). More recently, Murphey et al (2008) studied an epileptic patient with an electrode implanted in a more rostral area in the fusiform gyrus (midway between the occipital and temporal poles, see Fig. 1A) in the right hemisphere, using electrical recording and electrical stimulation. The activity recorded in this area was larger for chromatic than for achromatic stimuli, and also depended on the specific hues presented. Electrical stimulation via the electrode evoked artificial colored percept in the absence of visual stimuli. Thus, activity in this midfusiform area seemed directly related to the conscious experience of color in this patient (Murphey et al., 2008). The region examined by Murphey et al (2008) is referred to as midfusiform color center in Fig. 1A.

2. The case of Madame R (Verrey, 1888)

Although a few cases of full-field cerebral achromatopsia had been described earlier (see Zeki, 1990, for review), to the best of our knowledge Verrey's paper is the first detailed report of achromatopsia confined to one visual hemifield, with detailed anatomical localization of the lesion. Given the importance of this case report, which is not currently available outside historical libraries, here we report an English translation of some of the most important passages of Verrey's article.

"Very few cases of hemiachromatopsia have been published to date. From the case of the loss of the two homonymous halves of the visual field of colors, we have arrived at the conclusion of the probable existence, in a region of the cerebral cortex, of a special center dedicated to the chromatic sense. However, a case in which autopsy would confirm this hypothesis was still missing until now. Furthermore, many cases of hemiachromatopsia observed were accompanied by difficulties with reading, ranging from simple dyslexia to a complete word blindness. The case that I describe here and that I have been able to follow for a year has the advantage of being an unambiguous case of hemiachromatopsia. Apart from sight dysfunctions, there was no symptom indicating brain involvement; no aphasia symptoms, no word blindness in its proper sense, no paresis or paralysis of the extremities. Finally, the necroscopic examination of the brain confirmed the generally accepted hypothesis, that of the existence of a cortical center of the chromatic sense, a hypothesis that was however disputed by several authors, and in particular Schneller, who sought to explain these symptoms by a lesion of the chiasma or of the optic tracts. This brain examination led us to discover a pre-existing lesion of the inferior part of the left occipital lobe that was very precisely localized" (page 289).

Verrey then describes the clinical presentation of his patient. "Madame R, 60 years old, from Neufchatel, came to my office for a consultation on the 4th of October in 1887. She complained of no longer being able to read easily, a difficulty she first noticed several weeks ago. After reading several lines, she felt tired and needed to put her book aside; she believed that it would come to be that she would receive a stronger glasses prescription. She associated this weakness of sight with a gastric discomfort that she had experienced near the end of July that same year" (page 290).

In July 1887, Madame R had indeed suffered an episode of acute vertigo with headache and vomiting. On examination, Verrey noted that reading was possible but slowed, especially for the right part of long words. Visual fields were normal, except for a concentric restriction to 15-20° in all directions and a slightly decreased acuity in the right visual field. Form perception was apparently normal. However, colored paper patches of 0.5 cm in diameter, presented along a Foerster perimeter, were systematically perceived as being grey in color in the whole right visual field, whereas they were normally perceived in the left hemifield. The patient's status remained stable from July 1887 until March 1888, when Madame R died as a consequence of a second stroke. Two weeks before the fatal stroke, Verrey was able to re-examine Madame R and confirm the stability of her

condition, except for a possible slight worsening of her visual sensitivity in the right hemifield.

“The 20th of March at 5 in the evening, Madame R suddenly fell and lost consciousness in a store in town where she was doing some errands. She was carried home and her doctor, called in urgency, noted a total left hemiplegia, whole-body anesthesia, violent vomiting, clonic and tonic convulsions of the face and on the right side. After the 21st of March, the convulsions ceased and in the following days the coma became deeper, her respiration stertorous; death in the morning of the 28th” (page 293f).

Autopsy discovered a large, recent hematoma in the right hemisphere, and a smaller, more ancient lesion between the basal portion of the left occipital lobe and the floor of the occipital horn of the left lateral ventricle. The lesion occupied the white matter of the third occipital gyrus and destroyed more or less completely the white matter of the occipital end of the lingual and fusiform gyri (see Fig. 1B), as well as that of the caudal-ventral tip of the cuneus. Ventrally, the lesion approaches the medial surface of the occipital lobe, destroying its deep cortical layers but not reaching the superficial ones. The lesion was an intracerebral hematoma, with a sagittal length of 3.5 cm, 1-cm wide and 1.75-cm high. Verrey concluded that “the center of the chromatic sense would lie in the most inferior part of the occipital lobe, probably in the caudal part of the lingual and fusiform gyri” (p. 298).

3. The case of Madame D (Bartolomeo et al., 1997)

In 1997, Bartolomeo, Bachoud-Lévi and Denes published on *Cortex* the case study of a patient that did not seem to conform to the picture suggested from these cases of hemiachromatopsia, i.e. the existence of bilateral color centers, each competent for color processing in the contralateral hemifield (Bartolomeo et al., 1997). Madame D had two consecutive hemorrhagic lesions in the occipitotemporal cortex and underlying white matter, in roughly mirror-image locations. The patient was a 74-year-old, right-handed retired secretary. She was hospitalized in May 1995 after the sudden occurrence of headaches and visual disturbances. On admission, Madame D presented a right homonymous hemianopia. Her reading was slow and letter-by-letter, with occasional confusion among letters. Writing was preserved. She showed a mild anomia, without any comprehension or repetition deficits, which subsided a few weeks later. CT scan revealed a left occipitotemporal hematoma. An MRI performed in Sep. 1995 showed a reduction in the size of the hematoma, which involved Brodmann's areas 18,19 and 37 (see Fig. 1C). Two months after lesion occurrence, visual fields appeared normal on clinical examinations. Goldman perimetry, however, showed the persistence of a mild paracentral scotoma. This deficit, situated between 38 and 158 for the left eye and 28 and 258 for the right eye (see Fig. 2 in Bartolomeo et al., 1998a), was apparent only with the II test, and thus allowed some residual visual processing. In particular, on clinical testing color naming was entirely normal in the right hemifield. Thus, after the first lesion in the left hemisphere, Madame D had no signs of right hemiachromatopsia on clinical examination; she had a moderate alexia (see Bachoud-Lévi and Bartolomeo, 2003), but kept enjoying painting and remained able to accurately name color patches in either hemifield. Seven months later, while Madame D was recovering from pure alexia, she unfortunately suffered from a second stroke, in an approximately symmetrical location in the right hemisphere (see Fig. 1C). Upon occurrence of the second stroke, Madame D suddenly found herself unable to identify faces, objects and letters, despite reasonably well preserved elementary visual abilities (Bartolomeo et al., 1998a; Bartolomeo et al., 1998b, 2003); importantly, she had also become full-field achromatopsic, and complained to see the world in shades of grey or, later on, in reddish-brown nuances.

Thus, Madame D developed full-field, clinically evident achromatopsia after the second lesion in the right hemisphere, without any clinical signs of right

hemiachromatopsia after the first lesion in the left hemisphere. The 1997 *Cortex* study did not offer a complete account of this “puzzling sequence of events”. The authors noted that their results supported the hypothesis of a critical role of the right hemisphere in color processing, but this putative pattern of hemispheric laterality has not been confirmed by subsequent neuroimaging studies. It is, moreover, inconsistent with the case of Madame R (Verrey, 1888), who had right hemiachromatopsia after a left occipitotemporal lesion.

4. How can similar left hemisphere lesions give rise or not to right hemiachromatopsia?

There is, thus, a stark contrast between Madame R’s right hemiachromatopsia and Madame D’s preserved full-field color vision after lesions in the ventral posterior regions of their left hemisphere. Why should a left hemispheric lesion give such different outcomes in these patients?

A first account might rest on the possibility of individual differences in the hemispheric laterality of the color centers in the brain. According to this hypothesis, the right hemisphere color centers could have been responsible for full-field color processing in Madame D, but not in Madame R. A case report of full-field achromatopsia after an apparently unilateral right hemisphere lesion (Setälä and Vesti, 1994) may indeed suggest that in some individuals color-related areas in the right hemisphere have bilateral competence. This might indeed have been the case for Madame D. As the authors themselves acknowledge, however, “the CT and MRI findings do not totally rule out the existence of bilateral lesions; there may also be an incipient lesion in the left angular or fusiform gyrus, not visible in CT and MRI” (Setälä and Vesti, 1994, p. 35). Furthermore, this possibility does not seem consistent with the remaining available evidence from brain-damaged patients, which suggest that unilateral brain damage can give rise to hemiachromatopsia for the opposite hemifield, without appreciable differences between right and left hemisphere lesions (Short and Graff-Radford, 2001). Moreover, the available data do not suggest the possibility of an atypical pattern of hemispheric laterality for either Madame R or Madame D (who was right-handed).

A second possibility is that the left hemisphere lesions damaged different anatomical systems in the two patients. A precise test of this hypothesis would require state-of-art images of the lesions of Madame R and Madame D, which are unfortunately not available. However, based on the autopsy report and figure provided by Verrey (1888) for Madame R, and on CT and clinical MRI scans obtained for Madame D, we reconstructed their lesions on standardized brain slices, shown in Figure 1 together with the location of areas crucial for color processing.

5. Methods

Mapping of the lesions was performed by using MRICron (<http://www.mccauslandcenter.sc.edu/mricro/mricron>). For each patient, we rotated the Colin27 template (Holmes et al., 1998) provided in MRICron from the MNI space to the orientation of sectional drawings for Madame R (Verrey, 1888), and of individual clinical MRI scans for Madame D (Bartolomeo et al., 1998a; Bartolomeo et al., 1997). The lesion was then drawn on the reoriented template and subsequently taken back to the MNI space using the inverse rotation (see Doricchi and Tomaiuolo, 2003).

The ventral part of V4 (hOC4v, Rottschy et al., 2007) and the subdivisions of the fusiform gyrus (FG1 and FG2, Caspers et al., 2012) were obtained from recent post-mortem cytoarchitectonic atlases (SPM Anatomy Toolbox V2, <http://www.fz-juelich.de>) and overlapped on the Colin 27 template. These maps were thresholded in order to only show voxels with a probability superior to 50% (above the chance level of being in the given area for a given voxel).

MNI coordinates for area V8 and the midfusiform color area were respectively extracted from previous functional MRI study (Hadjikhani et al., 1998) and direct electrical recording and stimulation in an epileptic patient (Murphey et al., 2008), and plotted in the Colin27 template. Note that when areas were reported in Talairach coordinates we used the Yale non-linear MNI 2 Talairach conversion (<http://www.bioimagesuite.org/Mni2Tal/index.html>) in order to obtain MNI coordinates.

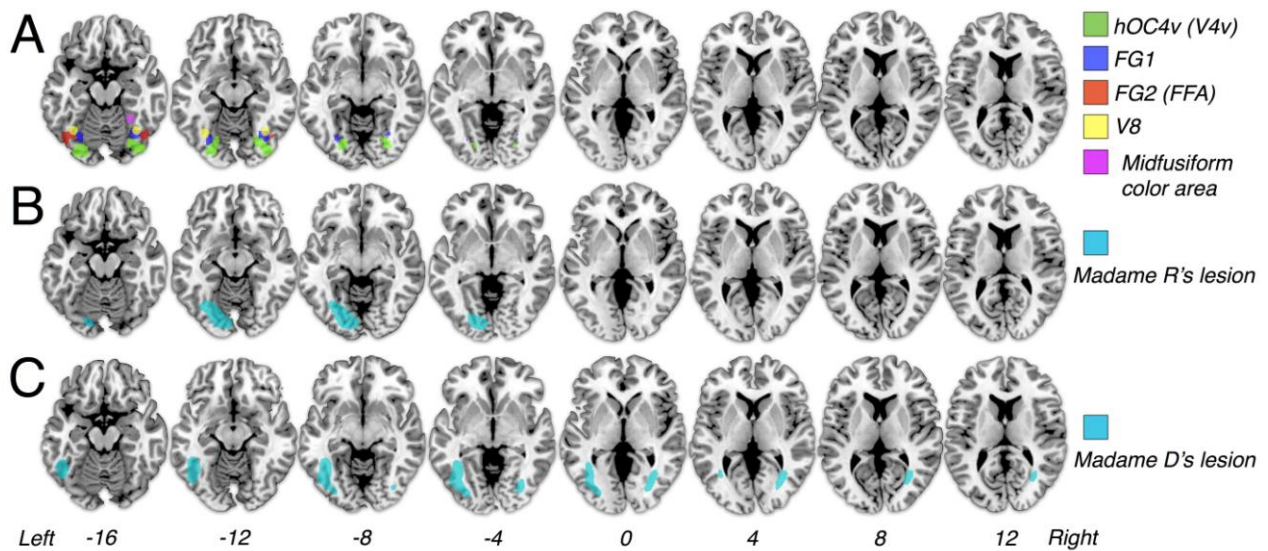


Figure 1: A. Color-related areas in the human brain. Cytoarchitectonic areas hOC4v (Rottschy et al., 2007), FG1, FG2 (Caspers et al., 2012), the functionally activated area V8 (Hadjikhani et al., 1998) and the midfusiform color center explored in the right hemisphere of an epileptic patient by Murphey et al (2008). B. Reconstruction of Madame R's lesion. C. Reconstruction of Madame D's lesion.

6. Results

The results of the anatomical analysis are displayed in Figure 1. Inspection of the figure suggests that Madame R's lesion encroached directly upon areas crucial for color processing (V4/V8). This provides a straightforward explanation for her hemiachromatopsia, precisely along the lines suggested by Verrey in the original case report (Verrey, 1888). On the other hand, Fig. 1 also indicates that Madame D's first, left-hemisphere lesion did not damage directly the color processing regions. However, as suggested by the predominant involvement of the white matter nearby these regions, Madame D's first lesion could have disconnected these posterior color-processing areas from more anterior color-related regions, such as the midfusiform color center putatively implicated in conscious color experience (Murphey et al., 2008). Nevertheless, the callosal connections of V4 might have prevented Madame D's first lesion from producing hemiachromatopsia. It is well known that the callosal connections of V4 (Fig. 2) are much more widespread than those of V1 and V2, which are limited to the representation of the vertical meridian (Clarke and Miklossy, 1990; Zeki, 1990).

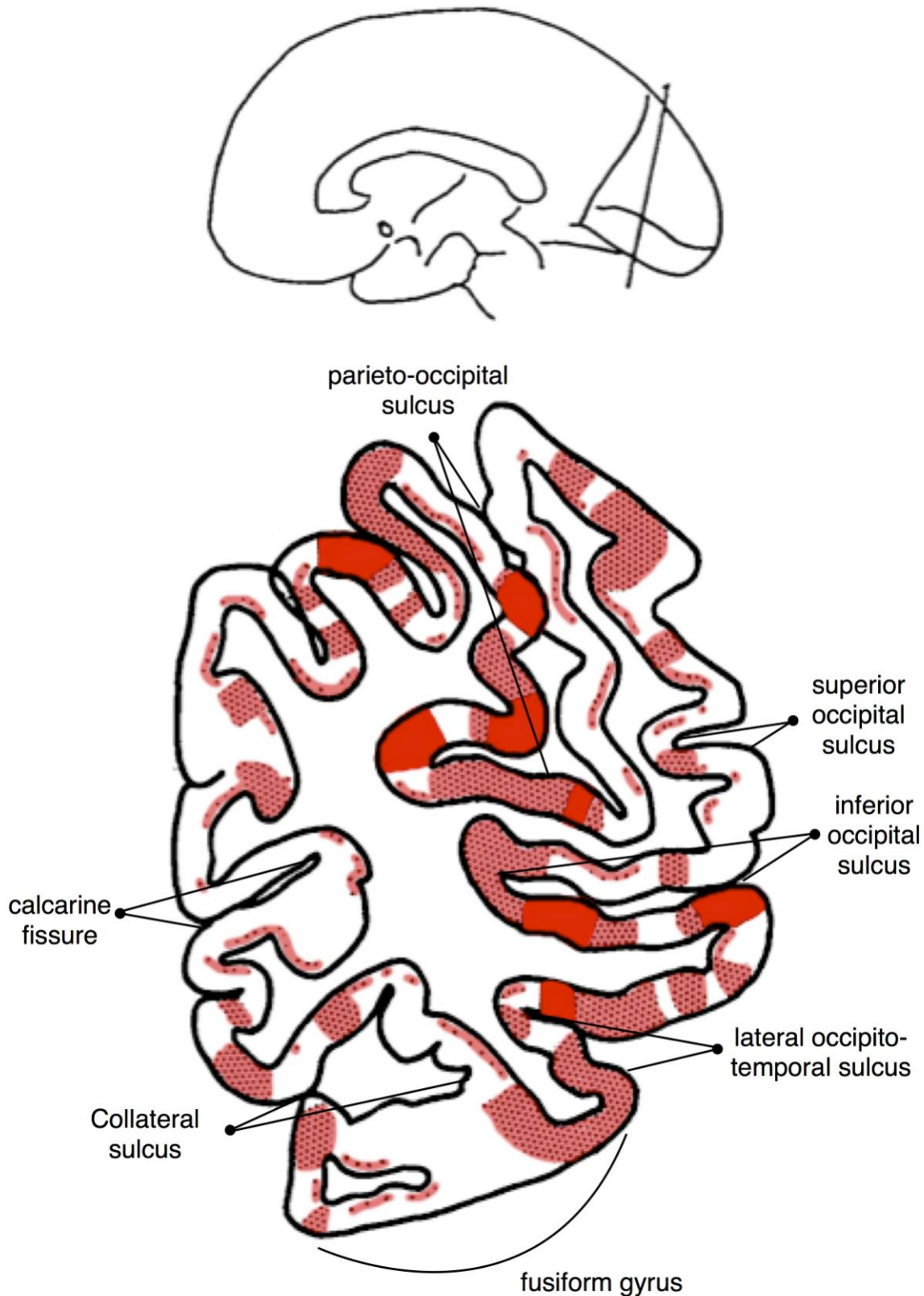


Figure 2: Coronal view of the callosal connections (in red) of V4 (modified from Clarke and Miklosy, 1990). Post-mortem studies localized V4 in the collateral sulcus overlapping with the occipital portion of the fusiform gyrus in humans (Rottschy et al., 2007). Following degenerating axons from occipital lobes of six human brains with unilateral occipital infarctions, Clarke and Miklosy (1990) were able to describe the projections of the corpus

callosum on a region of the fusiform gyrus which presumably contains the human analogue of the V4 complex.

Color-related information might thus have traveled from V1 to V4 in the left hemisphere and then crossed to the right hemisphere thanks to V4 callosal connections, with consequent full-field conscious color experience. Madame D's second lesion appears, instead, to have damaged at least partially the right hemisphere V4 (Fig. 1C), thus impairing this pathway, with consequent full-field achromatopsia.

7. Discussion

Color processing in the brain proceeds along multiple stages, starting from the activity of L, M, and S cones in the retina to color-opponent neurons in the lateral geniculate nucleus and V1 (Conway et al., 2010), to hue maps with color constancy in V2 and V4 (Roe et al., 2012) and finally more "cognitive" aspects in more anterior areas in the temporal cortex. These high-level, cognitive aspects include elements of color knowledge (i.e., knowledge about prototypical object colors, Miceli et al., 2001) and perhaps the possibility of full conscious experience of color (Murphey et al., 2008).

The present reappraisal of two published cases of acquired color deficits contributes to our understanding of the role of the human homologue of V4 to color perception, by showing that direct damage to the putative human localization of the V4 complex is correlated to a perceptual color processing deficit in the contralateral hemifield (Verrey, 1888), and resolves the apparently contradictory findings, obtained in another patient (Bartolomeo et al., 1997), that occipitotemporal damage in the left hemisphere did not produce hemiachromatopsia, whereas subsequent damage to the right hemisphere was able to determine full-field achromatopsia.

Note, however, that experimental evidence from intra-operative stimulation (Lee et al., 2000) and studies of visual hallucinations (ffytche et al., 1998) suggest that V4 might have in itself a role in conscious processing of color (Zeki, 2005). If so, then the reason why Madame D did not develop hemi-achromatopsia after her left hemisphere lesion is because V4 was not affected. It remains, however, difficult to explain why Madame D developed full field achromatopsia after her second lesion to right V4, given that left V4 was unaffected throughout. In addition to the above-mentioned possibility of an individual right-hemisphere dominance for color processing, one might posit changes in input to left V4 at initial presentation, as implied by the transient hemianopia. Perhaps during the seven months prior to the second lesion Madame D was relying on callosal connections from right V4 to left V4 for full field colour vision. If, however, conscious color experience does not require solely the activity of V4, but also its integration with more rostral regions such as the midfusiform color area, then our present hypothesis seems to account for most of the available evidence.

Two limits of the present study must be acknowledged. First, it is difficult to precisely estimate the location and extent of the brain lesions of these patients in the absence of high-resolution neuroimaging data. Second, there are still many uncertainties concerning the homologies between monkey and human brain in these occipitotemporal regions. Despite these problems, the present results contribute to confirm the importance of the human homologue of V4 in color processing, as well as the putative role of inter-hemispheric interactions between these regions. It is likely from the present data that a lesion of V4 can profoundly impair the visual experience of color, perhaps by depriving more anterior areas of crucial input. Thus, rather than a single "special center dedicated to the chromatic sense" (Verrey, 1888), a complex network of processing streams in the occipitotemporal cortex seems to be essential to several aspects of color-related cognition.

Reviewing the history of cerebral achromatopsia, Semir Zeki noted that "the optic radiations and the white matter in general were to come to the rescue of many a faltering

argument" (Zeki, 1993, page 47) during the debate about the color centers in the brain. In the present comparison between the cases of Madame R and Madame D, however, simple consideration of cortical lesion location did not permit to reach a satisfactory account of the dramatic differences between the consequences of their brain lesions. On the other hand, by taking into account white matter pathways, an approach sometimes defined as *hodotopic* (see Catani and ffytche, 2005), it was possible to articulate a more plausible, if speculative, explanation of an otherwise mysterious pattern of lesion-symptom mapping.

8. References

- Bachoud-Lévi AC, and Bartolomeo P. Mechanisms of pure alexia: Spatially-based impairment, letter identification deficit, or both? *Neurocase* 9 (2): 164-176, 2003.
- Bartolomeo P, Bachoud-Lévi AC, de Gelder B, Denes G, Dalla Barba G, Brugières P, and Degos JD. Multiple-domain dissociation between impaired visual perception and preserved mental imagery in a patient with bilateral extrastriate lesions. *Neuropsychologia* 36 (3): 239-249, 1998a.
- Bartolomeo P, Bachoud-Lévi AC, Degos JD, and Boller F. Disruption of residual reading capacity in a pure alexic patient after a mirror-image right hemispheric lesion. *Neurology* 50 (1): 286-288, 1998b.
- Bartolomeo P, Bachoud-Lévi AC, Degos JD, and Boller F. Right hemisphere contributions to residual reading in pure alexia: Evidence from a patient with subsequent bilateral strokes. In: Zaidel E, and Iacoboni M (Eds.), *The Parallel Brain: The Cognitive Neuroscience of the Corpus Callosum*. The MIT Press: Cambridge, MA, 2003. pp. 500-506.
- Bartolomeo P, Bachoud-Lévi AC, and Denes G. Preserved imagery for colours in a patient with cerebral achromatopsia. *Cortex* 33 (2): 369-378, 1997.
- Beauvois MF, and Saillant B. Optic aphasia for colours and colour agnosia: A distinction between visual and visuo-verbal impairments in the processing of colours. *Cognitive Neuropsychology* 2 (1): 1-48, 1985.
- Bouvier SE, and Engel SA. Behavioral deficits and cortical damage loci in cerebral achromatopsia. *Cerebral Cortex* 16 (2): 183-191, 2006.
- Caspers J, Zilles K, Eickhoff SB, Schleicher A, Mohlberg H, and Amunts K. Cytoarchitectonical analysis and probabilistic mapping of two extrastriate areas of the human posterior fusiform gyrus. *Brain Structure and Function*, 2012.
- Catani M, and ffytche DH. The rises and falls of disconnection syndromes. *Brain* 128 (Pt 10): 2224-2239, 2005.
- Clarke S, and Miklossy J. Occipital cortex in man: organization of callosal connections, related myelo- and cytoarchitecture, and putative boundaries of functional visual areas. *The Journal of comparative neurology* 298 (2): 188-214, 1990.
- Conway BR, Chatterjee S, Field GD, Horwitz GD, Johnson EN, Koida K, and Mancuso K. Advances in Color Science: From Retina to Behavior. *Journal of Neuroscience* 30 (45): 14955-14963, 2010.
- Damasio A, Yamada T, Damasio H, Corbett J, and McKee J. Central achromatopsia: Behavioral, anatomic, and physiologic aspects. *Neurology* 30: 1064-1071, 1980.
- Doricchi F, and Tomaiuolo F. The anatomy of neglect without hemianopia: a key role for parietal-frontal disconnection? *NeuroReport* 14 (17): 2239-2243, 2003.
- Farnsworth D. *Farnsworth dichotomous test for colour-blindness - panel D-15*. The Psychological Corporation: New York, 1947.
- ffytche DH, Howard RJ, Brammer MJ, David A, Woodruff P, and Williams S. The anatomy of conscious vision: an fMRI study of visual hallucinations. *Nat Neurosci* 1 (8): 738-742, 1998.
- Hadjikhani N, Liu AK, Dale AM, Cavanagh P, and Tootell RB. Retinotopy and color sensitivity in human visual cortical area V8. *Nat Neurosci* 1 (3): 235-241, 1998.
- Holmes CJ, Hoge R, Collins L, Woods R, Toga AW, and Evans AC. Enhancement of MR images using registration for signal averaging. *J Comput Assist Tomogr* 22 (2): 324-333, 1998.
- Ishihara S. *Tests for colour-blindness*. Kanehara Shup: Tokyo, 1974.
- Lee HW, Hong SB, Seo DW, Tae WS, and Hong SC. Mapping of functional organization in human visual cortex: electrical cortical stimulation. *Neurology* 54 (4): 849-854, 2000.

- Meadows JC. Disturbed perception of colours associated with localized cerebral lesions. *Brain* 97: 615-632, 1974.
- Miceli G, Fouch E, Capasso R, Shelton JR, Tomaiuolo F, and Caramazza A. The dissociation of color from form and function knowledge. *Nature Neuroscience* 4 (6): 662-667, 2001.
- Murphey DK, Yoshor D, and Beauchamp MS. Perception matches selectivity in the human anterior color center. *Current Biology* 18 (3): 216-220, 2008.
- Roe AW, Chelazzi L, Connor CE, Conway BR, Fujita I, Gallant JL, Lu H, and Vanduffel W. Toward a unified theory of visual area V4. *Neuron* 74 (1): 12-29, 2012.
- Rottschy C, Eickhoff SB, Schleicher A, Mohlberg H, Kujovic M, Zilles K, and Amunts K. Ventral visual cortex in humans: Cytoarchitectonic mapping of two extrastriate areas. *Human Brain Mapping* 28 (10): 1045-1059, 2007.
- Setälä K, and Vesti E. Acquired cerebral achromatopsia: A case report. *Neuro-ophthalmology* 14 (1): 31-36, 1994.
- Short RA, and Graff-Radford NR. Localization of hemiachromatopsia. *Neurocase* 7 (4): 331-337, 2001.
- Verrey L. Hémiachromatopsie droite absolue. Conservation partielle de la perception lumineuse et des formes. Ancien kyste hémorragique de la partie inférieure du lobe occipital gauche. *Arch. Ophthalmol. (Paris)* 8: 289-300, 1888.
- Zeki S. Colour coding in rhesus monkey prestriate cortex. *Brain Res* 53 (2): 422-427, 1973.
- Zeki S. A century of cerebral achromatopsia. *Brain* 113: 1721-1777, 1990.
- Zeki S. *A Vision of the Brain*. Blackwell Scientific Publications: Oxford, 1993.
- Zeki S. Improbable areas in the visual brain. *Trends Neurosci* 26 (1): 23-26, 2003.
- Zeki S. The Ferrier Lecture 1995 behind the seen: the functional specialization of the brain in space and time. *Philos Trans R Soc Lond B Biol Sci* 360 (1458): 1145-1183, 2005.
- Zeki S, and Bartels A. The clinical and functional measurement of cortical (in)activity in the visual brain, with special reference to the two subdivisions (V4 and V4 alpha) of the human colour centre. *Philosophical Transactions of the Royal Society B: Biological Sciences* 354 (1387): 1371-1382, 1999.