

New biomarkers in T-cell lymphomas.

Bettina Bisig, Philippe Gaulard, Laurence De Leval

► **To cite this version:**

Bettina Bisig, Philippe Gaulard, Laurence De Leval. New biomarkers in T-cell lymphomas.. Best Practice and Research: Clinical Haematology, Elsevier, 2012, 25 (1), pp.13-28. <10.1016/j.beha.2012.01.004>. <inserm-00693167>

HAL Id: inserm-00693167

<http://www.hal.inserm.fr/inserm-00693167>

Submitted on 2 May 2012

HAL is a multi-disciplinary open access archive for the deposit and dissemination of scientific research documents, whether they are published or not. The documents may come from teaching and research institutions in France or abroad, or from public or private research centers.

L'archive ouverte pluridisciplinaire **HAL**, est destinée au dépôt et à la diffusion de documents scientifiques de niveau recherche, publiés ou non, émanant des établissements d'enseignement et de recherche français ou étrangers, des laboratoires publics ou privés.

New biomarkers in T-cell lymphomas

Bettina Bisig^{1,2} MD, Philippe Gaulard^{3,4,5} MD, Laurence de Leval^{1,2,6,*} MD PhD

¹Department of Pathology, Centre Hospitalier Universitaire Sart Tilman, Liège, Belgium;

²Laboratory of Experimental Pathology, Groupe Interdisciplinaire de Génomprotéomique Appliquée (GIGA) – Research, University of Liège, Belgium;

³Department of Pathology, Assistance Publique – Hôpitaux de Paris (AP-HP), Groupe hospitalier Henri Mondor – Albert Chenevier, Créteil, France;

⁴Institut National de la Santé et de la Recherche Médicale (INSERM), Unité U955, Créteil, France;

⁵Université Paris-Est, Faculté de Médecine, Créteil, France;

⁶Institute of Pathology, Centre Hospitalier Universitaire Vaudois, Lausanne, Switzerland

* Corresponding author

Addresses :

Bettina Bisig, Department of Pathology, CHU Sart Tilman, B-4000 Liège, Belgium. Tel. ++32 4 366 24 10. Fax : ++32 4 366 29 19. E-mail : bettina.bisig@ulg.ac.be

Philippe Gaulard, Department of Pathology, Hôpital Henri Mondor, F-94010 Créteil, France. Tel.: +33 1 49 81 27 43. Fax : +33 1 49 81 27 33. E-mail: philippe.gaulard@hmn.aphp.fr

Laurence de Leval, Institute of Pathology, CHUV, CH-1011 Lausanne, Switzerland. Tel.: ++41 21 314 71 94. Fax: ++41 21 314 72 05. E-mail: laurence.deleval@chuv.ch

Abstract

Peripheral T-cell lymphomas (PTCLs) are heterogeneous and uncommon malignancies characterized by an aggressive clinical course and a mostly poor outcome with current treatment strategies. The recent genome-wide molecular characterization of several entities has provided novel insights into their pathobiology and led to the identification of new biomarkers with diagnostic, prognostic or therapeutic implications for PTCL patients. Cell lineage and differentiation antigens (markers of $\gamma\delta$ or NK lineage, of cytotoxicity, of follicular helper T cells) reflect the tumour's biological behaviour, and their detection in tissue samples may refine the diagnostic and prognostic stratification of the patients. Previously unrecognized gene rearrangements are being discovered (*ITK-SYK* translocation, *IRF4/MUM1* and *DUSP22* rearrangements), and may serve as diagnostic genetic markers. Deregulated molecules within oncogenic pathways (NF- κ B, Syk, PDGFR α) and immunoreactive cell-surface antigens (CD30, CD52) have been brought to the fore as potential targets for guiding the development of novel therapies.

Key words

peripheral T-cell lymphomas; biomarkers; translocations; gene expression profiling; targeted therapy; prognosis

Introduction

Malignancies derived from mature T cells and natural killer (NK) cells, collectively referred to as peripheral T-cell lymphomas (PTCLs), constitute a heterogeneous group of uncommon neoplasias, accounting altogether for less than 15% of all non-Hodgkin lymphomas worldwide [1]. Although the aetiology of most PTCL subtypes is poorly understood, infections by the Epstein-Barr virus (EBV) or the human T-lymphotropic virus type 1 (HTLV-1) contribute to the development of a few entities more prevalent in Asia and Latin America where these viruses are endemic [1, 2].

The pathological diagnosis of PTCLs is often challenging, owing to a broad morphologic and immunophenotypic variability within and significant overlaps across distinct entities; and to the lack – with few exceptions – of specific, entity-defining, genetic alterations. Conversely, the clinical features are critical to the classification of PTCLs, which are listed according to their predominant site of involvement as disseminated/leukaemic, extranodal, cutaneous or nodal entities (Table 1) [2].

With few exceptions, PTCLs almost uniformly exhibit resistance to standard chemotherapy regimens and have a poor clinical outcome [3, 4]. The 5-year overall survival (OS) rate is as low as 30% for peripheral T-cell lymphoma, not otherwise specified (PTCL, NOS) and angioimmunoblastic T-cell lymphoma (AITL), contrasting with 70% for anaplastic lymphoma kinase-positive anaplastic large cell lymphoma (ALK+ ALCL). Most extranodal and leukaemic subtypes have an even more aggressive clinical course, with a 5-year OS ranging between 7% and 32% [3]. More effective treatment modalities are clearly needed.

Over the past years, novel insights have been gained into the pathobiology of PTCLs (reviewed in [5, 6]). Importantly, genome-wide molecular characterization of several PTCL entities has consented to refine their diagnostic criteria and reveal novel diagnostic biomarkers [7-11]. The delineation of molecular subgroups has been shown to be of interest for the prognostic stratification of patients within some PTCL categories [10, 12-14]. By comparison with the molecular signatures of benign T-cell populations, gene expression analyses have also contributed to the identification of oncogenic pathways, guiding the development of novel targeted therapies [11, 15-18]. Moreover, previously unrecognized recurrent genetic alterations have been recently described [19-21]. Concurrently, a number of immunotherapeutic agents are being developed or under investigation, targeting cell-surface molecules that are variably expressed across PTCL entities (reviewed in [22, 23]).

This review will focus on the most relevant of these new molecular biomarkers, by virtue of their diagnostic, prognostic or therapeutic implications (summarized in Table 2).

Lineage / differentiation markers

While ascribing lymphoid neoplasms to a normal cell counterpart is a major principle for their classification according to the World Health Organization (WHO) [2], yet many PTCL entities do not conform to this criterion as their cellular origin remains poorly characterized (Fig. 1). This is likely due to the complexity of normal T-cell differentiation, characterized by marked functional diversity but also evidence of functional overlap and plasticity between T- and NK-cell subsets. These features might in turn account for frequent aberrations and a pronounced variability in the phenotype within distinct PTCL categories (reviewed in [24-26]). Over the past years it has become clear that cell lineage or differentiation traits represent major determinants of the biology of these neoplasms, relevant to their classification and prognosis, and significant progresses have been achieved in the identification of the cellular derivation of several PTCL entities.

$\gamma\delta$ T-cell lineage

Among normal mature T cells, a major distinction is based on the structure of the T-cell receptor (TCR), composed of either the $\alpha\beta$ chains or the $\gamma\delta$ chains. While $\alpha\beta$ T cells (including CD4+ (mainly helper) and CD8+ (mainly cytotoxic) subpopulations) belong to the adaptive immune system featuring specificity and memory, $\gamma\delta$ T cells participate in the innate immune responses as a first-line defence (together with NK cells) and are mostly CD4-/CD8- cells located within the skin, the mucosae and the spleen [27].

Reflecting the paucity and distribution of normal $\gamma\delta$ T cells, PTCLs derived from T cells of the $\gamma\delta$ lineage ($\gamma\delta$ PTCLs) comprise a few rare, highly aggressive, extranodal

malignancies, with peculiar clinicopathologic features reflecting their cell of origin [2, 27, 28]. Hepatosplenic T-cell lymphoma (HSTL) is the prototype and the first entity initially defined by its $\gamma\delta$ derivation (although subsequently rare cases with an $\alpha\beta$ phenotype and a similar clinicopathologic presentation were reported [29]). HSTL occurs predominantly in young male adults and may arise in the setting of chronic immune suppression or prolonged antigenic stimulation, particularly following long-term immunosuppressive therapy for solid organ transplantation or in children treated by azathioprine and infliximab for Crohn's disease. The disease typically presents with hepatosplenomegaly, thrombocytopenia and systemic symptoms. Histopathology reveals a predominantly intrasinusoidal involvement of the spleen, liver and bone marrow by monotonous medium-sized T cells with a non-activated cytotoxic phenotype (see below) [30]. Genetically most cases harbour an isochromosome 7q [31]. The clinical course of the disease is rapidly progressive with an extremely dismal 5-year OS of only 7% [3].

Among cutaneous T-cell lymphomas, it has been recognized that entities with a $\gamma\delta$ phenotype share an aggressive behaviour and are associated with a significantly shorter survival when compared with their $\alpha\beta$ counterparts [32, 33], and hence primary cutaneous $\gamma\delta$ PTCLs, irrespective of the histological pattern, are grouped under a single entity [2]. Similar cases presenting in mucosal sites may possibly be related [2, 33, 34]. In contrast with HSTL, these non-hepatosplenic muco-cutaneous $\gamma\delta$ PTCLs carry an activated cytotoxic phenotype (see below), and are clinically and morphologically more heterogeneous [28, 31]. Accordingly, recent GEP studies have evidenced that, while HSTLs feature a distinct and homogeneous molecular signature, non-hepatosplenic $\gamma\delta$ PTCLs do not spontaneously cluster together in unsupervised expression analyses [35, 36]. This clinicopathologic and molecular heterogeneity favours the existence of several

biologically distinct disease entities within the spectrum of non-hepatosplenic $\gamma\delta$ PTCLs, encouraging the study of larger series of samples from different anatomic sites, to gain new insights into their pathobiological relationship and refine their classification [28, 31, 35-37].

Until recently, expression of the $\gamma\delta$ TCR in lymphoma samples could only be assessed by flow cytometry or by immunohistochemistry on frozen sections. As a consequence, in routinely processed fixed material the $\gamma\delta$ phenotype was extrapolated from the negativity for the $\alpha\beta$ TCR (recognized by the anti- β F1 antibody) [31]. Monoclonal antibodies detecting the constant region of the TCR γ chain (C γ M1) or TCR δ chain (TCR δ 1) in paraffin sections have now been made available [37, 38], and will valuably assist in the identification of these rare – and probably hitherto underdiagnosed – malignancies [28].

NK-cell receptors (NKRs)

Although immunohistochemistry can be employed to determine the $\alpha\beta$ versus $\gamma\delta$ lineage of a T-cell population, it is not sufficient to assess its clonality. Instead, demonstration of T-cell monoclonality requires genetic testing, most commonly PCR assays establishing the rearrangement patterns of the *TCR* genes in the sample of interest. Conversely, *TCR* testing does not provide any information in NK-cell proliferations, since NK cells do not rearrange their *TCR* genes. In that setting, clonality analysis can be performed indirectly by immunophenotyping of cell-surface markers such as NK-cell receptors (NKRs). The latter include killer cell immunoglobulin-like receptors (KIRs), which recognize major histocompatibility complex (MHC) class I molecules and provide signals that regulate NK-cell functions. Since KIRs comprise multiple isoforms, a restricted KIR repertoire

can be used as a surrogate marker of clonal cellular expansion. This tool has proven to be particularly useful in the evaluation of NK-cell lymphocytosis by flow cytometry, for the differential diagnosis between reactive conditions and neoplastic diseases such as chronic lymphoproliferative disorders of NK cells (CLPD-NKs) [39, 40]. Restricted KIR expression has also been demonstrated in extranodal NK/T-cell lymphomas (NKTCLs) by immunohistochemistry on frozen sections [41].

In addition to NK-cell lymphoproliferations, T-cell large granular lymphocytic leukaemia (T-LGL) and subsets of T-cell-derived extranodal cytotoxic PTCLs (i.e. HSTL and enteropathy-associated T-cell lymphoma (EATL)) have been shown to share the expression of NKRs [39, 42, 43], reflecting the close functional relationship between NK cells and cytotoxic T cells.

Interestingly, a peculiar KIR – namely CD158k/KIR3DL2 – is aberrantly expressed by Sézary cells, and the determination of circulating CD4+CD158k+ cells by flow cytometry has been proposed as a tool for the evaluation and follow-up of patients with Sézary syndrome [44, 45].

Cytotoxic markers

Cytotoxicity is mediated through the release of cytotoxic granules-associated molecules, including perforin and several granzymes, and is a property shared by functional NK cells, $\gamma\delta$ T cells and CD8+ cytotoxic T cells (of the $\alpha\beta$ lineage), as well as several PTCL entities (summarized in Table 3) [2]. In addition to providing a mechanistic explanation to some manifestations of these neoplasms (e.g. preferential involvement of extranodal sites, mirroring the tropism of normal $\gamma\delta$ T cells and NK cells; and common prominent

intratumoral apoptosis), the demonstration of a cytotoxic immunophenotype may be of diagnostic or prognostic significance [2, 10, 46, 47].

Perforin, granzyme B and T-cell intracellular antigen-1 (TIA-1) represent the most useful cytotoxic markers for diagnostic purposes, and can routinely be identified by immunohistochemistry on tissue sections. While TIA-1 is detected in both resting (non-activated) and activated cytotoxic cells, the expression of perforin and granzyme B is a feature of activated cytotoxic cells [48]. Granzyme H, recently validated as a marker of NKTCL, can be detected by immunohistochemistry and may thus represent a novel helpful marker assisting in the differential diagnosis between NKTCLs and other cytotoxic PTCLs [11].

Within the heterogeneous PTCL, NOS category, Iqbal *et al.* identified a distinct molecular subgroup, characterized by the upregulation of numerous cytotoxicity-related genes and by a significant enrichment in transcripts associated with normal activated CD8+ T cells [10]. Noteworthy, the patients within this group had an inferior survival compared to the other PTCL, NOS cases, in line with previous immunohistochemistry-based reports [46, 47].

Follicular helper T (T_{FH})-cell markers

The majority of PTCLs display a CD4+ immunophenotype, with a molecular signature closer to activated than to resting T cells [17]. CD4+ T cells comprise several functionally different subsets, including the recently characterized follicular helper T cells (T_{FH} cells), which have gained increasing interest as the critical regulators of antigen-specific B-cell immune responses [49, 50]. T_{FH} cells normally reside in the light zone of reactive germinal centres, and differ from other T-cell subsets by the expression

of distinctive transcription factors, cell-surface molecules and cytokines (T_{FH}-cell markers, see below) [51, 52].

An essential advance in the histogenetic understanding of PTCLs was the recent identification of the T_{FH} cell as the cell of origin of AITL, a distinct entity amid PTCLs [7, 10, 16]. AITL is defined by a constellation of clinical and pathologic features. The patients typically present in their 6th or 7th decade with generalized lymphadenopathy, hepatosplenomegaly, B symptoms, skin rash and/or pruritus, and polyclonal hypergammaglobulinemia. Peculiar histopathologic features include neoplastic clear cells showing an aberrant expression of CD10, a conspicuous polymorphic reactive infiltrate, prominent arborizing vessels, increased follicular dendritic cell meshworks, and expansion of EBV-infected B blasts (reviewed in [25, 53]). In addition, as a corollary of – and initial hint to – their T_{FH}-cell derivation, AITL tumour cells characteristically express several T_{FH}-cell markers, including the CXCL13 chemokine [54-56], the cell-surface molecules PD-1/CD279 [56, 57], ICOS [58] and CD200 [59], the adaptor molecule SAP [60], and the transcription factors Bcl-6 [61] and c-Maf [62]. In practice, the immunohistochemical demonstration of a T_{FH}-like phenotype is a very helpful adjunct to support the diagnosis of AITL, particularly in morphologically challenging cases [53]. Noteworthy, a small subset of nodal lymphomas classified as PTCLs, NOS also appears to express T_{FH}-cell markers and may harbour a few AITL-like histologic features, questioning the criteria that define the borders between these entities [7, 63, 64].

Interestingly, screening of PTCLs has evidenced the expression of T_{FH}-cell markers in other PTCL subsets [65]. The latter comprise most PTCLs, NOS featuring a follicular growth pattern, i.e. the follicular variant of PTCL, NOS (PTCL-F) of which a subset harbours the t(5;9)/*ITK-SYK* translocation (see below) [64, 66, 67]; and primary

cutaneous CD4+ small/medium-sized pleomorphic T-cell lymphoma [68], a provisional entity within primary cutaneous PTCLs, often presenting as a solitary skin nodule in the head and neck area with an indolent clinical course [69].

Cell-surface markers

Along the lines of the anti-CD20 monoclonal antibody rituximab, which has revolutionized the treatment and outcome of B-cell lymphoma patients, efforts have been undertaken to develop therapeutic antibodies targeting cell-surface molecules in PTCLs [22]. Among these, CD30 and CD52 have so far revealed as the most promising targets.

CD30

CD30 (TNFRSF8), a transmembrane glycoprotein of the tumour necrosis factor receptor (TNFR) superfamily, is involved in signal transduction via the activation of the NF- κ B pathway and the mitogen-activated protein kinases (MAPKs), ultimately modulating cell growth, proliferation and apoptosis [70]. In reactive lymphoid tissues, CD30 is a non-lineage-specific activation marker expressed by scattered B and T immunoblasts. Among PTCLs, strong and homogeneous CD30 expression is a hallmark feature of ALCLs, irrespective of their *ALK* gene status, and of the primary cutaneous CD30+ T-cell lymphoproliferative disorders. A subset of cases in virtually all PTCL entities may also express CD30 but at variable and generally lower levels [2, 71].

The CD30 antigen has recently emerged as a novel therapeutic target in patients with CD30+ lymphoproliferations including ALCLs. Indeed, although most ALK+ ALCLs can be cured with first-line chemotherapy regimens, approximately 10-30% of patients are refractory or relapse after initial remission. Some of these patients may respond to salvage chemotherapy and autologous stem cell transplantation, but those who progress have a poor prognosis and treatment options at this stage are limited. ALK-

ALCL, on the other hand, is associated with a more aggressive clinical behaviour and a poorer response to both primary and second-line therapeutic strategies [72].

In the recently developed brentuximab vedotin (SGN-35), an anti-CD30 antibody has been linked to monomethyl auristatin E, a tubulin inhibitor inducing cell cycle arrest and apoptosis [73, 74]. Early clinical trials have demonstrated striking activity of this antibody-drug conjugate in the treatment of patients with relapsed or refractory CD30+ lymphomas, yielding complete remission rates of around 60% in ALCL patients, with limited toxicity (reviewed in [74, 75]). The potential benefits of incorporating this promising agent into established chemotherapy regimens deserve to be further investigated, including as front-line therapy and possibly for patients with CD30+ PTCLs other than ALCL, such as CD30+ PTCLs, NOS, bearing a much poorer prognosis with conventional treatment approaches [72].

CD52

CD52 is a cell-surface glycoprotein of unknown function expressed by most normal B and T cells, monocytes and macrophages, but not on haemopoietic progenitors. The presence of CD52 antigen on the surface of malignant lymphocytes has been exploited therapeutically as the target of alemtuzumab (Campath-1H), a humanized anti-CD52 monoclonal antibody inducing complement-mediated cell lysis, antibody-dependent cell cytotoxicity and apoptosis [76, 77]. Several clinical trials have demonstrated the activity of alemtuzumab against PTCLs, particularly T-cell prolymphocytic leukemia (T-PLL) and cutaneous T-cell lymphomas (CTCLs) (reviewed in [23, 77]). In PTCL, NOS and AITL, promising responses have been observed in association with conventional

polychemotherapy regimens, although frequently with major hematologic toxicity and infectious complications (reviewed in [23, 78]).

An open question remains the delineation of the histological subtypes that could more efficiently be targeted by an anti-CD52 immunotherapy. By immunohistochemistry on paraffin sections, 30-50% of AITLs, PTCLs, NOS and NKTCLs but only a small minority of ALCLs were CD52 positive [76, 79, 80]. Conversely, by immunofluorescence on frozen tissues and/or by flow cytometry the detection rate of CD52 was generally higher, reaching 90-100% for AITLs, PTCLs, NOS and adult T-cell leukaemias/lymphomas (ATLLs), and 6-50% for ALCLs [81, 82]. GEP studies, on the other hand, have demonstrated a lower CD52 expression level in PTCLs, NOS compared to normal T cells [79], and in CD30+ PTCLs, NOS compared to CD30- PTCLs, NOS [7].

Surprisingly, despite this apparent heterogeneity among PTCLs, only very few studies have correlated the expression of CD52 by the neoplastic cells to the response to alemtuzumab, with divergent conclusions [83, 84]. Further studies are warranted to determine the predictive value of CD52 detection in PTCL samples, and the technique most suitable for this detection in routine settings (immunohistochemistry and/or flow cytometry).

Recurrent chromosomal translocations

Characteristic chromosomal translocations are a hallmark feature of most B-cell lymphomas, often involving the promoter of an immunoglobulin locus and a cellular oncogene which is thereby upregulated, offering both an explanation for the mechanism underlying their transformation and a useful diagnostic tool. Recurrent structural genetic alterations are also commonly observed in T-cell lymphoblastic neoplasms [5].

Conversely, the only PTCL entity that has been long recognized in association with a specific gene rearrangement is ALK⁺ ALCL, carrying *ALK* gene rearrangements [85]. Today this scenario is changing rapidly, as novel recurrent genetic alterations are being discovered in PTCLs, most recently as a result of next generation sequencing technologies combined with powerful bioinformatic algorithms [21], and their list is expected to be growing over the next few years.

ALK rearrangements

The anaplastic lymphoma kinase (ALK, also designated as CD246) is a transmembrane receptor tyrosine kinase, member of the insulin receptor superfamily, whose normal expression is restricted to scattered cells in the central nervous system. Aberrant activity of the ALK kinase has been shown to contribute to oncogenesis in various lymphoid and non-lymphoid malignancies (reviewed in [86]).

The distinguishing features of ALK⁺ ALCL, the best defined entity among PTCLs, are the presence of an *ALK* locus rearrangement at 2p23 and the ensuing aberrant ALK protein expression by the tumour cells [85]. *ALK* is most frequently juxtaposed to the nucleophosmin (*NPM*) gene in the t(2;5)(p23;q35) translocation. Less common

partner genes include Tropomyosin 3 (*TPM3*), TRK fused gene (*TFG*), *ATIC* (Pur H gene) and Clathrin heavy chain (*CLTC*) (reviewed in [5]). The different translocations lead to the deregulated expression of oncogenic fusion proteins, resulting in the constitutive activation of ALK and in the engagement of multiple signalling pathways, including the Jak3/Stat3 and the PI3K/Akt pathways [85].

Although morphologically ALK+ ALCLs span a broad spectrum including several variants, common features include the presence of so-called “hallmark cells” strongly positive for CD30 and the loss of expression of several T-cell antigens [2]. Since conversely other PTCL entities may express CD30, ALK testing is essential to confirm the diagnosis of ALK+ ALCL. *ALK* rearrangement can routinely be demonstrated by conventional karyotyping, fluorescence *in situ* hybridization (FISH) or RT-PCR (usually designed for detection of the NPM-ALK fusion transcript only). However, immunohistochemistry assesses ALK protein expression with high sensitivity and specificity and has largely replaced genetic assays. The subcellular location of the immunostaining is indicative of the type of translocation: in cases with the t(2;5)/*NPM-ALK* translocation ALK staining is both cytoplasmic and nuclear, while most variant translocations entail an ALK positivity restricted to the cytoplasm [87].

The distinction of ALK+ ALCL from other CD30+ PTCLs is prognostically relevant, since patients with the former usually have a much better outcome than patients with ALK- ALCL or PTCL, NOS (5-year OS of approximately 70%, 50% and 30%, respectively) [72].

From a therapeutic perspective, the recent discovery of an oncogenic *EML4* (echinoderm microtubule-associated protein-like 4)-*ALK* translocation in a small subset of lung adenocarcinomas has boosted the efforts for developing ALK-targeting drugs.

Several small-molecule ALK inhibitors are being tested preclinically, and crizotinib (PF-02341066) has yielded promising preliminary results and limited toxicity in patients with non-small-cell lung cancers [88]. ALK+ ALCL patients, particularly when refractory to standard chemotherapy regimens, may also benefit from this novel therapeutic option and will predictably be included in future trials.

***ITK-SYK* translocation**

The t(5;9)(q33;q22) translocation, first reported in 2006 in a small subset of PTCLs, NOS, juxtaposes the IL-2-inducible T-cell kinase (*ITK*) gene on chromosome 5 and the spleen tyrosine kinase (*SYK*) gene on chromosome 9 [19]. Itk and Syk are both nonreceptor tyrosine kinases with important functions in lymphocyte development and signal transduction; however, while Itk plays a critical role at all stages of T-cell development and differentiation, the expression of Syk is markedly reduced in normal peripheral T lymphocytes [89, 90]. The Itk-Syk fusion protein, comprising the N-terminal pleckstrin homology domain and proline-rich region of Itk and the tyrosine kinase domain of Syk [19], is a catalytically active tyrosine kinase with transforming properties demonstrated *in vitro* [91] and in transgenic mouse models [92, 93].

Intriguingly, the *ITK-SYK* translocation occurs predominantly in association with the follicular variant of PTCL, NOS (PTCL-F) [19, 67]. Although the characteristic expression of T_{FH}-cell markers in PTCL-F suggests a possible relationship with AITL, several clinical, morphologic and biological features distinguish these two entities, and the *ITK-SYK* translocation appears to be restricted to PTCL-F [19, 67, 94].

The t(5;9)/*ITK-SYK* translocation can be demonstrated on paraffin-embedded tissue sections by home-made FISH assays. Hitherto, the diagnostic utility of this test

seems limited, since the translocation is present in only 20% of PTCL-F, which beforehand represent a small minority of PTCLs, NOS [19, 67], and its prognostic significance is unknown. Interestingly, inhibition of Syk is being investigated as a novel potential therapeutic option in PTCLs [95] (see below), and a high sensitivity of tumours with *ITK-SYK* fusion may be expected.

Rearrangements involving the 6p25.3 locus (*IRF4* or *DUSP22*)

Novel recurrent chromosomal translocations have recently been reported in approximately 25% of ALK- ALCLs, comprising both systemic and primary cutaneous cases. Surprisingly, although all involve the same genetic locus at 6p25.3, the gene actually affected by the break appears to be variable, corresponding to *IRF4* in about one third of the cases and to *DUSP22* in the remainder [20, 21, 96, 97].

The interferon regulatory factor-4 (*IRF4*) transcription factor, also known as multiple myeloma oncogene-1 (*MUM1*), is an important regulator of normal lymphoid differentiation, expressed at highest levels in plasma cells and activated T lymphocytes. A subset of multiple myelomas harbours an *IRF4-IGH* translocation and overexpresses *MUM1/IRF4* [98]. In rearranged cases of ALK- ALCL, *IRF4*'s translocation partner is mostly unknown, and, somewhat unexpectedly, *MUM1/IRF4* expression does not appear to be upregulated [21]. Conversely, when the rearranged gene at 6p25.3 is *DUSP22* (encoding a dual-specificity phosphatase that inhibits TCR signalling), its partner locus is located at 7q32.3 in more than half of the cases, in close proximity of the *FRA7H* fragile site and the microRNA-coding *MIR29* gene. This recurrent t(6;7)(p25.3;q32.3) entails a downregulation of *DUSP22* and an overexpression of *MIR29*, leading to postulate that

the first (*DUSP22*) might function as a tumour suppressor and the second (*MIR29*) as an oncogene in translocated ALK- ALCLs [21].

The various 6p25.3 locus rearrangements occur in approximately 20% of systemic and 30% of cutaneous ALK- ALCLs, but only very occasionally in other PTCL entities [20, 21, 96, 97]. As a consequence, the detection of these rearrangements by FISH may be helpful in distinguishing ALK- ALCL from other CD30+ T-cell lymphoproliferations, particularly in the skin. Indeed, among primary cutaneous T-cell lymphoproliferative disorders, FISH positivity for a 6p25.3 translocation is 99% specific for primary cutaneous ALCL [96]. As a correct diagnosis has therapeutic consequences, FISH testing for 6p25.3 rearrangements should be integrated in the diagnostic work-up in this setting. Further investigations are needed, however, to determine the prognostic significance of these rearrangements.

Noteworthy is the report of a translocation involving the *TCRA* gene at the side of *IRF4* (t(6;14)(p25;q11.2)) in two cases of PTCL, NOS with a cytotoxic phenotype and a peculiar, strikingly similar, clinical presentation (bone marrow and skin infiltration), suggesting that these cases may constitute a distinct clinicopathologic entity [20].

Deregulated signalling pathways

The molecular characterization of PTCL entities has unravelled the deregulation of several signalling pathways in T-cell lymphomas in comparison with benign T-cell populations, entailing prognostic and/or therapeutic implications (reviewed in [99]).

Nuclear factor-*kappa*B (NF- κ B)

The nuclear factor-*kappa*B (NF- κ B) family of transcription factors has crucial functions during normal T-cell development and TCR-mediated activation, influencing T-cell proliferation and survival. Several lines of evidence indicate that deregulated NF- κ B activity is involved in the pathogenesis of human cancers, including various lymphoid malignancies, by enhancing proliferation and inhibiting apoptosis [100].

Constitutive NF- κ B activation is notably induced in cells infected by the human T-lymphotropic virus type 1 (HTLV-1), via the virus-encoded oncoprotein Tax, promoting cell proliferation and oncogenic transformation [100, 101]. HTLV-1 is indeed the causative agent of adult T-cell leukaemia/lymphoma (ATLL), a mostly aggressive PTCL presenting with generalized lymphadenopathy, peripheral blood involvement and often widespread systemic disease. The peculiar geographic distribution of this malignancy (mainly observed in Japan, the Caribbean basin and Central Africa) reflects the prevalence of HTLV-1 infection in the general population [2].

Besides ATLL, NF- κ B has also been shown to be aberrantly activated in cutaneous T-cell lymphomas (CTCLs) [102] and in NKTCLs, as recently demonstrated by several GEP studies [11, 18]. NF- κ B pathway engagement in NKTCLs is believed to be mediated by the Epstein-Barr virus (EBV), which is invariably associated with this

destructive extranodal (prototypically nasal) cytotoxic lymphoma, most prevalent in Asia and Central-South America [2].

Several NF- κ B-blocking compounds have been shown to inhibit proliferation and induce apoptosis in malignant T cells *in vitro* [101, 102]. Among these agents bortezomib (PS-341, a proteasome inhibitor) has demonstrated promising clinical activity against CTCLs and, in combination with CHOP, in a subset of patients with aggressive systemic PTCLs (including PTCL, NOS, NKTCL, AITL and ALK- ALCL) (reviewed in [78]). Other clinical trials are to be expected in the near future, and will hopefully include ATLL and NKTCL patients.

In one study the global NF- κ B signature was found of prognostic value, the overexpression of NF- κ B-related genes correlating with a significantly better outcome within most PTCL entities (PTCL, NOS, AITL, NKTCL and CTCL) [12].

Although testing of the NF- κ B pathway is not well codified and not yet performed routinely in PTCL samples, several proteins of the NF- κ B family can be detected by immunohistochemistry and might be explored in future trials to confirm their prognostic significance [11, 12, 18].

Spleen tyrosine kinase (Syk)

The activation of the spleen tyrosine kinase (Syk) is an essential step in the signal transduction from immune receptors, regulating early lymphocyte development. In mature lymphoid cells, Syk is mainly involved in B-cell receptor (BCR) signalling, while in normal T lymphocytes *SYK* is downregulated and largely supplanted by Zap-70 (a Syk homologue) for transducing T-cell receptor (TCR)-mediated signals [90]. Syk kinase activity is modulated by the differential phosphorylation of critical tyrosine residues

within the kinase domain and in linker regions, allowing the transition between an autoinhibited and an active conformation [103].

Contrasting with the rarity of the t(5;9)/*ITK-SYK* translocation, aberrant Syk expression has been recently demonstrated in the vast majority (94%) of a large series of PTCLs representative of most histotypes. An active phosphorylation status of the Syk kinase could be confirmed in 4/4 Syk-positive samples analyzed by Western blot [94]. Moreover, the Syk inhibitor fostamatinib disodium (R406) was shown to inhibit proliferation and induce apoptosis in T-cell lymphoma cell lines [95], leading to an ongoing trial of fostamatinib in PTCL patients [23]. However, the high prevalence of Syk upregulation in PTCLs observed by Feldman *et al.* [94] was not found by others, who reported Syk expression to be mostly absent [104] or limited to a subset of CD30+ PTCLs [105], a discordance that is perhaps due to the use of different antibodies, detecting functionally distinct forms of Syk. Nevertheless, given the important therapeutic implications of targeting the activated subset of the kinase, this issue needs to be elucidated by further research.

Platelet-derived growth factor receptor alpha (PDGFR α)

Platelet-derived growth factor receptor alpha (PDGFR α) is a receptor tyrosine kinase that undergoes dimerization and autophosphorylation upon ligand (PDGF) binding, thereby activating several major signal transduction cascades, including the PI3K/Akt and the Ras-MAPK pathways, which in turn mediate important cell functions such as migration, proliferation and cell survival. Physiological PDGFR α expression is mainly observed in mesenchymal cells and is induced during inflammation. Deregulation of PDGFR α signalling contributes to the pathogenesis of various malignancies, and has been shown to

result from either *PDGFRA* gene amplifications (e.g. in glioblastomas), activating mutations (e.g. in gastrointestinal stromal tumours (GISTs)) or translocations (e.g. *FIP1L1-PDGFRA* translocation in hypereosinophilic syndrome and chronic eosinophilic leukaemia) (reviewed in [106]).

Recent GEP studies have demonstrated an upregulation of *PDGFRA* in several PTCL entities, comprising PTCLs, NOS [15, 17], AITLs [16] and NKTCLs [11], with evidence of an aberrant expression of both PDGFR α and its active phosphorylated form (pPDGFR α) in over 85-90% of the samples. The mechanisms underlying *PDGFRA* gene deregulation in PTCLs remain unclear, since neither genomic imbalances of its locus at 4q11–q13 nor mutations in the coding sequence or in the promoter region could be evidenced in the PDGFR α -positive samples [11, 107].

Furthermore, *in vitro* studies have demonstrated the sensitivity of malignant T cells to imatinib mesylate, a tyrosine kinase inhibitor with known anti-PDGFR α activity. Imatinib induced a concentration-dependent growth inhibition and/or cell death of PTCL, NOS primary cells and NKTCL cell lines, with only a limited effect on the viability of normal lymphocytes [11, 17].

Altogether, these data point towards PDGFR α as a new candidate for targeted treatment strategies in patients with PTCLs. Further preclinical and clinical validation is needed to confirm the potential role of imatinib or other more recently developed tyrosine kinase inhibitors in this setting.

Summary

The pathological diagnosis of PTCLs is often challenging, and with few exceptions affected patients have a dismal outcome. Genome-wide molecular analyses have consented to identify novel biomarkers that may improve the practical management of these patients. Cutaneous PTCLs of $\gamma\delta$ derivation must be distinguished from their $\alpha\beta$ counterparts because of a more aggressive behaviour. Cytotoxic proteins are variably expressed by several PTCL entities, and appear to confer a poorer prognosis when detected in PTCLs, NOS. Granzyme H may be helpful in distinguishing NKTCL from other cytotoxic PTCL subtypes, and a restricted KIR repertoire can be used as a surrogate marker of clonality in NK-cell proliferations. The expression of T_{FH}-cell markers is routinely explored to ascertain the diagnosis of AITL, as a reflection of its histogenetic derivation. Other molecules variably expressed at the surface of PTCLs can be targeted by immunotherapeutic agents. Particularly antibodies or antibody conjugates directed against CD52 and CD30 have shown promising results in clinical trials. At the genetic level, previously unrecognized chromosomal translocations are being discovered in several PTCL subtypes, providing hints to their pathogenesis as well as novel diagnostic markers. The *ITK-SYK* translocation is associated with the follicular variant of PTCL, NOS, while recurrent *IRF4* and *DUSP22* rearrangements have newly been reported in subsets of cutaneous and systemic ALK- ALCLs. Molecules deregulated in oncogenic pathways are increasingly being identified through GEP studies, including transcription factors and tyrosine kinases such as NF- κ B, PDGFR α and Syk. Specific inhibitors targeting these proteins are being evaluated as novel therapeutic options.

Practice points

- $\gamma\delta$ PTCLs are highly aggressive disease, irrespective of their site of origin, and can be ascertained in routinely processed tissues by immunohistochemistry since recently.
- Subsets of PTCLs express CD30 or CD52 on their surface and therapeutic antibodies targeting these molecules (brentuximab and alemtuzumab, respectively) have shown promising clinical activity.
- Recurrent chromosomal translocations, traditionally considered as a hallmark of B-cell lymphomas, are being discovered in several PTCL entities.
- Gene expression studies have identified oncogenic pathways deregulated in PTCLs, disclosing potential targets for novel therapies, including tyrosine kinase and proteasome inhibitors.

Research agenda

- PTCLs are rare and heterogeneous diseases with a dismal prognosis. International collaborative efforts are needed to gather large homogeneous cohorts of patients and tumour samples, to allow meaningful clinical and translational research.
- The distinction of cytotoxic versus non-cytotoxic PTCLs, NOS has appeared to be biologically significant, but testing of larger series is required to establish its clinical relevance.
- Next-generation genome-wide technologies will be disclosing novel oncogenic mechanisms, predictive markers and therapeutic targets in the near future, opening the way for individually tailored treatments for PTCL patients as well.

Acknowledgements

This work was supported by the Belgian National Fund for Scientific Research (Fonds de la Recherche Scientifique, FNRS), the Belgian Cancer Plan, and the French Foundation for Medical Research (Fondation pour la Recherche Médicale, FRM). Bettina Bisig and Laurence de Leval are a Scientific Research Worker-Télévie and a Senior Research Associate of the FNRS, respectively.

Tables and figures

Table 1.

Current WHO classification and worldwide frequency of peripheral T-cell and NK-cell lymphomas (adapted from Swerdlow *et al.* [2]).

Predominant presentation	PTCL entity	Frequency (%)**
Disseminated/leukaemic	T-cell prolymphocytic leukaemia	
	T-cell large granular lymphocytic leukaemia	
	Chronic lymphoproliferative disorders of NK cells*	
	Aggressive NK-cell leukaemia	
	Systemic EBV-positive T-cell lymphoproliferative disease of childhood	
	Adult T-cell leukaemia/lymphoma	9.6
Extranodal	Extranodal NK/T-cell lymphoma, nasal type	10.4
	Enteropathy-associated T-cell lymphoma	4.7
	Hepatosplenic T-cell lymphoma	1.4
Cutaneous	Subcutaneous panniculitis-like T-cell lymphoma	0.9
	Mycosis fungoides	
	Sézary syndrome	
	Primary cutaneous CD30+ T-cell lymphoproliferative disorders	
	Primary cutaneous anaplastic large cell lymphoma	1.7
	Lymphomatoid papulosis	
	Primary cutaneous $\gamma\delta$ T-cell lymphoma	
	Primary cutaneous CD8+ aggressive epidermotropic cytotoxic T-cell lymphoma*	
	Primary cutaneous CD4+ small/medium T-cell lymphoma*	
Hydroa vacciniforme-like lymphoma		
Nodal	Peripheral T-cell lymphoma, not otherwise specified	25.9
	Angioimmunoblastic T-cell lymphoma	18.5
	Anaplastic large-cell lymphoma, ALK-positive	6.6
	Anaplastic large-cell lymphoma, ALK-negative*	5.5

ALK, anaplastic lymphoma kinase; EBV, Epstein-Barr virus; NK, natural killer.

* Provisional entities.

** According to Vose *et al.* [3]. Statistics are based on pathologic anatomy registries, with under-representation of leukaemic and cutaneous entities.

Table 2.

Summary of the biomarkers discussed in this review and their clinical relevance in the diagnosis, prognosis or treatment of peripheral T-cell lymphoma entities.

Biomarkers	Associated PTCL entities	Clinical significance
Lineage / differentiation markers		
TCR γ and TCR δ chains	HSTL Primary cutaneous $\gamma\delta$ TCL Other non-HS $\gamma\delta$ PTCLs	<i>Diagnosis</i> <i>Prognosis:</i> $\gamma\delta$ PTCLs are highly aggressive
NK-cell receptors: KIRs	NK-cell lymphoproliferations, T-LGL (restricted KIR repertoire) Sézary syndrome (aberrant expression of CD158k/ KIR3DL2)	<i>Diagnosis</i>
Cytotoxic molecules: TIA-1, perforin, granzyme B, granzyme H	Cfr. Table 3	<i>Diagnosis</i> <i>Prognosis:</i> cytotoxic PTCLs, NOS have poorer outcome
T _{FH} -cell markers: CXCL13, PD-1, ICOS, CD200, SAP, Bcl-6, c-Maf	AITL PTCL-F Primary cutaneous CD4+ small/ medium TCL	<i>Diagnosis</i>
Cell-surface markers		
CD30	ALK+ and ALK- ALCL Subset of PTCL, NOS Primary cutaneous CD30+ T-cell lymphoproliferative disorders	<i>Diagnosis</i> <i>Therapy:</i> brentuximab vedotin targets CD30
CD52	Subset of AITL, PTCL, NOS, NKTCL, ATLL Minority of ALCL	<i>Therapy:</i> alemtuzumab targets CD52
Chromosomal translocations		
<i>ALK</i> rearrangement	ALK+ ALCL	<i>Diagnosis</i> <i>Prognosis:</i> ALK+ ALCLs have better outcome
<i>ITK-SYK</i> translocation	Subset of PTCL-F	<i>Diagnosis</i> <i>Therapy:</i> fostamatinib inhibits Syk activity
<i>IRF4</i> or <i>DUSP22</i>	Subset of systemic and cutaneous	<i>Diagnosis</i>

rearrangement

ALK- ALCL

Signalling pathways

NF- κ B

ATLL
NKTCL
Cutaneous TCL
PTCL, NOS, AITL, ALK- ALCL

Prognosis:
“NF- κ B high” PTCLs
have better outcome
Therapy:
bortezomib blocks NF- κ B pathway

Syk

Majority of PTCLs (Feldman, 2008)
Subset of CD30+ PTCLs
(Geissinger, 2010)

Therapy:
fostamatinib inhibits Syk activity

PDGFR α

PTCL, NOS
AITL
NKTCL

Therapy:
imatinib inhibits PDGFR α activity

AITL, angioimmunoblastic T-cell lymphoma; ALCL, anaplastic large cell lymphoma; ALK, anaplastic lymphoma kinase; ATLL, adult T-cell leukaemia/lymphoma; HSTL, hepatosplenic T-cell lymphoma; KIR, killer cell immunoglobulin-like receptor; NK, natural killer; NKTCL, extranodal NK/T-cell lymphoma; non-HS, non-hepatosplenic; NOS, not otherwise specified; PTCL, peripheral T-cell lymphoma; PTCL-F, follicular variant of PTCL, NOS; TCL, T-cell lymphoma; TCR, T-cell receptor; T_{FH}, follicular helper T cell; T-LGL, T-cell large granular lymphocytic leukaemia.

Table 3.

Overview of major peripheral T-cell lymphoma entities associated with a cytotoxic phenotype and presenting with tissue involvement.

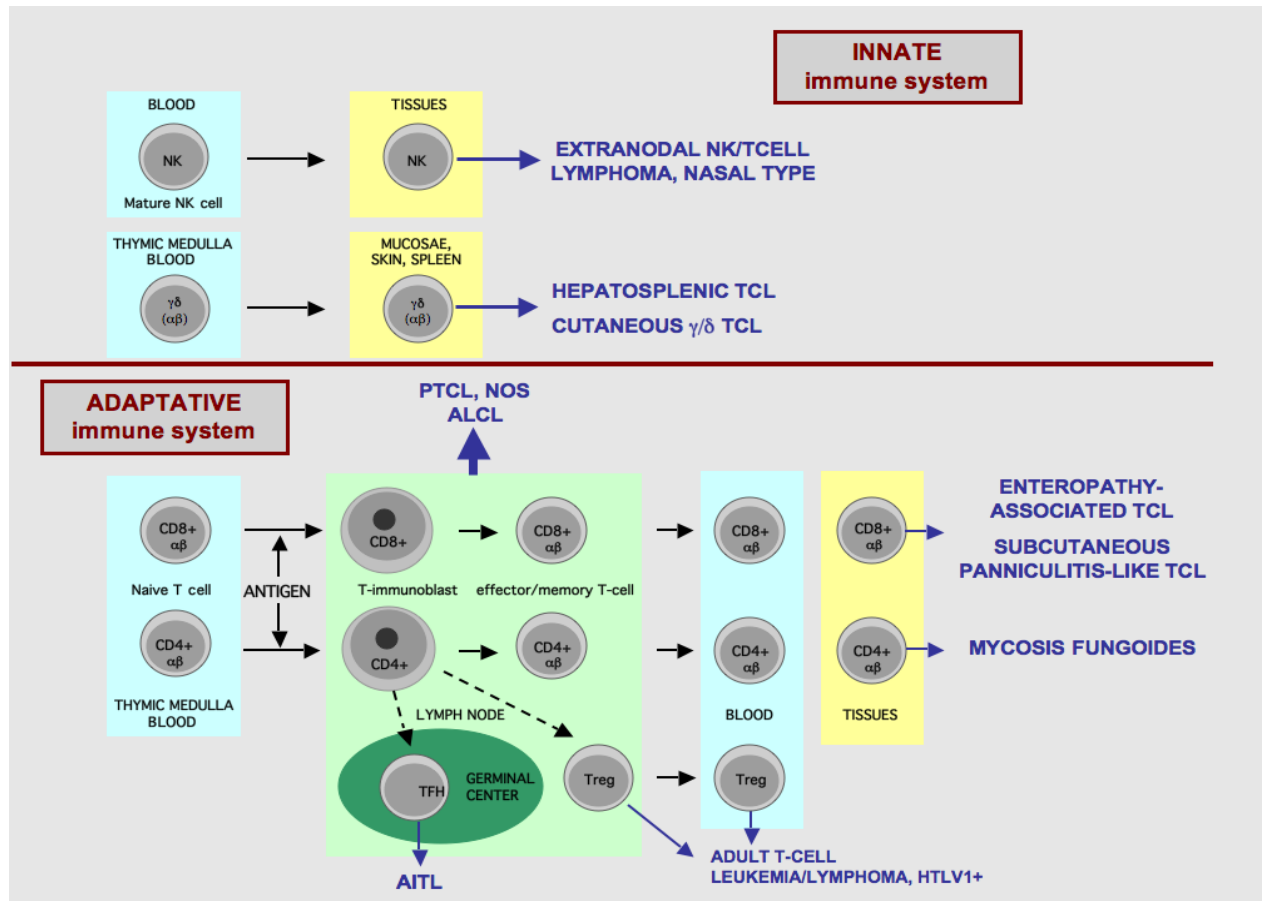
PTCL entity	Predominant presentation	Postulated cell of origin	Cytotoxic phenotype*	EBV status
NKTCL, nasal type	Extranodal	NK cells (rarely $\gamma\delta$ or $\alpha\beta$ T cells)	Activated	Positive
EATL	Extranodal	$\alpha\beta$ T cells (rarely $\gamma\delta$ T cells)	Activated	Negative
HSTL	Extranodal	$\gamma\delta$ T cells (rarely $\alpha\beta$ T cells)	Non-activated	Negative
Subcutaneous panniculitis-like TCL	Cutaneous	$\alpha\beta$ T cells	Activated	Negative
Primary cutaneous CD30+ T-cell lymphoproliferative disorders	Cutaneous	$\alpha\beta$ T cells	Activated	Negative
Primary cutaneous $\gamma\delta$ TCL	Cutaneous	$\gamma\delta$ T cells	Activated	Negative
PTCL, NOS (subset)	Nodal	$\alpha\beta$ T cells	Variable	Variable
ALK+ ALCL	Nodal	$\alpha\beta$ T cells	Activated	Negative
ALK- ALCL	Nodal	$\alpha\beta$ T cells	Activated	Negative

ALCL, anaplastic large cell lymphoma; ALK, anaplastic lymphoma kinase; EATL, enteropathy-associated T-cell lymphoma; EBV, Epstein-Barr virus; HSTL, hepatosplenic T-cell lymphoma; NKTCL, extranodal NK/T-cell lymphoma; non-HS, non-hepatosplenic; NOS, not otherwise specified; PTCL, peripheral T-cell lymphoma; TCL, T-cell lymphoma.

* Activated cytotoxic phenotype: expression of perforin and/or granzyme B in addition to TIA-1; non-activated cytotoxic phenotype: expression of TIA-1 only.

Fig. 1.

Overview of normal T-cell and NK-cell differentiation and putative histogenetic derivation of the major PTCL entities (reproduced with permission from de Leval *et al.* [25]).



AITL, angioimmunoblastic T-cell lymphoma; ALCL, anaplastic large cell lymphoma; HTLV1, human T-lymphotropic virus type 1; NK, natural killer cell; NOS, not otherwise specified; PTCL, peripheral T-cell lymphoma; TCL, T-cell lymphoma; TFH, follicular helper T cell; Treg, regulatory T cell.

References

- [1] Rudiger T, Weisenburger DD, Anderson JR, et al. Peripheral T-cell lymphoma (excluding anaplastic large-cell lymphoma): results from the Non-Hodgkin's Lymphoma Classification Project. *Ann Oncol* 2002;13:140-9.
- [2] Swerdlow SH, Campo E, Harris NL, et al. WHO Classification of Tumours of Haematopoietic and Lymphoid Tissues. Lyon: IARC; 2008.
- [3] Vose J, Armitage J, Weisenburger D. International peripheral T-cell and natural killer/T-cell lymphoma study: pathology findings and clinical outcomes. *J Clin Oncol* 2008;26:4124-30.
- [4] Foss FM, Zinzani PL, Vose JM, et al. Peripheral T-cell lymphoma. *Blood* 2011;117:6756-67.
- *[5] de Leval L, Bisig B, Thielen C, et al. Molecular classification of T-cell lymphomas. *Crit Rev Oncol Hematol* 2009;72:125-43.
- [6] Costello R, Sanchez C, Le Treut T, et al. Peripheral T-cell lymphoma gene expression profiling and potential therapeutic exploitations. *Br J Haematol* 2010;150:21-7.
- *[7] de Leval L, Rickman DS, Thielen C, et al. The gene expression profile of nodal peripheral T-cell lymphoma demonstrates a molecular link between angioimmunoblastic T-cell lymphoma (AITL) and follicular helper T (TFH) cells. *Blood* 2007;109:4952-63.
- [8] Lamant L, de Reynies A, Duplantier MM, et al. Gene-expression profiling of systemic anaplastic large-cell lymphoma reveals differences based on ALK status and two distinct morphologic ALK+ subtypes. *Blood* 2007;109:2156-64.
- [9] Thompson MA, Stumph J, Henrickson SE, et al. Differential gene expression in anaplastic lymphoma kinase-positive and anaplastic lymphoma kinase-negative anaplastic large cell lymphomas. *Hum Pathol* 2005;36:494-504.
- *[10] Iqbal J, Weisenburger DD, Greiner TC, et al. Molecular signatures to improve diagnosis in peripheral T-cell lymphoma and prognostication in angioimmunoblastic T-cell lymphoma. *Blood* 2010;115:1026-36.
- *[11] Huang Y, de Reynies A, de Leval L, et al. Gene expression profiling identifies emerging oncogenic pathways operating in extranodal NK/T-cell lymphoma, nasal type. *Blood* 2010;115:1226-37.
- [12] Martinez-Delgado B, Cuadros M, Honrado E, et al. Differential expression of NF-kappaB pathway genes among peripheral T-cell lymphomas. *Leukemia* 2005;19:2254-63.
- [13] Ballester B, Ramuz O, Gisselbrecht C, et al. Gene expression profiling identifies molecular subgroups among nodal peripheral T-cell lymphomas. *Oncogene* 2006;25:1560-70.
- [14] Cuadros M, Dave SS, Jaffe ES, et al. Identification of a proliferation signature related to survival in nodal peripheral T-cell lymphomas. *J Clin Oncol* 2007;25:3321-9.
- [15] Piccaluga PP, Agostinelli C, Zinzani PL, et al. Expression of platelet-derived growth factor receptor alpha in peripheral T-cell lymphoma not otherwise specified. *Lancet Oncol* 2005;6:440.
- [16] Piccaluga PP, Agostinelli C, Califano A, et al. Gene expression analysis of angioimmunoblastic lymphoma indicates derivation from T follicular helper cells and vascular endothelial growth factor deregulation. *Cancer Res* 2007;67:10703-10.

- *[17] Piccaluga PP, Agostinelli C, Califano A, et al. Gene expression analysis of peripheral T cell lymphoma, unspecified, reveals distinct profiles and new potential therapeutic targets. *J Clin Invest* 2007;117:823-34.
- [18] Ng SB, Selvarajan V, Huang G, et al. Activated oncogenic pathways and therapeutic targets in extranodal nasal-type NK/T cell lymphoma revealed by gene expression profiling. *J Pathol* 2011;223:496-510.
- [19] Streubel B, Vinatzer U, Willheim M, et al. Novel t(5;9)(q33;q22) fuses ITK to SYK in unspecified peripheral T-cell lymphoma. *Leukemia* 2006;20:313-8.
- [20] Feldman AL, Law M, Remstein ED, et al. Recurrent translocations involving the IRF4 oncogene locus in peripheral T-cell lymphomas. *Leukemia* 2009;23:574-80.
- *[21] Feldman AL, Dogan A, Smith DI, et al. Discovery of recurrent t(6;7)(p25.3;q32.3) translocations in ALK-negative anaplastic large cell lymphomas by massively parallel genomic sequencing. *Blood* 2011;117:915-9.
- [22] Morris JC, Waldmann TA, Janik JE. Receptor-directed therapy of T-cell leukemias and lymphomas. *J Immunotoxicol* 2008;5:235-48.
- [23] Dunleavy K, Piekarczyk RL, Zain J, et al. New strategies in peripheral T-cell lymphoma: understanding tumor biology and developing novel therapies. *Clin Cancer Res* 2010;16:5608-17.
- [24] de Leval L, Gaulard P. Pathobiology and molecular profiling of peripheral T-cell lymphomas. *Hematology Am Soc Hematol Educ Program* 2008:272-9.
- [25] de Leval L, Gaulard P. Pathology and biology of peripheral T-cell lymphomas. *Histopathology* 2011;58:49-68.
- [26] Piccaluga PP, Agostinelli C, Tripodo C, et al. Peripheral T-cell lymphoma classification: the matter of cellular derivation. *Expert Rev Hematol* 2011;4:415-25.
- [27] Gaulard P, Belhadj K, Reyes F. Gammadelta T-cell lymphomas. *Semin Hematol* 2003;40:233-43.
- [28] Tripodo C, Iannitto E, Florena AM, et al. Gamma-delta T-cell lymphomas. *Nat Rev Clin Oncol* 2009;6:707-17.
- [29] Macon WR, Levy NB, Kurtin PJ, et al. Hepatosplenic alphabeta T-cell lymphomas: a report of 14 cases and comparison with hepatosplenic gammadelta T-cell lymphomas. *Am J Surg Pathol* 2001;25:285-96.
- [30] Belhadj K, Reyes F, Farcet JP, et al. Hepatosplenic gammadelta T-cell lymphoma is a rare clinicopathologic entity with poor outcome: report on a series of 21 patients. *Blood* 2003;102:4261-9.
- [31] Vega F, Medeiros LJ, Gaulard P. Hepatosplenic and other gammadelta T-cell lymphomas. *Am J Clin Pathol* 2007;127:869-80.
- [32] Toro JR, Liewehr DJ, Pabby N, et al. Gamma-delta T-cell phenotype is associated with significantly decreased survival in cutaneous T-cell lymphoma. *Blood* 2003;101:3407-12.
- [33] Willemze R, Jaffe ES, Burg G, et al. WHO-EORTC classification for cutaneous lymphomas. *Blood* 2005;105:3768-85.
- [34] Arnulf B, Copie-Bergman C, Delfau-Larue MH, et al. Nonhepatosplenic gammadelta T-cell lymphoma: a subset of cytotoxic lymphomas with mucosal or skin localization. *Blood* 1998;91:1723-31.
- [35] Miyazaki K, Yamaguchi M, Imai H, et al. Gene expression profiling of peripheral T-cell lymphoma including gammadelta T-cell lymphoma. *Blood* 2009;113:1071-4.

- [36] Iqbal J, Weisenburger DD, Chowdhury A, et al. Natural killer cell lymphoma shares strikingly similar molecular features with a group of non-hepatosplenic gammadelta T-cell lymphoma and is highly sensitive to a novel aurora kinase A inhibitor in vitro. *Leukemia* 2011;25:1377.
- [37] Garcia-Herrera A, Song JY, Chuang SS, et al. Nonhepatosplenic gammadelta T-cell Lymphomas Represent a Spectrum of Aggressive Cytotoxic T-cell Lymphomas With a Mainly Extranodal Presentation. *Am J Surg Pathol* 2011;35:1214-25.
- [38] Rouillet M, Gheith SM, Mauger J, et al. Percentage of $\{\gamma\}\{\delta\}$ T cells in panniculitis by paraffin immunohistochemical analysis. *Am J Clin Pathol* 2009;131:820-6.
- [39] Morice WG. The immunophenotypic attributes of NK cells and NK-cell lineage lymphoproliferative disorders. *Am J Clin Pathol* 2007;127:881-6.
- [40] Morice WG, Jevremovic D, Olteanu H, et al. Chronic lymphoproliferative disorder of natural killer cells: a distinct entity with subtypes correlating with normal natural killer cell subsets. *Leukemia* 2010;24:881-4.
- [41] Haedicke W, Ho FC, Chott A, et al. Expression of CD94/NKG2A and killer immunoglobulin-like receptors in NK cells and a subset of extranodal cytotoxic T-cell lymphomas. *Blood* 2000;95:3628-30.
- [42] Morice WG, Macon WR, Dogan A, et al. NK-cell-associated receptor expression in hepatosplenic T-cell lymphoma, insights into pathogenesis. *Leukemia* 2006;20:883-6.
- [43] Dukers DF, Vermeer MH, Jaspars LH, et al. Expression of killer cell inhibitory receptors is restricted to true NK cell lymphomas and a subset of intestinal enteropathy-type T cell lymphomas with a cytotoxic phenotype. *J Clin Pathol* 2001;54:224-8.
- [44] Poszepczynska-Guigne E, Schiavon V, D'Incan M, et al. CD158k/KIR3DL2 is a new phenotypic marker of Sezary cells: relevance for the diagnosis and follow-up of Sezary syndrome. *J Invest Dermatol* 2004;122:820-3.
- [45] Bahler DW, Hartung L, Hill S, et al. CD158k/KIR3DL2 is a useful marker for identifying neoplastic T-cells in Sezary syndrome by flow cytometry. *Cytometry B Clin Cytom* 2008;74:156-62.
- [46] Asano N, Suzuki R, Kagami Y, et al. Clinicopathologic and prognostic significance of cytotoxic molecule expression in nodal peripheral T-cell lymphoma, unspecified. *Am J Surg Pathol* 2005;29:1284-93.
- [47] Asano N, Suzuki R, Ohshima K, et al. Linkage of expression of chemokine receptors (CXCR3 and CCR4) and cytotoxic molecules in peripheral T cell lymphoma, not otherwise specified and ALK-negative anaplastic large cell lymphoma. *Int J Hematol* 2010;91:426-35.
- [48] Kanavaros P, Boulland ML, Petit B, et al. Expression of cytotoxic proteins in peripheral T-cell and natural killer-cell (NK) lymphomas: association with extranodal site, NK or T gammadelta phenotype, anaplastic morphology and CD30 expression. *Leuk Lymphoma* 2000;38:317-26.
- [49] Vinuesa CG, Tangye SG, Moser B, Mackay CR. Follicular B helper T cells in antibody responses and autoimmunity. *Nat Rev Immunol* 2005;5:853-65.
- [50] Crotty S. Follicular helper CD4 T cells (TFH). *Annu Rev Immunol* 2011;29:621-63.
- [51] Chtanova T, Tangye SG, Newton R, et al. T follicular helper cells express a distinctive transcriptional profile, reflecting their role as non-Th1/Th2 effector cells that provide help for B cells. *J Immunol* 2004;173:68-78.

- [52] Kim CH, Lim HW, Kim JR, et al. Unique gene expression program of human germinal center T helper cells. *Blood* 2004;104:1952-60.
- [53] de Leval L, Gisselbrecht C, Gaulard P. Advances in the understanding and management of angioimmunoblastic T-cell lymphoma. *Br J Haematol* 2010;148:673-89.
- [54] Grogg KL, Attygalle AD, Macon WR, et al. Angioimmunoblastic T-cell lymphoma: a neoplasm of germinal-center T-helper cells? *Blood* 2005;106:1501-2.
- [55] Dupuis J, Boye K, Martin N, et al. Expression of CXCL13 by neoplastic cells in angioimmunoblastic T-cell lymphoma (AITL): a new diagnostic marker providing evidence that AITL derives from follicular helper T cells. *Am J Surg Pathol* 2006;30:490-4.
- [56] Yu H, Shahsafaei A, Dorfman DM. Germinal-center T-helper-cell markers PD-1 and CXCL13 are both expressed by neoplastic cells in angioimmunoblastic T-cell lymphoma. *Am J Clin Pathol* 2009;131:33-41.
- [57] Dorfman DM, Brown JA, Shahsafaei A, Freeman GJ. Programmed death-1 (PD-1) is a marker of germinal center-associated T cells and angioimmunoblastic T-cell lymphoma. *Am J Surg Pathol* 2006;30:802-10.
- [58] Marafioti T, Paterson JC, Ballabio E, et al. The inducible T-cell co-stimulator molecule is expressed on subsets of T cells and is a new marker of lymphomas of T follicular helper cell-derivation. *Haematologica* 2010;95:432-9.
- [59] Dorfman DM, Shahsafaei A. CD200 (OX-2 membrane glycoprotein) is expressed by follicular T helper cells and in angioimmunoblastic T-cell lymphoma. *Am J Surg Pathol* 2011;35:76-83.
- [60] Roncador G, Garcia Verdes-Montenegro JF, Tedoldi S, et al. Expression of two markers of germinal center T cells (SAP and PD-1) in angioimmunoblastic T-cell lymphoma. *Haematologica* 2007;92:1059-66.
- [61] Ree HJ, Kadin ME, Kikuchi M, et al. Bcl-6 expression in reactive follicular hyperplasia, follicular lymphoma, and angioimmunoblastic T-cell lymphoma with hyperplastic germinal centers: heterogeneity of intrafollicular T-cells and their altered distribution in the pathogenesis of angioimmunoblastic T-cell lymphoma. *Hum Pathol* 1999;30:403-11.
- [62] Bisig B, Thielen C, Herens C, et al. c-Maf expression in angioimmunoblastic T-cell lymphoma reflects follicular helper T-cell derivation rather than oncogenesis. *Histopathology* 2011 (in press).
- [63] Rodriguez-Pinilla SM, Atienza L, Murillo C, et al. Peripheral T-cell lymphoma with follicular T-cell markers. *Am J Surg Pathol* 2008;32:1787-99.
- [64] Zhan HQ, Li XQ, Zhu XZ, et al. Expression of follicular helper T cell markers in nodal peripheral T cell lymphomas: a tissue microarray analysis of 162 cases. *J Clin Pathol* 2011;64:319-24.
- [65] Gaulard P, de Leval L. Follicular helper T cells: implications in neoplastic hematopathology. *Semin Diagn Pathol* 2011;28:202-13.
- [66] de Leval L, Savilo E, Longtine J, et al. Peripheral T-cell lymphoma with follicular involvement and a CD4+/bcl-6+ phenotype. *Am J Surg Pathol* 2001;25:395-400.
- [67] Huang Y, Moreau A, Dupuis J, et al. Peripheral T-cell lymphomas with a follicular growth pattern are derived from follicular helper T cells (TFH) and may show overlapping features with angioimmunoblastic T-cell lymphomas. *Am J Surg Pathol* 2009;33:682-90.

- [68] Rodriguez Pinilla SM, Roncador G, Rodriguez-Peralto JL, et al. Primary cutaneous CD4+ small/medium-sized pleomorphic T-cell lymphoma expresses follicular T-cell markers. *Am J Surg Pathol* 2009;33:81-90.
- [69] Beltraminelli H, Leinweber B, Kerl H, Cerroni L. Primary cutaneous CD4+ small-/medium-sized pleomorphic T-cell lymphoma: a cutaneous nodular proliferation of pleomorphic T lymphocytes of undetermined significance? A study of 136 cases. *Am J Dermatopathol* 2009;31:317-22.
- [70] Al-Shamkhani A. The role of CD30 in the pathogenesis of haematopoietic malignancies. *Curr Opin Pharmacol* 2004;4:355-9.
- [71] de Leval L, Gaulard P. CD30+ lymphoproliferative disorders. *Haematologica* 2010;95:1627-30.
- [72] Savage KJ, Harris NL, Vose JM, et al. ALK- anaplastic large-cell lymphoma is clinically and immunophenotypically different from both ALK+ ALCL and peripheral T-cell lymphoma, not otherwise specified: report from the International Peripheral T-Cell Lymphoma Project. *Blood* 2008;111:5496-504.
- [73] Francisco JA, Cerveny CG, Meyer DL, et al. cAC10-vcMMAE, an anti-CD30-monomethyl auristatin E conjugate with potent and selective antitumor activity. *Blood* 2003;102:1458-65.
- [74] Foyil KV, Bartlett NL. Brentuximab vedotin for the treatment of CD30+ lymphomas. *Immunotherapy* 2011;3:475-85.
- [75] Ansell SM. Brentuximab vedotin: delivering an antimitotic drug to activated lymphoma cells. *Expert Opin Investig Drugs* 2011;20:99-105.
- [76] Rodig SJ, Abramson JS, Pinkus GS, et al. Heterogeneous CD52 expression among hematologic neoplasms: implications for the use of alemtuzumab (CAMPATH-1H). *Clin Cancer Res* 2006;12:7174-9.
- [77] Dearden CE, Matutes E. Alemtuzumab in T-cell lymphoproliferative disorders. *Best Pract Res Clin Haematol* 2006;19:795-810.
- *[78] Howman RA, Prince HM. New drug therapies in peripheral T-cell lymphoma. *Expert Rev Anticancer Ther* 2011;11:457-72.
- [79] Piccaluga PP, Agostinelli C, Righi S, et al. Expression of CD52 in peripheral T-cell lymphoma. *Haematologica* 2007;92:566-7.
- [80] Chang ST, Lu CL, Chuang SS. CD52 expression in non-mycotic T- and NK/T-cell lymphomas. *Leuk Lymphoma* 2007;48:117-21.
- [81] Geissinger E, Bonzheim I, Roth S, et al. CD52 expression in peripheral T-cell lymphomas determined by combined immunophenotyping using tumor cell specific T-cell receptor antibodies. *Leuk Lymphoma* 2009;50:1010-6.
- [82] Jiang L, Yuan CM, Hubacheck J, et al. Variable CD52 expression in mature T cell and NK cell malignancies: implications for alemtuzumab therapy. *Br J Haematol* 2009;145:173-9.
- [83] Ginaldi L, De Martinis M, Matutes E, et al. Levels of expression of CD52 in normal and leukemic B and T cells: correlation with in vivo therapeutic responses to Campath-1H. *Leuk Res* 1998;22:185-91.
- [84] Gallamini A, Zaja F, Patti C, et al. Alemtuzumab (Campath-1H) and CHOP chemotherapy as first-line treatment of peripheral T-cell lymphoma: results of a GITIL (Gruppo Italiano Terapie Innovative nei Linfomi) prospective multicenter trial. *Blood* 2007;110:2316-23.

- [85] Amin HM, Lai R. Pathobiology of ALK+ anaplastic large-cell lymphoma. *Blood* 2007;110:2259-67.
- [86] Webb TR, Slavish J, George RE, et al. Anaplastic lymphoma kinase: role in cancer pathogenesis and small-molecule inhibitor development for therapy. *Expert Rev Anticancer Ther* 2009;9:331-56.
- [87] Falini B, Pulford K, Pucciarini A, et al. Lymphomas expressing ALK fusion protein(s) other than NPM-ALK. *Blood* 1999;94:3509-15.
- [88] Gerber DE, Minna JD. ALK inhibition for non-small cell lung cancer: from discovery to therapy in record time. *Cancer Cell* 2010;18:548-51.
- [89] Andreotti AH, Schwartzberg PL, Joseph RE, Berg LJ. T-cell signaling regulated by the Tec family kinase, Itk. *Cold Spring Harb Perspect Biol* 2010;2:a002287.
- [90] Turner M, Schweighoffer E, Colucci F, et al. Tyrosine kinase SYK: essential functions for immunoreceptor signalling. *Immunol Today* 2000;21:148-54.
- [91] Rigby S, Huang Y, Streubel B, et al. The lymphoma-associated fusion tyrosine kinase ITK-SYK requires pleckstrin homology domain-mediated membrane localization for activation and cellular transformation. *J Biol Chem* 2009;284:26871-81.
- *[92] Pechloff K, Holch J, Ferch U, et al. The fusion kinase ITK-SYK mimics a T cell receptor signal and drives oncogenesis in conditional mouse models of peripheral T cell lymphoma. *J Exp Med* 2010;207:1031-44.
- [93] Dierks C, Adrian F, Fisch P, et al. The ITK-SYK fusion oncogene induces a T-cell lymphoproliferative disease in mice mimicking human disease. *Cancer Res* 2010;70:6193-204.
- *[94] Feldman AL, Sun DX, Law ME, et al. Overexpression of Syk tyrosine kinase in peripheral T-cell lymphomas. *Leukemia* 2008;22:1139-43.
- [95] Wilcox RA, Sun DX, Novak A, et al. Inhibition of Syk protein tyrosine kinase induces apoptosis and blocks proliferation in T-cell non-Hodgkin's lymphoma cell lines. *Leukemia* 2010;24:229-32.
- [96] Wada DA, Law ME, Hsi ED, et al. Specificity of IRF4 translocations for primary cutaneous anaplastic large cell lymphoma: a multicenter study of 204 skin biopsies. *Mod Pathol* 2011;24:596-605.
- [97] Pham-Ledard A, Prochazkova-Carlotti M, Laharanne E, et al. IRF4 gene rearrangements define a subgroup of CD30-positive cutaneous T-cell lymphoma: a study of 54 cases. *J Invest Dermatol* 2010;130:816-25.
- [98] Gualco G, Weiss LM, Bacchi CE. MUM1/IRF4: A Review. *Appl Immunohistochem Mol Morphol* 2010;18:301-10.
- *[99] Zhao WL. Targeted therapy in T-cell malignancies: dysregulation of the cellular signaling pathways. *Leukemia* 2010;24:13-21.
- [100] Jost PJ, Ruland J. Aberrant NF-kappaB signaling in lymphoma: mechanisms, consequences, and therapeutic implications. *Blood* 2007;109:2700-7.
- [101] Horie R. NF-kappaB in pathogenesis and treatment of adult T-cell leukemia/lymphoma. *Int Rev Immunol* 2007;26:269-81.
- [102] Izban KF, Ergin M, Qin JZ, et al. Constitutive expression of NF-kappa B is a characteristic feature of mycosis fungoides: implications for apoptosis resistance and pathogenesis. *Hum Pathol* 2000;31:1482-90.
- [103] Mocsai A, Ruland J, Tybulewicz VL. The SYK tyrosine kinase: a crucial player in diverse biological functions. *Nat Rev Immunol* 2010;10:387-402.

- [104] Pozzobon M, Marafioti T, Hansmann ML, et al. Intracellular signalling molecules as immunohistochemical markers of normal and neoplastic human leucocytes in routine biopsy samples. *Br J Haematol* 2004;124:519-33.
- [105] Geissinger E, Sadler P, Roth S, et al. Disturbed expression of the T-cell receptor/CD3 complex and associated signaling molecules in CD30+ T-cell lymphoproliferations. *Haematologica* 2010;95:1697-704.
- [106] Andrae J, Gallini R, Betsholtz C. Role of platelet-derived growth factors in physiology and medicine. *Genes Dev* 2008;22:1276-312.
- [107] Chen YP, Chang KC, Su WC, Chen TY. The expression and prognostic significance of platelet-derived growth factor receptor alpha in mature T- and natural killer-cell lymphomas. *Ann Hematol* 2008;87:985-90.