

Cannabis use, ischemic stroke, and multifocal intracranial vasoconstriction: a prospective study in 48 consecutive young patients.

Valérie Wolff, Valérie Lauer, Olivier Rouyer, François Sellal, Nicolas Meyer, Jean Sébastien Raul, Cécile Sabourdy, Fazel Boujan, Christine Jahn, Rémy Beaujeux, et al.

► **To cite this version:**

Valérie Wolff, Valérie Lauer, Olivier Rouyer, François Sellal, Nicolas Meyer, et al.. Cannabis use, ischemic stroke, and multifocal intracranial vasoconstriction: a prospective study in 48 consecutive young patients.: Ischemic Stroke and Cannabis. Stroke, American Heart Association, 2011, 42 (6), pp.1778-80. <10.1161/STROKEAHA.110.610915>. <inserm-00676840>

HAL Id: inserm-00676840

<http://www.hal.inserm.fr/inserm-00676840>

Submitted on 6 Mar 2012

HAL is a multi-disciplinary open access archive for the deposit and dissemination of scientific research documents, whether they are published or not. The documents may come from teaching and research institutions in France or abroad, or from public or private research centers.

L'archive ouverte pluridisciplinaire **HAL**, est destinée au dépôt et à la diffusion de documents scientifiques de niveau recherche, publiés ou non, émanant des établissements d'enseignement et de recherche français ou étrangers, des laboratoires publics ou privés.

Stroke

American Stroke
AssociationSM

JOURNAL OF THE AMERICAN HEART ASSOCIATION

A Division of American
Heart Association



Cannabis Use, Ischemic Stroke, and Multifocal Intracranial Vasoconstriction : A Prospective Study in 48 Consecutive Young Patients

Valérie Wolff, Valérie Lauer, Olivier Rouyer, François Sellal, Nicolas Meyer, Jean Sébastien Raul, Cécile Sabourdy, Fazel Boujan, Christine Jahn, Rémy Beaujeux and Christian Marescaux

Stroke 2011, 42:1778-1780: originally published online April 21, 2011

doi: 10.1161/STROKEAHA.110.610915

Stroke is published by the American Heart Association, 7272 Greenville Avenue, Dallas, TX 75214

Copyright © 2011 American Heart Association. All rights reserved. Print ISSN: 0039-2499. Online ISSN: 1524-4628

The online version of this article, along with updated information and services, is located on the World Wide Web at:

<http://stroke.ahajournals.org/content/42/6/1778>

Subscriptions: Information about subscribing to *Stroke* is online at
<http://stroke.ahajournals.org/subscriptions/>

Permissions: Permissions & Rights Desk, Lippincott Williams & Wilkins, a division of Wolters Kluwer Health, 351 West Camden Street, Baltimore, MD 21202-2436. Phone: 410-528-4050. Fax: 410-528-8550. E-mail:
journalpermissions@lww.com

Reprints: Information about reprints can be found online at
<http://www.lww.com/reprints>

Cannabis Use, Ischemic Stroke, and Multifocal Intracranial Vasoconstriction

A Prospective Study in 48 Consecutive Young Patients

Valérie Wolff, MD; Valérie Lauer, MD; Olivier Rouyer, MD, PhD; François Sellal, MD; Nicolas Meyer, MD, PhD; Jean Sébastien Raul, MD, PhD; Cécile Sabourdy, MD; Fazel Boujan, MD; Christine Jahn, MD; Rémy Beaujeux, MD; Christian Marescaux, MD

Background and Purpose—Our objective was to evaluate the relationship between cannabis use and ischemic stroke in a young adult population.

Methods—Forty-eight consecutive young patients admitted for acute ischemic stroke participated in the study. First-line screening was performed, including blood tests, cardiovascular investigations, and urine analysis for cannabinoids. If no etiology was found, 3D rotational angiography and cerebrospinal fluid analysis were performed. A control was planned through neurovascular imaging within 3 to 6 months.

Results—In this series, there was multifocal intracranial stenosis associated with cannabis use in 21% (n=10).

Conclusions—Multifocal angiopathy associated with cannabis consumption could be an important cause of ischemic stroke in young people. (*Stroke*. 2011;42:1778-1780.)

Key Words: stroke in young adults ■ vasospasm ■ cannabis

It has been recently reported that cannabis may contribute to acute ischemic cardiovascular or cerebrovascular events.¹ This possible effect was researched in a 2-year prospective study with a standardized assessment of all patients younger than 45 years admitted for ischemic stroke (IS).

Methods

From October 2005 to September 2007, 48 consecutive patients younger than 45 years of age who were admitted to our stroke unit for IS were included in this study. Patients were informed that they were included in a prospective study and agreed to participate. Standard T1, T2, FLAIR sequences, diffusion weighted-imaging magnetic resonance imaging scans were acquired for all patients. Vascular imaging comprised 3D-time of flight magnetic resonance angiography (n=43) or cerebral computed tomography angiography (n=5). Cardiac explorations included electrocardiogram (n=48), transthoracic echocardiography (n=48), and transoesophageal echocardiography (n=29). Exhaustive laboratory analyses were performed for all patients. If first-line investigations were inconclusive, 3D rotational angiography (n=30) and cerebrospinal fluid analysis (n=29) were performed. A questionnaire was used to determine cardiovascular risk factors, history of medication, and illicit drug or alcohol use. Urines were systematically screened for cannabinoids, cocaine, amphetamine, and methylenedioxymethamphetamine. Follow-up clinical visits (n=44) and control of vascular imaging (n=20) were planned within 3 to 6 months after discharge from hospital.

One study neurologist and 1 study radiologist separately reviewed all 3D-time of flight or computed tomography angiography images. A single operator performed all 3D rotational angiography, and 2 study radiologists, who were unaware of magnetic resonance angiography results, reviewed the 3D rotational angiography images. Involvement of single or several vessel segments were respectively classified as monoarterial stenosis or as multifocal intracranial stenosis (MIS).

Statistical Analysis

Data are summarized using descriptive statistics. Because of sparseness of data, computations of odds ratio and 95% CI, as well as multivariate logistic regression, were obtained using exact methods (StatXact and LogXact). The logistic regression was designed using the group of MIS as the dependent variable and the other variables as potential predictors. A probability value $\leq 5\%$ was considered statistically significant.

Results

Table displays the relationship between stroke etiology, classical risk factors, and cannabis use in the 48 patients. There were no patients undergoing serotonergic medical treatment, and there were no amphetamine, methylenedioxymethamphetamine, or cocaine users. Urine toxic analyses were positive for cannabis only in the 13 patients who admitted to smoking cannabis, and among them, all were

Received December 8, 2010; accepted December 30, 2010.

From the Unité Neuro-Vasculaire (V.W., V.L., C.S., C.M.), Hôpitaux Universitaires de Strasbourg (HUS), France; HUS, France; EA 3072, Faculté de Médecine de Strasbourg (O.R.), France; HUS, France; Service de Neurologie (F.S.), Hôpital de Colmar, Colmar, France; Département de Biostatistique et d'Informatique Médical (N.M.), HUS, France; Laboratoire de Toxicologie (J.S.R.), Institut de Médecine Légale, HUS, France; Service de Radiologie A (F.B., C.J., R.B.), HUS, France.

Correspondence to Valérie Wolff, Département de Neurologie, Hôpital Civil, 1, Place de l'Hôpital, 67100 Strasbourg, France. E-mail valerie.wolff@chru-strasbourg.fr

© 2011 American Heart Association, Inc.

Stroke is available at <http://stroke.ahajournals.org>

DOI: 10.1161/STROKEAHA.110.610915

Table. Stroke Etiology, Classical Risk Factors, and Cannabis Use in 48 Consecutive Young Patients

Characteristic	Total	Extracranial Dissection	Cardioembolism	Monoarterial Intracranial Stenosis	Multifocal Intracranial Stenosis	No Etiology
N	48	9	6	10	11	12
Age (Mean±SD)	35.5±8	36.2±6.9	42.3±4.2	34.8±7.7	29.7±8.8	37.3±6.3
Male	23	4	1	7	6	5
Hypertension	9	2	1	3	2	1
Diabetes	2	1	0	1	0	0
Hypercholesterolemia	26	5	4	5	6	6
Oral contraceptive use	12	1	1	2	2	6
Current smoker	25	5	0	5	10	5
Alcohol use	6	0	0	1	5	0
Cannabis use	13	1	0	1	10	1

N indicates number of patients.

tobacco smokers. Ten of 13 cannabis users displayed a specific pattern of MIS. Nine of these 10 patients had severe headache, and none had thunderclap headache. IS were located in the vertebrobasilar territory in 7 of 10 patients, and MIS predominated in posterior cerebral arteries (9 of 10 patients) and superior cerebellar arteries (7 of 10 patients). Lumbar puncture (8 of 10 patients) and blood analysis showed no significant abnormalities.

The association between MIS and cannabis was highly significant (odds ratio, 113 [9–5047]; $P < 0.001$). Indeed, 10 patients of 11 with MIS were cannabis users. An exact

logistic regression showed that no other factor could be introduced in the model, and thus no other factor appeared to be related independently to MIS.

The medical history of these patients strongly supported a temporal link between cannabis use and stroke associated with MIS (Figure). The 10 patients began to smoke cannabis on a regular basis several months to years before stroke onset. During the days before stroke, they all binged on cannabis, and 5 drank an unusually large amount of alcohol. Six patients stopped cannabis use after stroke with a favorable clinical outcome without relapse at 3 to 6 months. Control of

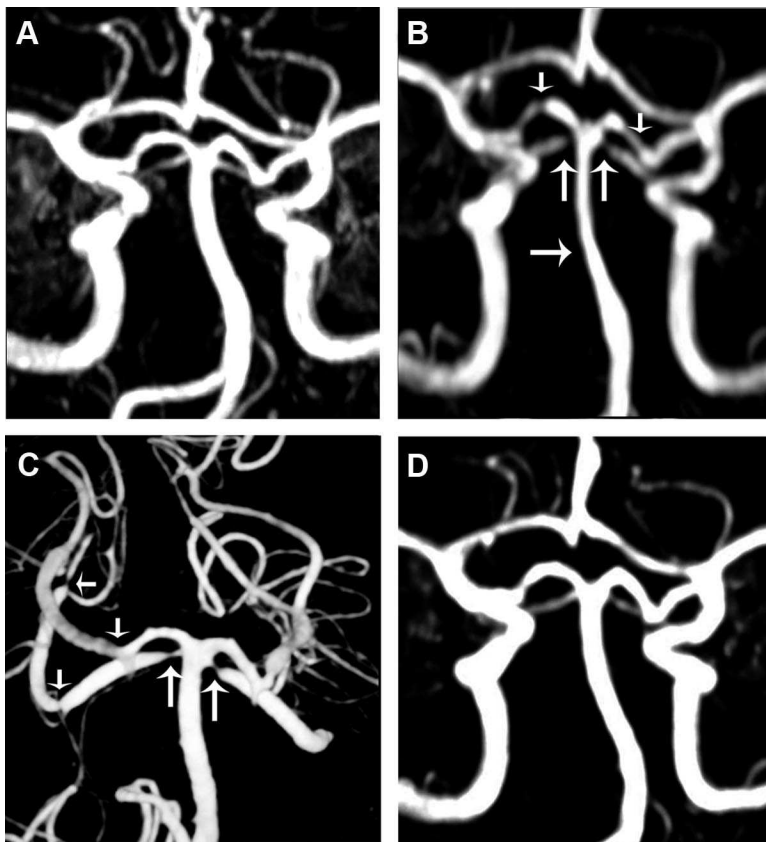


Figure. Typical example of the temporal link between cannabis consumption and MIS. Because of his familial history of aneurysm, a cerebral magnetic resonance angiography was performed when he was 19 and was normal (A). At age 20 years, he started smoking cannabis on a weekly basis. At age 21, he was hospitalized for a left cerebellar syndrome associated with unusual headache. Cerebral MRI showed a left cerebellar infarct. Cerebral magnetic resonance angiography disclosed MIS of basilar artery, both posterior cerebral arteries and superior cerebellar arteries (B); that were confirmed on 3D rotational angiography (C). After complete stop of cannabis use, the clinical outcome was favorable. Control cerebral magnetic resonance angiography (D) showed reverse of MIS at 3 months.

vascular imaging showed partial (n=3) or total (n=3) reversibility of MIS. Of the 3 remaining patients who still smoked cannabis, clinical outcome was favorable without relapse in 2, and was unfavorable in 1 patient, who underwent a new IS. At 3 to 6 months, there was no reversibility in these 3 patients.

Discussion

In our prospective cohort of 48 consecutive young patients with IS, 10 patients (21%) displayed a specific pattern of MIS that seemed to be associated with cannabis use. Using exact logistic regression, cannabis use appeared to be the most strongly associated factor with MIS. The 2 main radiological characteristics of their angiopathy were the involvement of multiple intracranial arteries and the reversibility of vasoconstriction after cannabis withdrawal.

Since 1987, fewer than 25 cases of IS associated with cannabis smoking have been published.^{2,3,4,5,6,7} As in our study, IS were more frequent in vertebrobasilar territory, suggesting susceptibility of posterior circulation.^{2,3,4} Concomitant alcohol consumption³ or unusually high consumption of cannabis were regarded as possible precipitating factors.^{3,4,5}

Our results raise the question of the relationship between the vasoconstriction pattern and the reversible cerebral vasoconstriction syndrome recently described.^{7,8} In regards to this

study, we have to conclude that cannabis is not as harmless as was thought, and cerebrovascular risk when consumed is probably underestimated.

Acknowledgements

Thanks to Rodrigue Galani, PhD, for writing assistance.

Disclosures

None.

References

1. Aryana A, Williams MA. Marijuana as a trigger of cardiovascular events: speculation or scientific certainty? *Int J Cardiol.* 2007;118:141–144.
2. Geller T, Loftis L, Brink D. Cerebellar infarction in adolescent males associated with acute marijuana use. *Pediatrics.* 2004;113:e365–e370.
3. Mateo I, Infante J, Gomez-Beldarrain M, Garcia-Monco JC. Cannabis and cerebrovascular disease. *Neurologia.* 2006;21:204–208.
4. Bal S, Khurana D, Lal V, Prabhakar S. Posterior circulation stroke in a cannabis abuser. *Neurol India.* 2009;57:91–92.
5. Duchene C, Olindo S, Chausson N, Jeannin S, Cohen-Tenoutji, Smadja D. Cannabis-induced cerebral and myocardial infarction in a young woman. *Rev neurol.* 2010;166:438–442.
6. Moussouttas M. Cannabis use and cerebrovascular disease. *Neurologist.* 2004;10:47–53.
7. Calabrese L, Dodick D, Schwedt T, Singhal A. Narrative review: reversible cerebral vasoconstriction syndromes. *Ann Intern Med.* 2007;146:34–44.
8. Ducros A, Boukobza M, Porcher R, Sarov M, Valade D, Bousser MG. The clinical and radiological spectrum of reversible cerebral vasoconstriction syndrome. A prospective series of 67 patients. *Brain.* 2007;130:3091–3001.