

## Free-breathing myocardial T2 measurements at 1.5T

Maelene Lohezic, Anne Menini, Jean-Marie Escanyé, Pierre-Yves Marie,  
Damien Mandry, Pierre-André Vuissoz, Jacques Felblinger

► **To cite this version:**

Maelene Lohezic, Anne Menini, Jean-Marie Escanyé, Pierre-Yves Marie, Damien Mandry, et al.. Free-breathing myocardial T2 measurements at 1.5T. 2011 SCMR/Euro CMR Joint Scientific Sessions, Feb 2011, Nice, France. Biomed Central, 13 (Suppl 1), pp.P11, 2011, Journal of Cardiovascular Magnetic Resonance. <inserm-00663677>

**HAL Id: inserm-00663677**

**<http://www.hal.inserm.fr/inserm-00663677>**

Submitted on 27 Jan 2012

**HAL** is a multi-disciplinary open access archive for the deposit and dissemination of scientific research documents, whether they are published or not. The documents may come from teaching and research institutions in France or abroad, or from public or private research centers.

L'archive ouverte pluridisciplinaire **HAL**, est destinée au dépôt et à la diffusion de documents scientifiques de niveau recherche, publiés ou non, émanant des établissements d'enseignement et de recherche français ou étrangers, des laboratoires publics ou privés.

**POSTER PRESENTATION**

**Open Access**

# Free-breathing myocardial T2 measurements at 1.5T

Maelene Lohezic<sup>1\*</sup>, Anne Menini<sup>2</sup>, Jean-Marie Escanyé<sup>3</sup>, Pierre-Yves Marie<sup>4</sup>, Damien Mandry<sup>4</sup>, Pierre-André Vuissoz<sup>3</sup>, Jacques Felblinger<sup>2</sup>

From 2011 SCMR/Euro CMR Joint Scientific Sessions  
Nice, France. 3-6 February 2011

## Introduction

Myocardial T2 mapping is a valuable tool for tissue characterization and oedema visualization. For instance, it is used to detect early rejection of heart transplant [1]. T2 values are usually estimated by performing several black blood Fast Spin Echo (FSE) sequences with different Echo Times (TE), what requires multiple breath holds. Successive apneas could lead to misregistration between images and to patient discomfort. A method allowing free breathing myocardial T2 measurements has been recently proposed and evaluated at 3T [2]. Results at 1.5T are presented here.

## Purpose

This study aims at demonstrating the feasibility of free-breathing myocardial T2 mapping at 1.5T.

## Methods

### MRI experiments

Five healthy volunteers underwent cardiac examination at 1.5T (SIGNA HDxt, GE Healthcare, Milwaukee, WI). Two sets of ten images with different TE were acquired with a conventional cardiac-gated black blood FSE sequence at mid-cavity short axis view, one during breath hold and the other one during free breathing. The same parameters were used, except for echo train length (ETL) (Table 1). ETL was set at 24 to keep the breath hold duration short, whereas 16 echoes were used for free-breathing acquisitions. Raw data from the free breathing acquisitions were recorded. Signals from a respiratory belt were carried by a custom Maglife patient monitoring system (Schiller Medical, France) and recorded with a dedicated home-made hardware [3].

## Post-processing

First, the ten breath-held images were registered manually. Then, the T2 map was obtained using a mono-exponential model to fit the T2 signal versus the echo time decay curve, on a pixel-wise basis.

## Free breathing reconstruction

Using physiological signals extracted from the respiratory belt, the method presented in [2] was used to obtain an artefact-free proton density weighted image  $r_0$  and a T2 map from the free breathing raw data set. For the sake of comparison, six segments were drawn on the left ventricle myocardium. The mean value of each ROI was then used to get 6 myocardial T2 values.

## Results

Like at 3T, there was no significant differences between the two sets of myocardial T2 values (paired Student T-test,  $p=0.17$ ). The free breathing T2 maps were in good agreement with the breath-held ones and respiratory artefacts were widely reduced in  $r_0$  (Fig. 1).

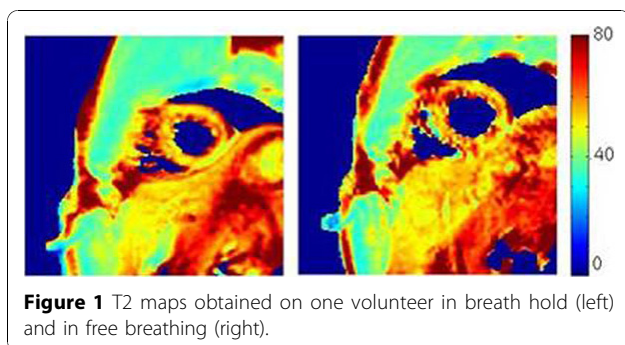
## Conclusions

The proposed free breathing method allows performing accurate T2 mapping at 1.5T with no additional acquisition time.

**Table 1 Acquisition parameters**

TE	10 to 75 ms
TR	2RR
TI	500 ms
Matrix size	128X128
FOV	36 cm
BW	62.5kHz
Slice thickness	10mm
ETL	16 or 24

<sup>1</sup>GE Healthcare / IADI Lab, Nancy, France  
Full list of author information is available at the end of the article



#### Author details

<sup>1</sup>GE Healthcare / IADI Lab, Nancy, France. <sup>2</sup>INSERM U947, Nancy, France.  
<sup>3</sup>Nancy-Université, Nancy, France. <sup>4</sup>CHU Nancy, Nancy, France.

Published: 2 February 2011

#### References

1. Marie, *et al. JACC* 2001, **37**:825-831.
2. Lohezic, *et al. Proc. ISMRM* 2010, 2958.
3. Odille, *et al. IEEE TBME* 2007, **54**:630-640.

doi:10.1186/1532-429X-13-S1-P11

**Cite this article as:** Lohezic *et al.*: Free-breathing myocardial T2 measurements at 1.5T. *Journal of Cardiovascular Magnetic Resonance* 2011 **13**(Suppl 1):P11.

**Submit your next manuscript to BioMed Central  
and take full advantage of:**

- Convenient online submission
- Thorough peer review
- No space constraints or color figure charges
- Immediate publication on acceptance
- Inclusion in PubMed, CAS, Scopus and Google Scholar
- Research which is freely available for redistribution

Submit your manuscript at  
[www.biomedcentral.com/submit](http://www.biomedcentral.com/submit)

 **BioMed Central**